



PATIENT

Dash Canaday

SPECIES

Canine

BREED

Smooth Collie

SEX

Neutered Male

AGE

3Y, 7M

WEIGHT

74lbs

INTERPRETED BY

Sebastian Jawinski,
German Board
Certified Vet Specialist
in Diagnostic Imaging

IMAGING PERFORMED BY

Lisa C./Kennedy S.

HOSPITAL NAME

Animal Clinic
Northview

REFERRING VET

Grace Schmeiser, DVM

INVOICE

73681

DATE

2-10-26

PRESENTING CLINICAL SIGNS

- Presented for 2 month history of intermittent left forelimb lameness. Ranges from barely detectable to non-weight bearing. Mild crepitus and resistance to flexion noted in L elbow on exam, otherwise physical exam was unremarkable.

COMPUTED TOMOGRAPHY OF THE CERVICAL SPINE, ELBOW, & SHOULDER JOINTS

Plain study provided for review.

COMPUTED TOMOGRAPHIC FINDINGS

The right elbow joint appears normal with well-defined bone surfaces and without signs of a fracture, sub-/luxation or an osteolytic/sclerotic process. The periarticular soft tissues are in expected normal limits. Especially the medial coronoid process is inconspicuous.

The left side presents an incongruity of the radio-ulnar joint space with mild alternations of bone density at the level of the medial coronoid process. The subchondral surface of the trochlea is inconspicuous. The periarticular soft tissues do not show particular findings in the plain study.

Both shoulder joints present a normal caudal humeral head. The bicipital groove is inconspicuous with a normal origin and course of the biceps tendon. The insertion of the infra- and supraspinatus muscles are unremarkable. Periarticular soft tissues and the brachial plexus are laterally symmetrical. The displayed spine shows no evidence of a compressive lesion.

COMPUTED TOMOGRAPHIC DIAGNOSIS

- Suspected lesion of the left medial coronoid process with alternations of bone density

INTERPRETATION OF THE FINDINGS & FURTHER RECOMMENDATIONS

The alternations of bone density and the mild incongruity of the radio-ulnar joint space are consistent with a mild degree of canine elbow dysplasia. These findings would match with the reported patient's history. However, currently there are no significant degenerative changes that would indicate clinical relevance. A fissure line or fragmentation is not noted.

Inflammatory changes within the soft tissues (for example synovitis and flexor enthesopathy) and a lateralized compressive of the spinal cord/nerve roots cannot be ruled out completely in the plain study.



PATIENT

Dash Canaday

SPECIES

Canine

BREED

Smooth Collie

SEX

Neutered Male

AGE

3Y, 7M

WEIGHT

74lbs

INTERPRETED BY

Sebastian Jawinski,
German Board
Certified Vet Specialist
in Diagnostic Imaging

IMAGING PERFORMED BY

Lisa C./Kennedy S.

HOSPITAL NAME

Animal Clinic
Northview

REFERRING VET

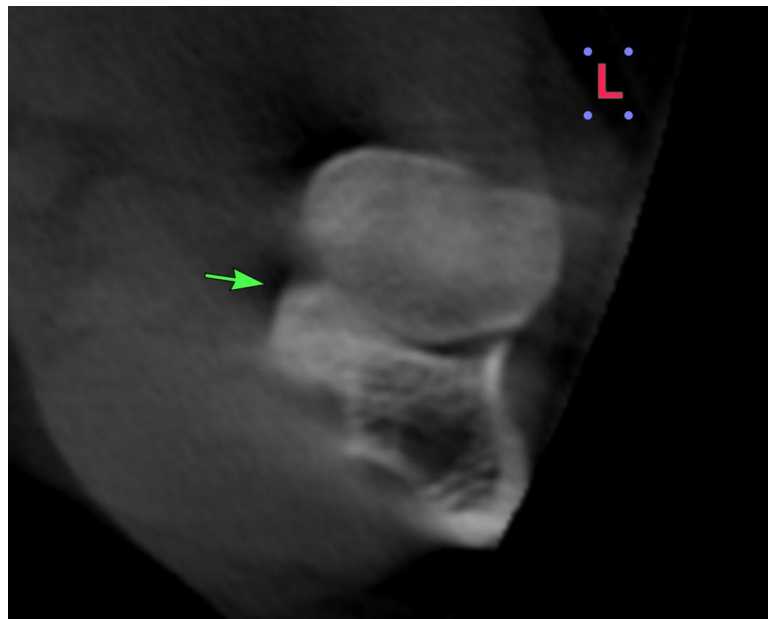
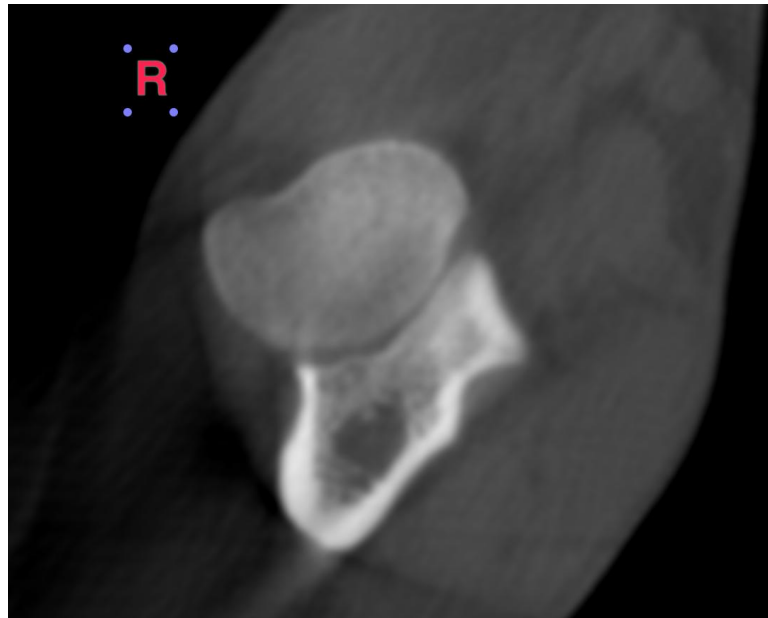Grace Schmeiser, DVM

INVOICE

73681

DATE

2-10-26



The information and recommendations provided are based on the images presented by the referring veterinarian/sonographer. No evaluation can be communicated regarding pathology that was not visible in the image/video clips provided.

Thank you for this referral. If the clinical or image interpretation does not parallel your findings or if I can be of any further assistance, please contact me.

Sebastian Jawinski, German Board Certified Vet Specialist in Diagnostic Imaging
info@sonopath.com