

**PATIENT**

Luna Rexhaj

PRESENTING CLINICAL SIGNS

Abd U/S: observed a large (minimum of 10 cm x 12 cm) hypoechoic structure in the area of the left kidney- identified normal liver, stomach, spleen, bladder, and right kidney; hypoechoic structure in the area of the left kidney appears to be filled with fluid with hyperechoic specs of floating material (observed at caudal aspect of structure); observed potentially lobulated area of structure towards midline.

SPECIES

Canine

COMPUTED TOMOGRAPHY OF THE THORAX & ABDOMEN

Pre/post contrast studies provided for review.

BREED

Italian Greyhound

COMPUTED TOMOGRAPHIC FINDINGS

Thorax:

SEX

Spayed Female

The lungs are regularly ventilated with close contact to the inner thoracic wall on all sides. There is no evidence of pleural thickening, fluid accumulation or free pleural gas. Pulmonary density is within normal limits, there is no evidence of focal or nodular pulmonary lesions.

AGE

1.5

The mediastinum is regular in width and density. Mediastinal (sternal, tracheal-, bronchial) lymph nodes are considered to be normal. The thoracic trachea and esophagus present as expected.

INTERPRETED BY

Sebastian Jawinski,
German Board
Certified Vet
Specialist in
Diagnostic Imaging

Inconspicuous representation of the main pulmonary artery, of the pulmonary artery branching, of the large intrathoracic and the hepatic vessels shown. The heart is inconspicuous as far as can be assessed with CT.

The diaphragm appears normal.

HOSPITAL NAME

Aloha Pet & Bird
Hospital

Abdomen:

The left side presents severe hydronephrosis and a distension of the left ureter of the cranial ureteral section. The left ureter cannot be further traced. The right kidney and right ureter are inconspicuous. Urinary bladder, trigone and urethra show no particular findings.

REFERRING VET

McLaughlin

Liver, spleen, pancreas, and gastrointestinal tract appear normal.

Abdominal lymph nodes and abdominal vessels have no particular findings. Signs of peritoneal/retroperitoneal effusion or free gas are not recognized.

INVOICE

49995

COMPUTED TOMOGRAPHIC DIAGNOSIS

- Severe hydronephrosis left kidney and partial left hydroureter
- Normal findings of the thorax and the abdomen apart from that

DATE

2-1-22



PATIENT

Luna Rexhaj

SPECIES

Canine

BREED

Italian Greyhound

SEX

Spayed Female

AGE

1.5

INTERPRETED BY

Sebastian Jawinski,
German Board
Certified Vet
Specialist in
Diagnostic Imaging

HOSPITAL NAME

Aloha Pet & Bird
Hospital

REFERRING VET

McLaughlin

INVOICE

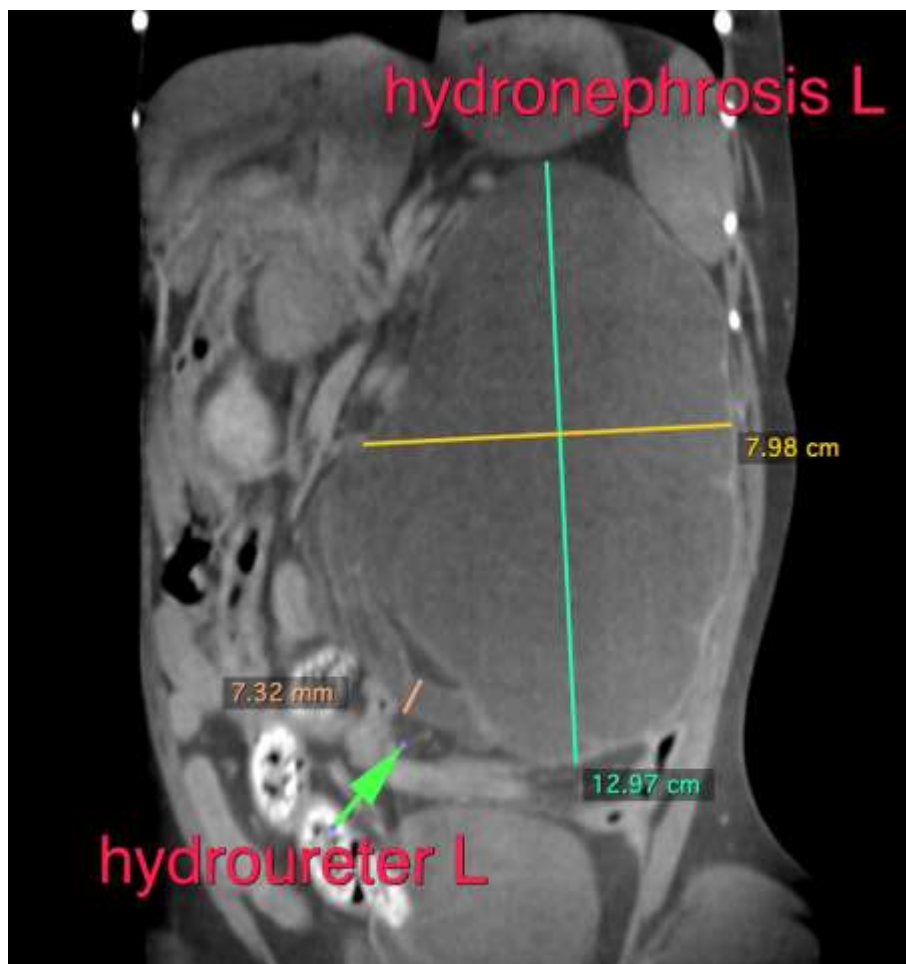
49995

DATE

2-1-22

INTERPRETATION OF THE FINDINGS & FURTHER RECOMMENDATIONS

The CT findings show severe hydronephrosis of the left kidney. The cranial aspect of the left ureter is included and presents significant distension. Differentials include but are not limited to obstructive lesions in the course of the ureter and the area of the trigone. Congenital malformation is common in young patients and possible as well. Strictures due to scarring after OHE should be considered (local pain?). Neoplasia is not detected. The left kidney still may be functional. Grade of hydronephrosis does not correlate with renal function. Explorative laparotomy to rule out obstruction and/or for nephrectomy could be performed next.





PATIENT

Luna Rexhaj

SPECIES

Canine

BREED

Italian Greyhound

SEX

Spayed Female

AGE

1.5

INTERPRETED BY

Sebastian Jawinski,
German Board
Certified Vet
Specialist in
Diagnostic Imaging

HOSPITAL NAME

Aloha Pet & Bird
Hospital

REFERRING VET

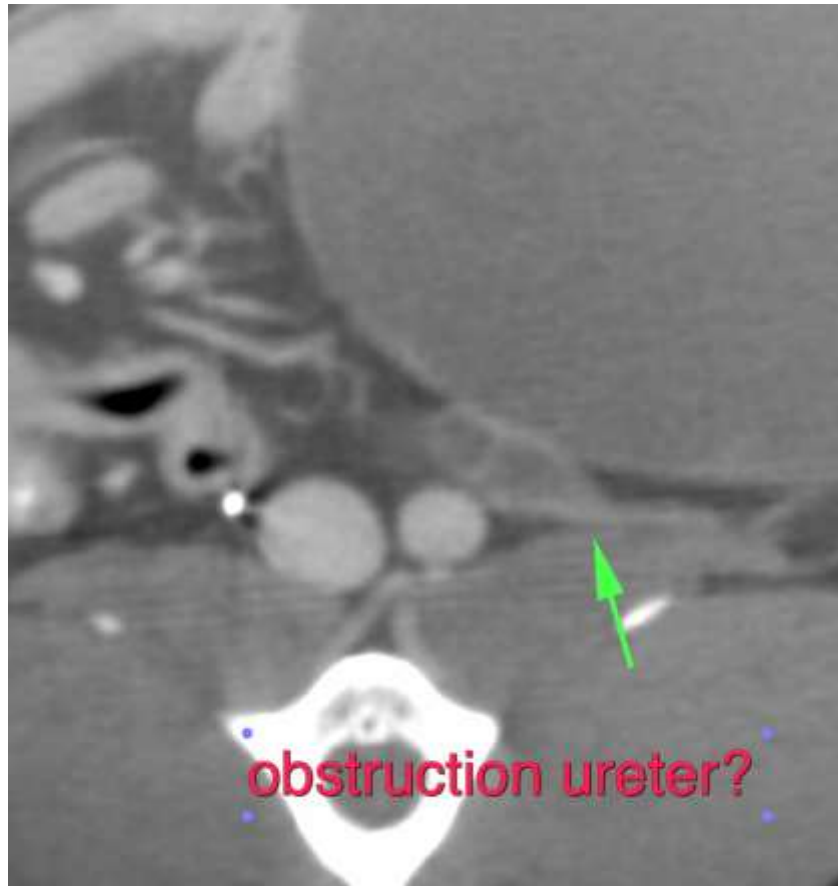
McLaughlin

INVOICE

49995

DATE

2-1-22



The information and recommendations provided are based on the images presented by the referring veterinarian/sonographer. No evaluation can be communicated regarding pathology that was not visible in the image/video clips provided.

Thank you for this referral. If the clinical or image interpretation does not parallel your findings or if I can be of any further assistance, please contact me.

Sebastian Jawinski, German Board Certified Vet Specialist in Diagnostic Imaging
Sebastian.Jawinski@sonopath.com