



PATIENT

Mozart Morton

PRESENTING CLINICAL SIGNS

Coughing 24 hour duration, low grade fever, lethargic, anorexia, vomited a couple of times. Abnormal PE/Chem/CBC/UA Results: Chemistries and T4 are unremarkable, CBC and UA are pending.

SPECIES

Canine

RADIOGRAPHIC FINDINGS

Displayed bony structures of spine and thorax are within normal limits without signs of a fracture, sub-/luxation and/or a lytic/sclerotic process.

BREED

Shih Tzu

Thorax:

SEX

The cardiac silhouette is normal with no evidence of chamber enlargement. Pulmonary vessels are normal in size and taper appropriately in the periphery.

Male Neutered

The ventral right lung section cranial to the heart shows an ill-defined area of increased density best seen in the lateral projections.

AGE

13.5 Years

The trachea is unremarkable in diameter and course. The luminal outline of the trachea is smooth. The carina and the bronchial tree appear normal.

INTERPRETED BY

Sebastian Jawinski,
German Board
Certified Vet
Specialist in
Diagnostic Imaging

Mediastinum presents expected soft tissue density, there is no evidence of tracheobronchial, cranial mediastinal or sternal lymphadenopathy. No mediastinal shift is seen.

The esophagus is not visible and considered to be normal.

Diaphragm is unremarkable, no signs of pleural effusion.

HOSPITAL NAME

Friendship Springs
Veterinary Care

Abdomen:

Liver and spleen present as expected and are well defined.

REFERRING VET

Trae Cutchin

The stomach is moderately gas distended and indicates a markedly thickened gastric wall with calcifications aligning with the inner outline. The pyloric region appears prominent.

The small intestine presents fluid-filled loops.

INVOICE

49275

The colon contains some radiopaque ingesta.

The left kidney is well visualized considered as normal. No signs of abdominal or retroperitoneal effusion.

DATE

12-28-21

Urinary bladder is moderately filled without evidence of radiopaque cystic calculi.



PATIENT

Mozart Morton

RADIOGRAPHIC DIAGNOSIS

- Significant thickening of the gastric wall with indicated calcifications
- Prominent pyloric region
- Ill-defined area of increased pulmonary density cranial right lung

SPECIES

Canine

INTERPRETATION OF THE FINDINGS & FURTHER RECOMMENDATIONS

The suspected thickening of the gastric wall is highly suspicious for severe gastritis. Lymphoplasmocytic and-histiocytic inflammation is possible as well as gastric ulceration. Neoplasia cannot be fully excluded. The calcifications and the distension would match with the latter (R/O foreign material/adenocarcinoma/lymphoma). A complementary abdominal ultrasound is recommended. Aspiration of ingesta/foreign material with a consecutive pneumonia of the right cranial lung lobe may be a concomitant finding. Radiographic results do match with the reported patient's history.

BREED

Shih Tzu

SEX

Male Neutered

AGE

13.5 Years

INTERPRETED BY

Sebastian Jawinski,
German Board
Certified Vet
Specialist in
Diagnostic Imaging

HOSPITAL NAME

Friendship Springs
Veterinary Care

REFERRING VET

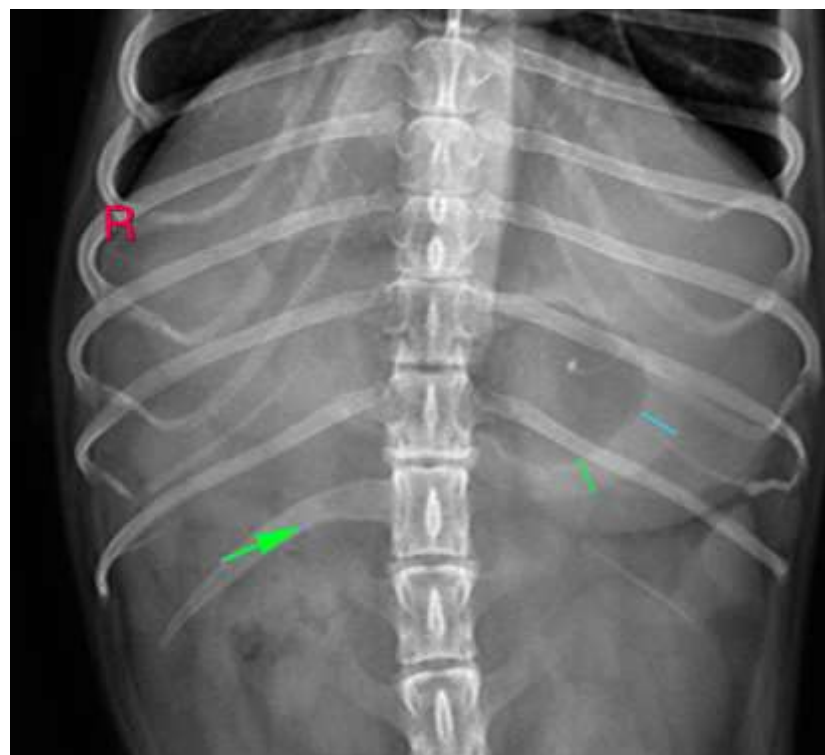
Trae Cutchin

INVOICE

49275

DATE

12-28-21





PATIENT

Mozart Morton

SPECIES

Canine

BREED

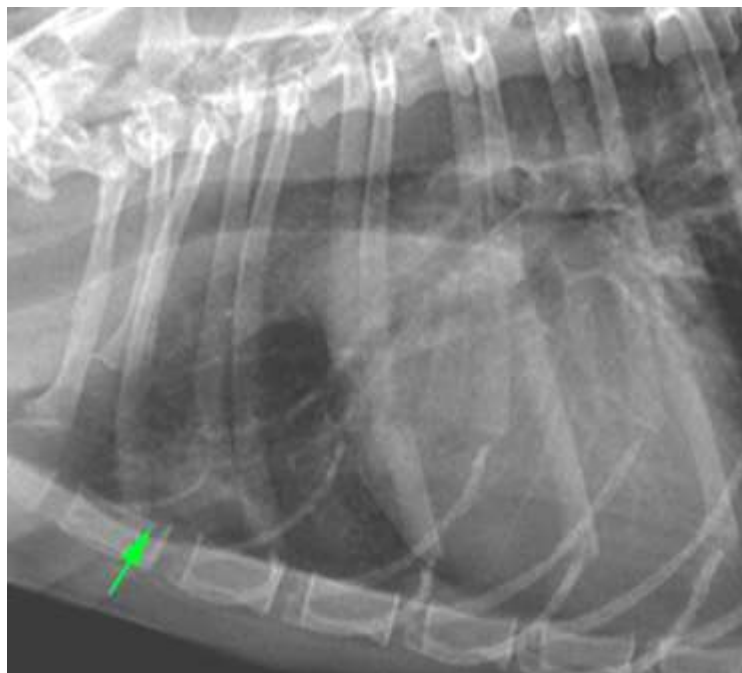
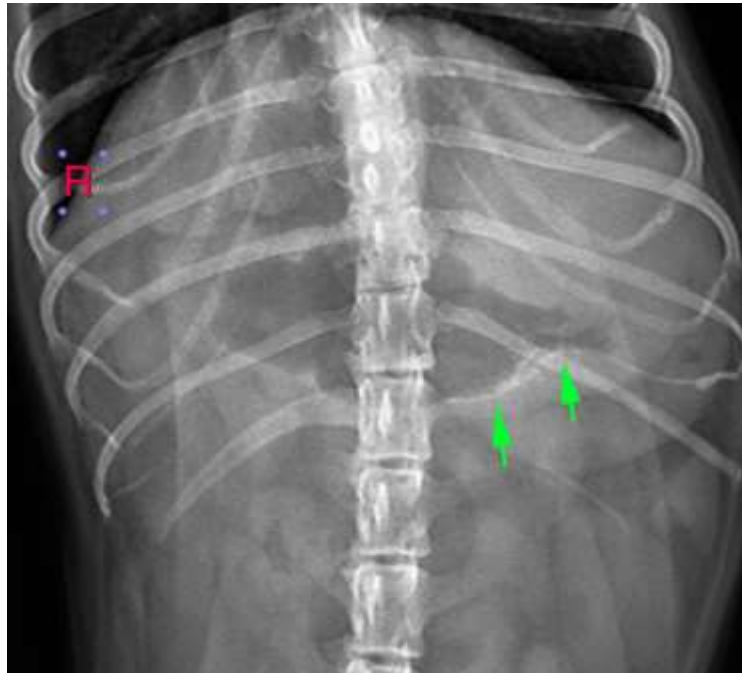
Shih Tzu

SEX

Male Neutered

AGE

13.5 Years



INTERPRETED BY

Sebastian Jawinski,
German Board
Certified Vet
Specialist in
Diagnostic Imaging

HOSPITAL NAME

Friendship Springs
Veterinary Care

REFERRING VET

Trae Cutchin

INVOICE

49275

DATE

12-28-21



PATIENT

Mozart Morton

SPECIES

Canine

BREED

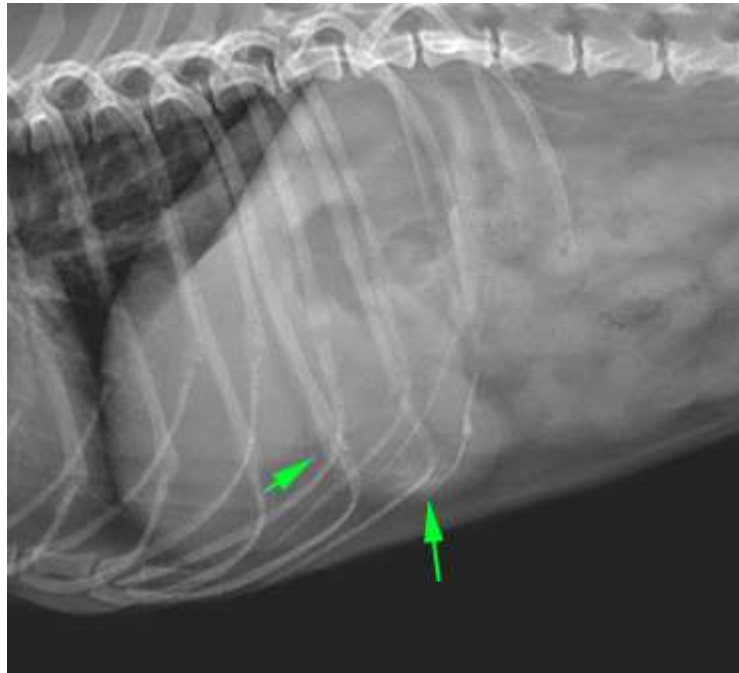
Shih Tzu

SEX

Male Neutered

AGE

13.5 Years



INTERPRETED BY

Sebastian Jawinski,
German Board
Certified Vet
Specialist in
Diagnostic Imaging

The information and recommendations provided are based on the images presented by the referring veterinarian. No evaluation can be communicated regarding pathology that was not visible in the image/video clips provided.

Thank you for this referral. If the clinical or image interpretation does not parallel your findings or if I can be of any further assistance, please contact me.

HOSPITAL NAME

Friendship Springs
Veterinary Care

Sebastian Jawinski, German Board Certified Vet Specialist in Diagnostic Imaging
Sebastian.Jawinski@sonopath.com

REFERRING VET

Trae Cutchin

INVOICE

49275

DATE

12-28-21