

**PATIENT**

Baby Durham

PRESENTING CLINICAL SIGNS

Patient came in as an emergency with a lump under chin. Possible salivary gland

SPECIES

Canine

COMPUTED TOMOGRAPHIC FINDINGS

Neck/Cervical Spine:

Presented bony structures of the cervical spine are unremarkable with an inconspicuous harmonic course.

BREEDAustralian Shepard
Miniature

Vertebral bodies are of regular density without signs of a lytic or sclerotic process. There is no evidence of a fracture and/or sub-/luxation/compressive lesion.

SEX

SF

The right side of the neck presents a large, subcutaneous, contrast filled lesion at the level right to the larynx and a division in a smaller part ventral and left to the larynx. In the area of the mandibular salivary gland a conglomerate of multiple small calcifications/calculi measuring approximately 1.60 cm in length is recognized.

AGE

12 Years

COMPUTED TOMOGRAPHIC DIAGNOSIS

- Large, fluid-filled lesion right neck with multiple calculi

INTERPRETED BYSebastian Jawinski,
German Board
Certified Vet
Specialist in
Diagnostic Imaging**INTERPRETATION OF THE FINDINGS & FURTHER RECOMMENDATIONS**

CT findings are highly suspicious for a salivary mucocele with multiple sialoliths likely of the mandibular salivary gland. The multiple calculi indicate a chronic issue like sialoadenosis which may be activated by obstruction and/or secondary infection/florid inflammation. Salivary gland location of the calcification is assumed but also could be in the area of the right medial retropharyngeal lymph node. A complementary ultrasound and aspirate could be performed next (determine origin and R/O abscess). Radiopaque foreign material is not detected but cannot be fully excluded. Neoplasia is unlikely.

HOSPITAL NAMEPetroglyph Animal
Hospital**REFERRING VET**

Dr. Raymond Hudgell

INVOICE

49282

DATE

12-28-21



PATIENT

Baby Durham

SPECIES

Canine

BREED

Australian Shepard
Miniature

SEX

SF

AGE

12 Years

INTERPRETED BY

Sebastian Jawinski,
German Board
Certified Vet
Specialist in
Diagnostic Imaging

HOSPITAL NAME

Petroglyph Animal
Hospital

REFERRING VET

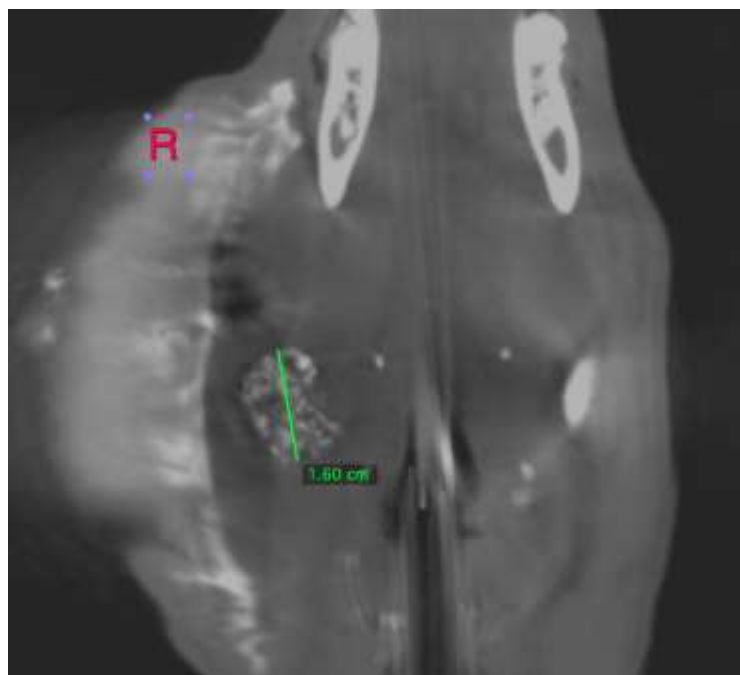
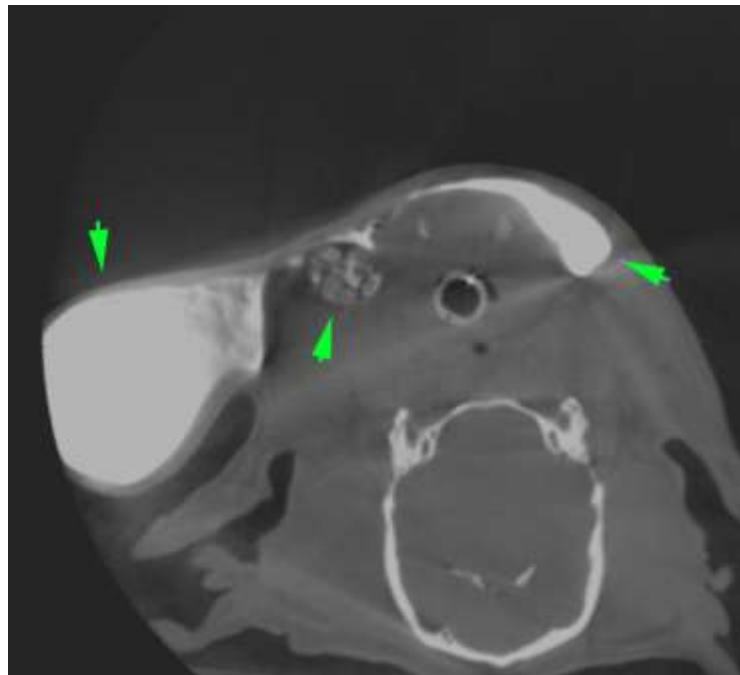
Dr. Raymond Hudgell

INVOICE

49282

DATE

12-28-21





PATIENT

Baby Durham

The information and recommendations provided are based on the images presented by the referring veterinarian. No evaluation can be communicated regarding pathology that was not visible in the image/video clips provided.

SPECIES

Canine

Thank you for this referral. If the clinical or image interpretation does not parallel your findings or if I can be of any further assistance, please contact me.

BREED

Australian Shepard
Miniature

Sebastian Jawinski, German Board Certified Vet Specialist in Diagnostic Imaging
Sebastian.Jawinski@sonopath.com

SEX

SF

AGE

12 Years

INTERPRETED BY

Sebastian Jawinski,
German Board
Certified Vet
Specialist in
Diagnostic Imaging

HOSPITAL NAME

Petroglyph Animal
Hospital

REFERRING VET

Dr. Raymond Hudgell

INVOICE

49282

DATE

12-28-21