

**PATIENT**

Buzz Rafferty

PRESENTING CLINICAL SIGNS

Nov 2021- satsuma sized swelling on elbow, no lameness, FNA suspected synovial fluid, tx abs and anti-infams Dec 2021 swelling still present no lameness adv CT and joint tap
Abnormal PE/Chem/CBC/UA Results: No abnormal bloods etc

SPECIES

Canine

COMPUTED TOMOGRAPHIC FINDINGS**Right Elbow**

There is a rounded soft-tissue dense mass noted proximal and caudal to the anconeal process measuring at least 4.75 x 4.70 cm. The mass is smoothly marginated with an inconspicuous periphery. The adjacent bony surface of the anconeal process is unremarkable. The radioulnar joint space is congruent. There are no osteophytic changes noted. The subchondral bone especially of the trochlea is inconspicuous as well as the tip of the medial coronoid process.

BREED

Springer Spaniel

SEX

Male

COMPUTED TOMOGRAPHIC DIAGNOSIS

- Soft tissue mass proximal and caudal to the right anconeal process
- Normal findings of the elbow joint

AGE

10 Months

INTERPRETED BY

Sebastian Jawinski,
German Board
Certified Vet
Specialist in
Diagnostic Imaging

INTERPRETATION OF THE FINDINGS & FURTHER RECOMMENDATIONS

CT findings likely represent a bursa inflammation/hygroma. Signs of an aggressive or even malignant process are not detected. The elbow joint and displayed bones are unremarkable. Abscess formation/infection are possible as well but currently not suspected.

HOSPITAL NAME

Myerscough
Veterinary Group

REFERRING VET

Sian Smith

INVOICE

49188

DATE

12-22-21



PATIENT

Buzz Rafferty

SPECIES

Canine

BREED

Springer Spaniel

SEX

Male

AGE

10 Months

INTERPRETED BY

Sebastian Jawinski,
German Board
Certified Vet
Specialist in
Diagnostic Imaging

HOSPITAL NAME

Myerscough
Veterinary Group

REFERRING VET

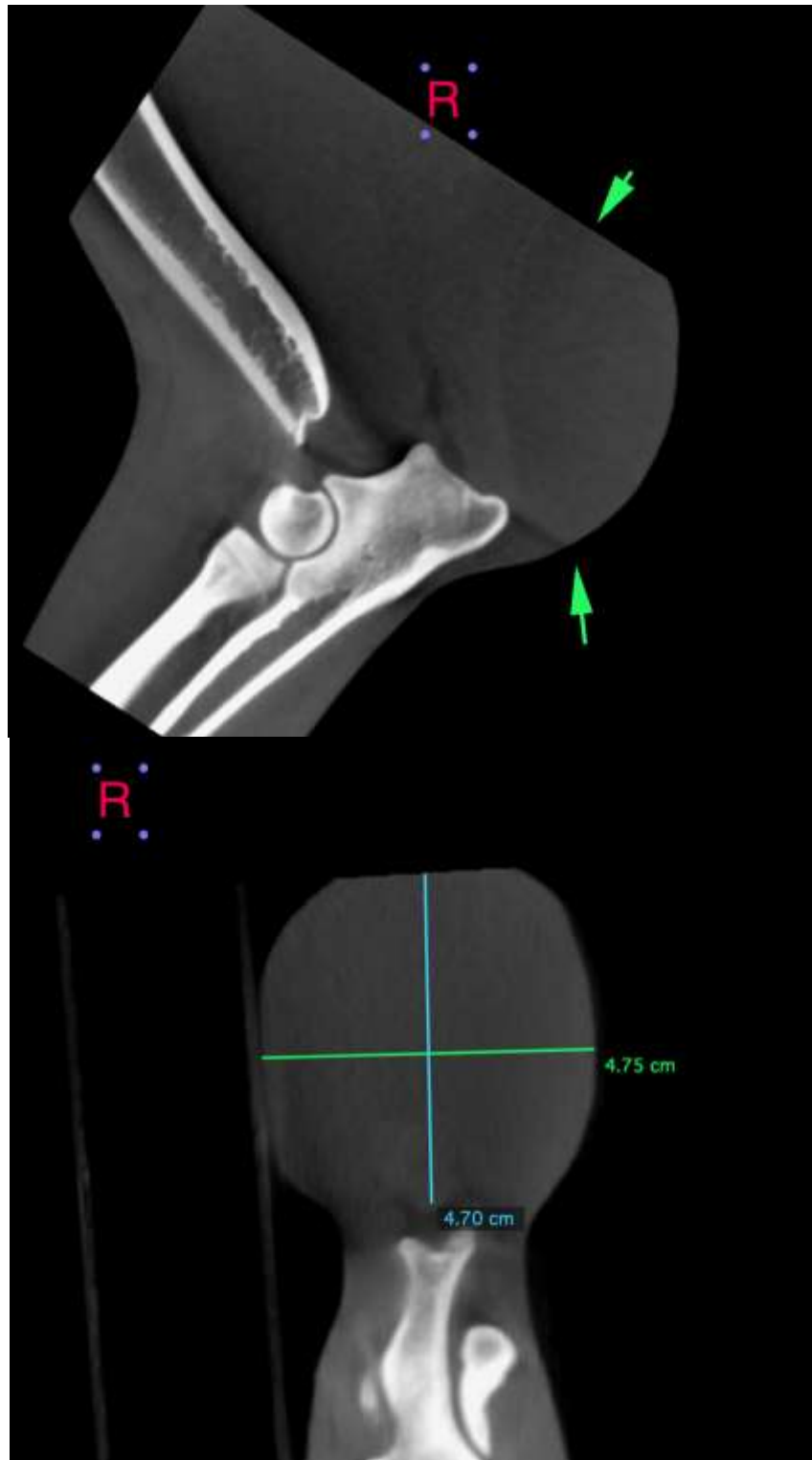
Sian Smith

INVOICE

49188

DATE

12-22-21





PATIENT

Buzz Rafferty

The information and recommendations provided are based on the images presented by the referring veterinarian. No evaluation can be communicated regarding pathology that was not visible in the image/video clips provided.

SPECIES

Canine

Thank you for this referral. If the clinical or image interpretation does not parallel your findings or if I can be of any further assistance, please contact me.

Sebastian Jawinski, German Board Certified Vet Specialist in Diagnostic Imaging
Sebastian.Jawinski@sonopath.com

BREED

Springer Spaniel

SEX

Male

AGE

10 Months

INTERPRETED BY

Sebastian Jawinski,
German Board
Certified Vet
Specialist in
Diagnostic Imaging

HOSPITAL NAME

Myerscough
Veterinary Group

REFERRING VET

Sian Smith

INVOICE

49188

DATE

12-22-21