



PATIENT

Blaze Warne

SPECIES

Feline

BREED

DSH

SEX

MN

AGE

7

WEIGHT

3.7

INTERPRETED BY

Sebastian Jawinski,
German Board
Certified Vet Specialist
in Diagnostic Imaging

IMAGING PERFORMED BY

Patricia Sanchez
Sanchez

HOSPITAL NAME

Animal Trust - Bolton

REFERRING VET

Patricia Sanchez
Sanchez

INVOICE

72812

DATE

12-2-25

PRESENTING CLINICAL SIGNS

Respiratory symptoms. There are no signs of heart murmur. Tried with steroids, panacur, furosemide and antibiotics. No responding to any medical treatment. Liver values mild-moderate elevated on bloods.

COMPUTED TOMOGRAPHY OF THE THORAX

Pre/post contrast studies are provided for review.

COMPUTED TOMOGRAPHIC FINDINGS

There is severe and diffuse increase of the interstitial density noted in all lung parts and on both sides, with concomitant dilatation of the bronchi and mild peri-bronchial infiltrates. The course and diameter of the trachea and the bifurcation are unremarkable. Free pleural fluid is not noted. Evidence of nodular changes is not recognized. The mediastinum, especially the mediastinal lymph nodes, appear inconspicuous. The heart shows a normal size as far as can be assessed with CT.

The thoracic borders are intact, including the diaphragm.

The cranial parts of the abdomen do not show particular findings.

COMPUTED TOMOGRAPHIC DIAGNOSIS

- Severe and diffuse interstitial lung pattern with peri-bronchial infiltrates and indicated bronchiectasis

INTERPRETATION OF THE FINDINGS & FURTHER RECOMMENDATIONS

The severe changes of the pulmonary interstitium are suspicious for infiltrative disease. These do explain the clinical symptoms and could represent chronic inflammatory or even neoplastic infiltrations. CT is unspecific there. The most common differentials include eosinophilic pneumonia, pulmonary lymphoma and fungal disease. Other neoplastic infiltrations are possible (for example mast cell tumor, bronchial carcinoma: s. right caudal lung lobe). For further assessment, endoscopy and BAL are recommended. The resistance to cortisone therapy makes lymphoma and inflammatory infiltrations less likely.



PATIENT

Blaze Warne

SPECIES

Feline

BREED

DSH

SEX

MN

AGE

7

WEIGHT

3.7

INTERPRETED BY

Sebastian Jawinski,
German Board
Certified Vet Specialist
in Diagnostic Imaging

IMAGING PERFORMED BY

Patricia Sanchez
Sanchez

HOSPITAL NAME

Animal Trust - Bolton

REFERRING VET

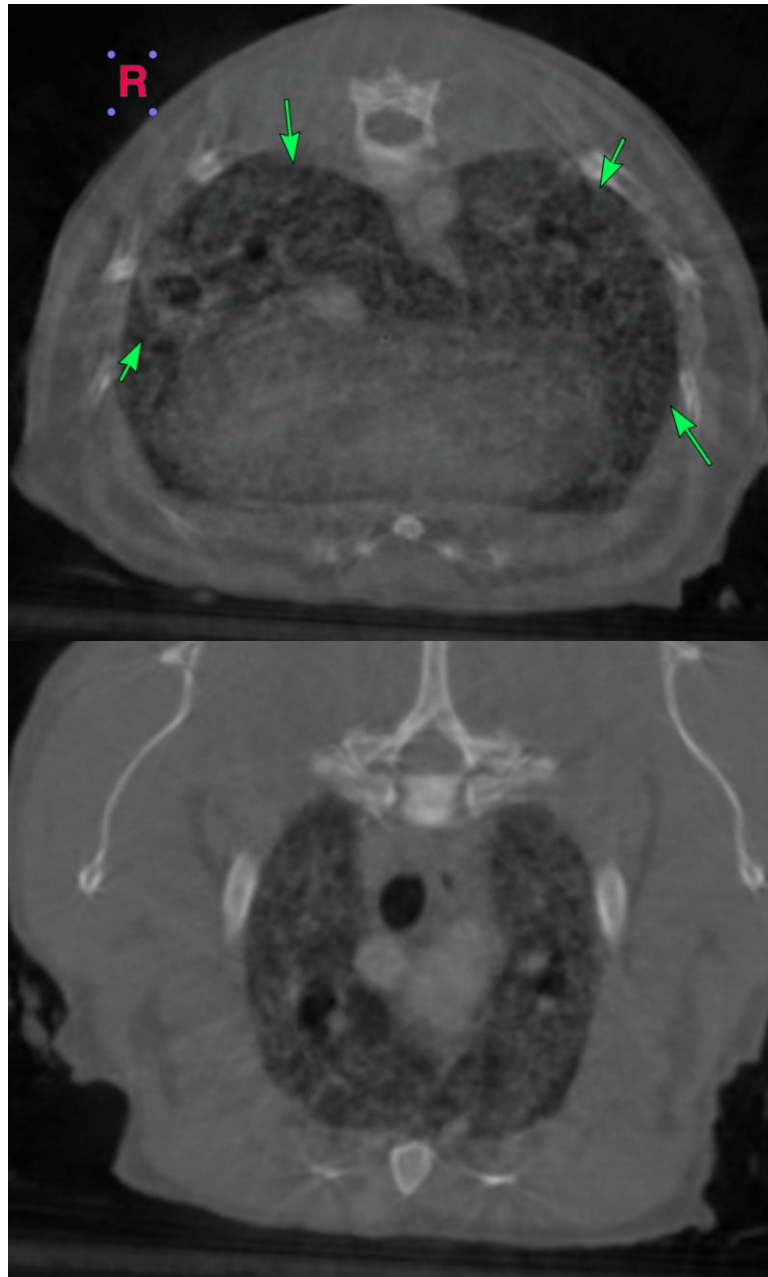
Patricia Sanchez
Sanchez

INVOICE

72812

DATE

12-2-25





PATIENT

Blaze Warne

SPECIES

Feline

BREED

DSH

SEX

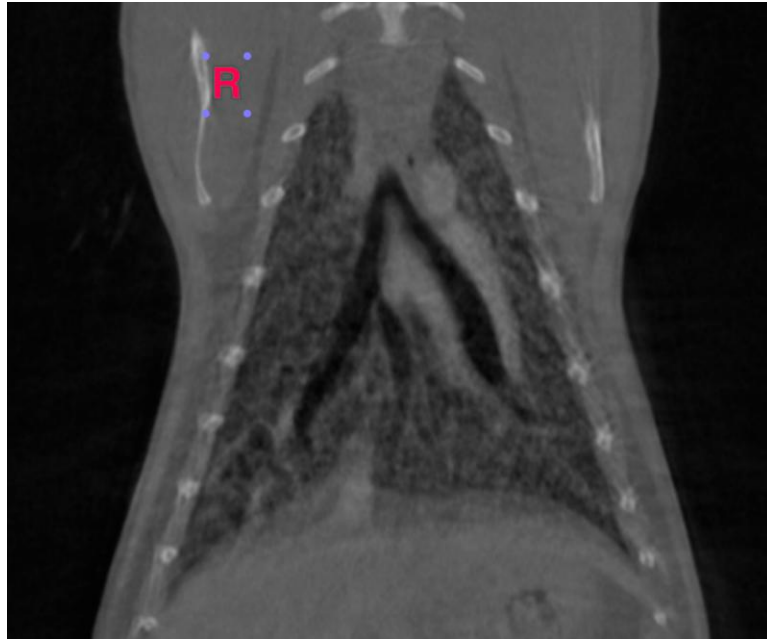
MN

AGE

7

WEIGHT

3.7



INTERPRETED BY

Sebastian Jawinski,
German Board
Certified Vet Specialist
in Diagnostic Imaging

IMAGING PERFORMED BY

Patricia Sanchez
Sanchez

HOSPITAL NAME

Animal Trust - Bolton

REFERRING VET

Patricia Sanchez
Sanchez

INVOICE

72812

DATE

12-2-25

The information and recommendations provided are based on the images presented by the referring veterinarian/sonographer. No evaluation can be communicated regarding pathology that was not visible in the image/video clips provided.

Thank you for this referral. If the clinical or image interpretation does not parallel your findings or if I can be of any further assistance, please contact me.

Sebastian Jawinski, German Board Certified Vet Specialist in Diagnostic Imaging
info@sonopath.com