



PATIENT

Lola Fenosik

SPECIES

Canine

BREED

Mixed

SEX

Female Spayed

AGE

12 Years

WEIGHT

28 lbs

INTERPRETED BY

Sebastian Jawinski,
German Board Certified
Vet Specialist in
Diagnostic Imaging

IMAGING PERFORMED BY

Dr Gabriel Ferrer DVM

HOSPITAL NAME

Pulse: Pet Ultrasound
Services

REFERRING VET

Dr Juan P. Amieiro-
Puig

INVOICE

49125

DATE

12-18-21

PRESENTING CLINICAL SIGNS

Presented for an abdominal ultrasound. Patient has a history of inappetence and decrease water consumption. Owner cannot medicate at home and pt has been hospitalized. PT has increase liver enzyme ALP and renal BUN.

Abnormal PE/Chem/CBC/UA Results: CBC: WBC: 4.9 (5-16.7) rest WNL CHEM: BUN: 34 (7-27) ALB: 4 (2.2-3.9) ALKP: 1531. (23-212) Amylase 400 (500-1500) Na 161 (144-160) IDEX 4X: All negative

ULTRASONOGRAPHIC EXAMINATION OF THE ABDOMEN

Urinary system

The urinary bladder is moderately filled and presents an irregular and diffusely thickened wall (0.48 cm) with intact wall layers. The trigone appears normal. Further caudally at the level of the cysto-urethral junction and cranial urethra marked hypoechoic thickening of the wall is recognized. Layering is indistinct here.

Ureters are not visualized and considered to be normal.

Both kidneys show an age-appropriate fuzzy corticomedullary transition. The renal pelvis on both sides appears mildly distended with diameters of 0.27 – 0.40 cm.

Adrenal glands

Both adrenal glands are normal.

Spleen

Splenic margins are mildly rounded, transverse diameters measure 1.00 cm. Splenic echogenic texture is inhomogeneous without protrusions of the capsule. Additional to that hyperechoic, perihilar infiltrates are recognized.

Splenic vasculature presents normal course of vessels and unremarkable perfusion of the splenic veins.

Liver/Gallbladder

The liver margins are rounded and appear irregular to nodular. Liver echogenicity alternates with prominent portal vessel walls. The gallbladder shows a small amount of sludge which is considered to be normal.

Gastrointestinal

The stomach, the small intestine and colon present intact wall layers being normal in width and echogenicity. Adjacent mesentery and fat tissue are of normal appearance. There is no overt evidence of an ileus, a florid-inflammatory or even neoplastic process. The mesenteric, epigastric and portal lymph nodes are considered to be normal.

Pancreas

All pancreatic parts displayed show isoechoic echogenicity to the surrounding omental fat. Signs of inflammatory changes or focal lesions are missing.

Free Abdomen



PATIENT

Lola Fenosik

There is no evidence of peritoneal or retroperitoneal effusion noted. The para-aortal and medial iliac lymph nodes are considered to be normal. The abdominal fat and great vessels show no pathological findings.

SPECIES

Canine

ULTRASONOGRAPHIC FINDINGS

Primary

- Mild hepatomegaly with an inhomogeneous/alternating echogenic texture and prominent portal veins
- Questionable loss of layering and thickening of the caudal urinary bladder wall and urethra

BREED

Mixed

Secondary

- Mild, bilateral distension renal pelvises
- Mild unspecific splenomegaly and inhomogeneous echotexture, perihilar hemangiomas/infarcts

SEX

Female Spayed

INTERPRETATION OF THE FINDINGS & FURTHER RECOMMENDATIONS

AGE

12 Years

Ultrasonographic findings of the liver do reflect the elevated liver enzymes. Changes show a mixed pattern representing chronic liver disease (chronic hepatitis, initial cirrhosis, fibrosis) and indicate an active, infiltrative process (unspecific hepatitis, vacuolar liver disease). Neoplasia cannot be ruled out but is thought to be unlikely. Final assessment is a matter of the temporary course (follow-up in 6 weeks) and ultrasound guided FNA/biopsy.

WEIGHT

28 lbs

The significant thickening of the urinary bladder wall could represent chronic cystitis. Chronic increased resistance due to obstructive disease (urethra?) is possible. Especially the indistinct layering and hypoechoic thickening at the level of the CUJ could represent early-stage neoplasia such as transitional cell carcinoma. Partial obstruction of the ureteral urine inflow would explain the mildly distended renal pelvises.

INTERPRETED BY

Sebastian Jawinski,
German Board Certified
Vet Specialist in
Diagnostic Imaging

Cystocentesis for urine culture/cytology as well as a follow-up ultrasound in 3 weeks after initial/empiric therapy (antibiotics, COX II inhibitors) could be the next diagnostic steps.

IMAGING PERFORMED BY

Dr Gabriel Ferrer DVM

Splenomegaly is unspecific. The inhomogeneous texture and the perihilar infiltrates are commonly seen with age-related findings and extramedullary hematopoiesis and/or benign lymphoid hyperplasia. Neoplastic infiltration and splenitis are further differentials but unlikely.

HOSPITAL NAME

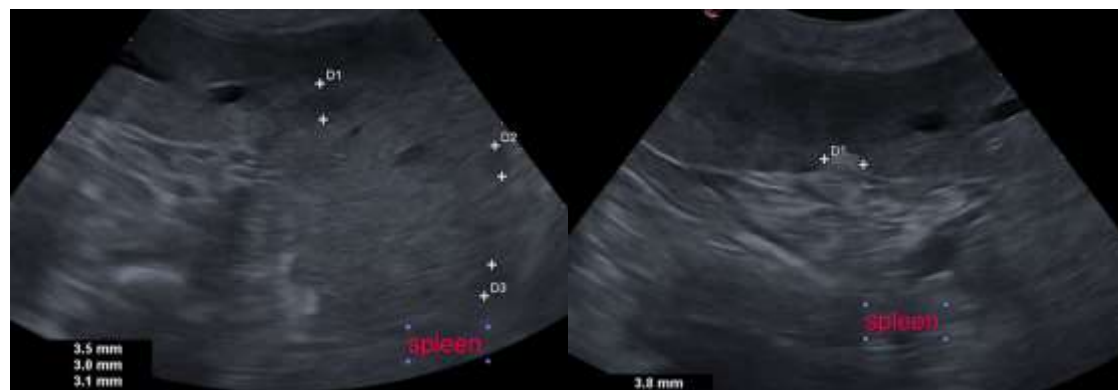Pulse: Pet Ultrasound
Services

REFERRING VET

Dr Juan P. Amieiro-
Puig

INVOICE

49125



DATE

12-18-21



PATIENT

Lola Fenosik

SPECIES

Canine

BREED

Mixed

SEX

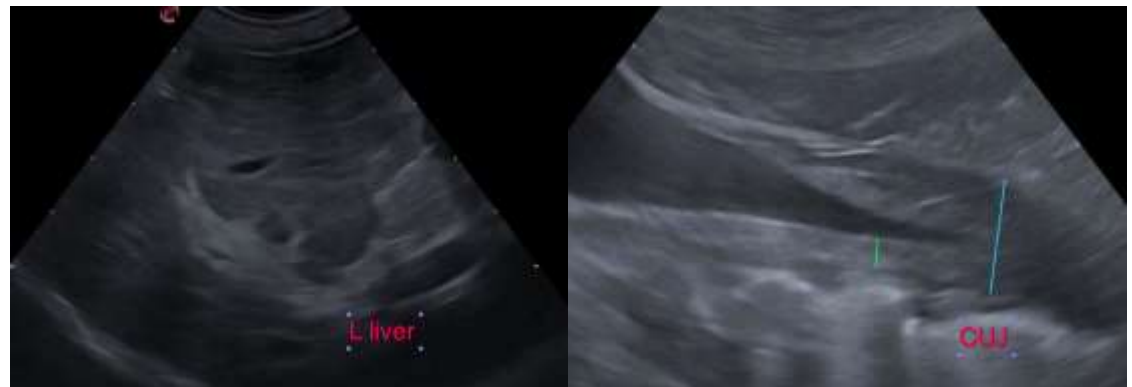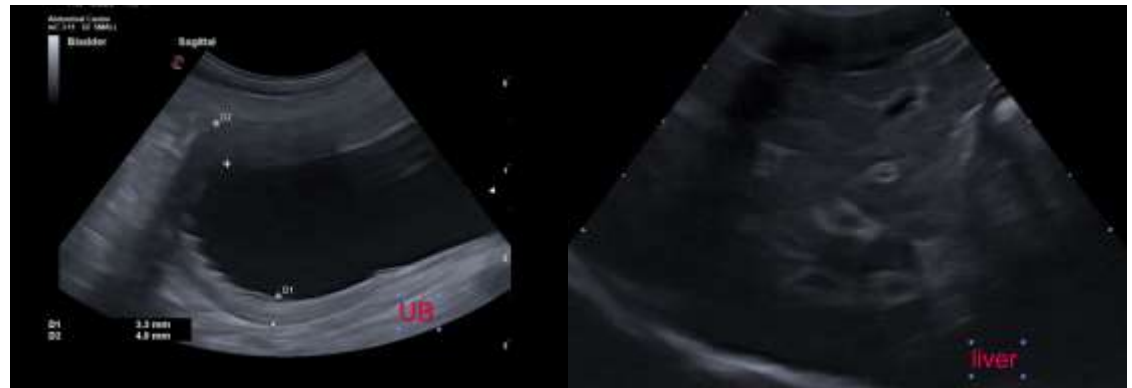
Female Spayed

AGE

12 Years

WEIGHT

28 lbs



INTERPRETED BY

Sebastian Jawinski,
German Board Certified
Vet Specialist in
Diagnostic Imaging

**IMAGING
PERFORMED BY**

Dr Gabriel Ferrer DVM

HOSPITAL NAME

Pulse: Pet Ultrasound
Services

REFERRING VET

Dr Juan P. Amieiro-
Puig

INVOICE

49125

DATE

12-18-21

The information and recommendations provided are based on the images presented by the referring veterinarian. No evaluation can be communicated regarding pathology that was not visible in the image/video clips provided.

Thank you for this referral. If the clinical or image interpretation does not parallel your findings or if I can be of any further assistance please contact me.

Sebastian Jawinski, German Board Certified Vet Specialist in Diagnostic Imaging
info@sonopath.com