



PATIENT

Coconut Harris

PRESENTING CLINICAL SIGNS

Straining to urinate with minimal urine production. Seen as an emergency last month where they suspected a mass at the urinary bladder trigone.

SPECIES

Canine

COMPUTED TOMOGRAPHIC STUDY OF THE ABDOMEN

Pre/post contrast studies provided for review.

BREED

Yorkie

COMPUTED TOMOGRAPHIC FINDINGS

Liver and spleen show normal findings in terms of size, surface, shape and contrast behavior. Gallbladder is inconspicuous without evidence of cholestasis presenting a small number of calculi. The common bile duct is considered to be normal.

SEX

Female Spayed

Pancreas presents normal size and shape with a smooth surface. The peripancreatic fat tissue and omentum are inconspicuous.

AGE

12 Years

Unremarkable presentation of the bilaterally symmetrical kidneys. There is no evidence of pelvic distension recognized. Adrenal glands are in normal limits.

INTERPRETED BY

Sebastian Jawinski,
German Board
Certified Vet
Specialist in
Diagnostic Imaging

The intra-pelvic section of the rectum appears moderately thickened with transverse diameters of 0.45 cm with mild deviation to the left caused by a highly filled urinary bladder reaching far caudal on the right. The surrounding fat tissue is inconspicuous. A soft tissue dense swelling is indicated in the area of the trigones and the urethra. Urinary inflow is bilaterally inconspicuous. There is no evidence of mineralized cystic calculi.

Stomach and all other parts of intestines are regularly presented without any indication of a wall thickening or a mass. There are no signs of an obstructive or functional ileus.

HOSPITAL NAME

Mobile Pet Imaging

The right medial iliac lymph node is mildly enlarged but inconspicuous in shape, enhancement and periphery. All other abdominal lymph nodes and abdominal vessels have no particular findings. Signs of peritoneal/retroperitoneal effusion or free gas are not recognized.

REFERRING VET

Meaux

COMPUTED TOMOGRAPHIC DIAGNOSIS

- Right caudal displacement of the urinary bladder
- Thickening of the CUJ and the rectal wall
- Mild adenomegaly right medial iliac lymph node

INVOICE

49000

INTERPRETATION OF THE FINDINGS & FURTHER RECOMMENDATIONS

DATE

12-13-21

The caudal displacement of the bladder on the right side with deviation of the intra-pelvic structures could represent perineal herniation on the right (rectal examination?). The suspected soft tissue swelling at the level of the cysto-urethral junction is unspecific and could be due to an inflammatory or neoplastic process. Signs of a ureteral/renal pelvic distension caused by an



PATIENT

Coconut Harris

obstructive lesion are not recognized. Changes of the right medial iliac lymph node still is consistent with a reactive-inflammatory process. Neoplasia of the trigones/CUJ and urethra cannot be fully excluded. Complementary ultrasound is recommended.

SPECIES

Canine

The rectal thickening may be secondary to chronic tenesmus. This again is not very specific from a CT perspective and colitis/rectal neoplasia are possible.

Currently signs of an aggressive/local invasive process are missing.

BREED

Yorkie

SEX

Female Spayed

AGE

12 Years

INTERPRETED BY

Sebastian Jawinski,
German Board
Certified Vet
Specialist in
Diagnostic Imaging

HOSPITAL NAME

Mobile Pet Imaging

REFERRING VET

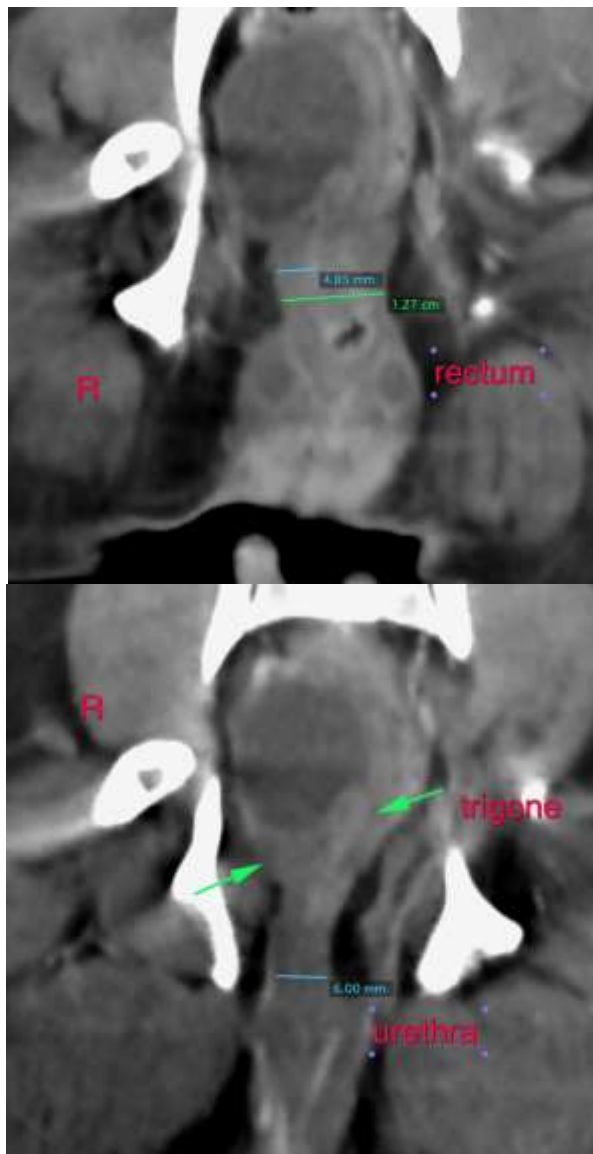
Meaux

INVOICE

49000

DATE

12-13-21





PATIENT

Coconut Harris

SPECIES

Canine

BREED

Yorkie

SEX

Female Spayed

AGE

12 Years

INTERPRETED BY

Sebastian Jawinski,
German Board
Certified Vet
Specialist in
Diagnostic Imaging

HOSPITAL NAME

Mobile Pet Imaging

REFERRING VET

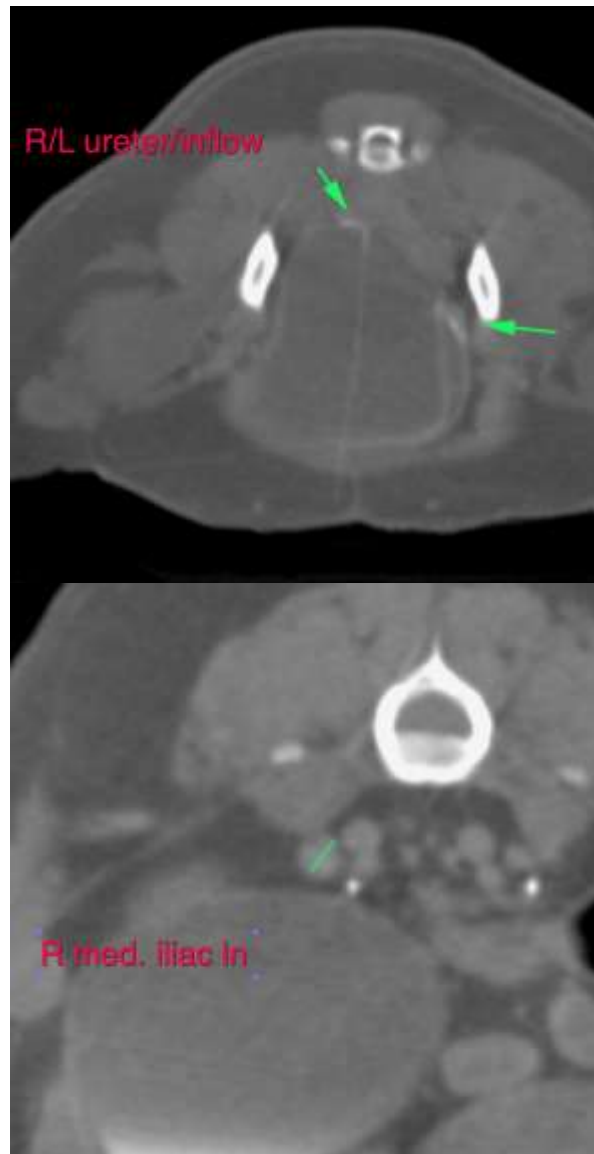
Meaux

INVOICE

49000

DATE

12-13-21



The information and recommendations provided are based on the images presented by the referring veterinarian. No evaluation can be communicated regarding pathology that was not visible in the image/video clips provided.

Thank you for this referral. If the clinical or image interpretation does not parallel your findings or if I can be of any further assistance, please contact me.

Sebastian Jawinski, German Board Certified Vet Specialist in Diagnostic Imaging
Sebastian.Jawinski@sonopath.com