



## PATIENT

Harper Greevy

## SPECIES

Canine

## BREED

Beagle

## SEX

FS

## AGE

7Y, 8M

## WEIGHT

15.2kg

## INTERPRETED BY

Sebastian Jawinski,  
German Board  
Certified Vet Specialist  
in Diagnostic Imaging

## IMAGING PERFORMED BY

Ana

## HOSPITAL NAME

Animal Trust - Bolton

## REFERRING VET

Ana Valega

## INVOICE

72536

## DATE

11-6-25

## PRESENTING CLINICAL SIGNS

External referral. First episode 26/06/25 after reverse sneezing tongue turned blue and her eyes were rolling. O had to keep hold of tongue until dog came round. also brought up white bile. Has been having recurrent similar episodes since. Has been on omeprazol + meloxicam, but only mild improvement seen. Elongated soft palate suspected.

Abnormal PE/Chem/CBC/UA Results: WNL

## COMPUTED TOMOGRAPHY OF THE HEAD & NECK

Pre/post contrast studies are provided for review.

## COMPUTED TOMOGRAPHIC FINDINGS

The soft palate presents moderate hyperplasia with maximum and estimated transverse diameters of 1.2 cm. The laryngeal structures appear hyperplastic as well, leading to a narrowing of the larynx. Both nasal cavities and frontal sinuses are regularly ventilated as well as the nasopharyngeal meatus, both tympanic bullae and the external ear canals.

The trachea shows an impression of the dorsal margin in its cervical part and partially in the thoracic course, indicating tracheal collapse. The bifurcation and bronchi are inconspicuous. The pulmonary structures do not show nodular or focal changes. Free pleural fluid is not noted. The mediastinum shows marked fat storage as well as the subcutaneous, interfascial and intermuscular regions.

The neurocranium is inconspicuous. Signs of a pathologic enhancement and or mass effect are not recognized. The cervical lymph nodes and salivary glands are unremarkable.

The right side shows an abnormal vein running parallel to the carotid artery. The jugular vein is seen on the left side and cannot be traced on the right side. Both thyroid glands are inconspicuous.

The thoracic borders are intact, including the diaphragm.

## COMPUTED TOMOGRAPHIC DIAGNOSIS

- Significant hyperplasia of the soft palate and laryngeal structures
- Indicated tracheal collapse
- Abnormal vein right neck with an absent jugular vein
- Moderate subcutaneous, interfascial, intermuscular and mediastinal fat storage

## INTERPRETATION OF THE FINDINGS & FURTHER RECOMMENDATIONS

The CT findings show moderate hyperplasia of the soft palate and significant swelling of the laryngeal structures. These could represent edematous or inflammatory changes leading to a dynamic narrowing of the upper airways. The dorsal impression of the trachea indicates tracheal collapse. This again may be a dynamic issue.



## PATIENT

Harper Greevy

## SPECIES

Canine

## BREED

Beagle

## SEX

FS

## AGE

7Y, 8M

## WEIGHT

15.2kg

## INTERPRETED BY

Sebastian Jawinski,  
German Board  
Certified Vet Specialist  
in Diagnostic Imaging

## IMAGING PERFORMED BY

Ana

## HOSPITAL NAME

Animal Trust - Bolton

## REFERRING VET

Ana Valega

## INVOICE

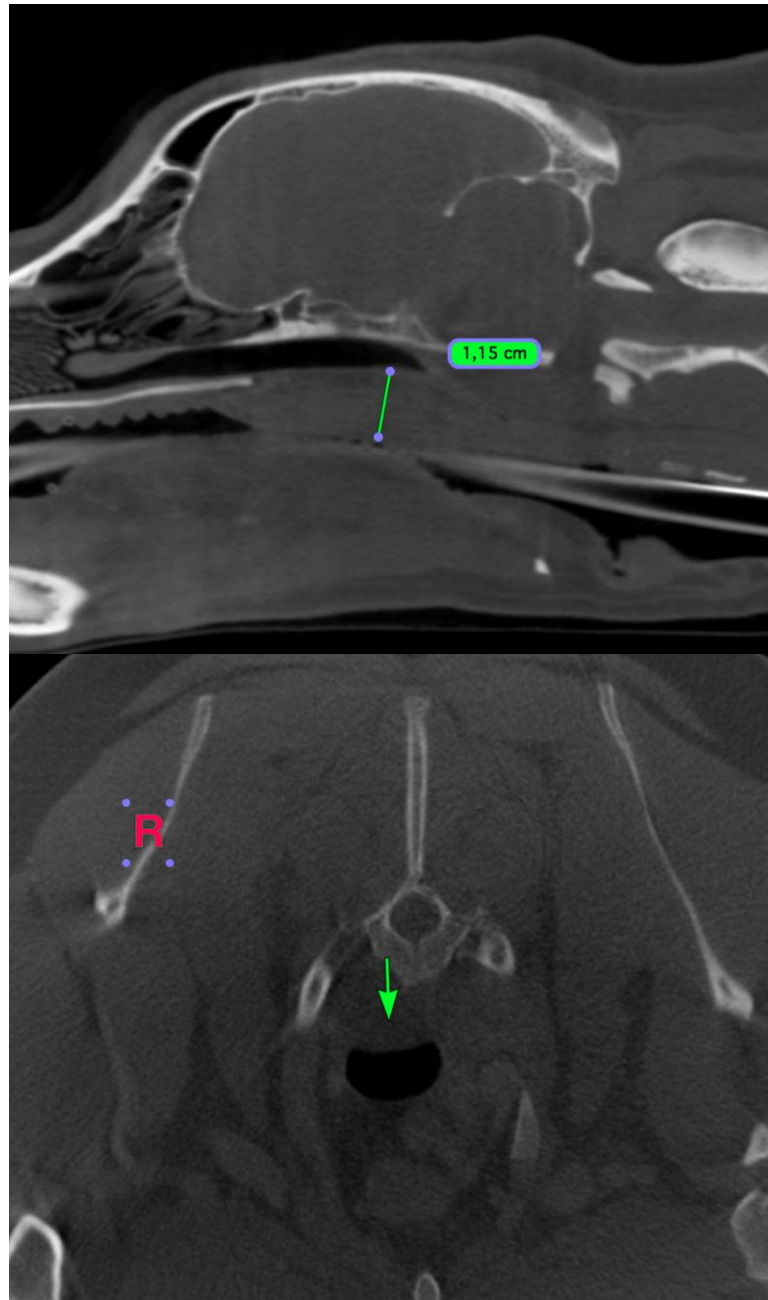
72536

## DATE

11-6-25

The missing jugular vein on the right side could represent an abnormal finding as seen with a aplasia of the vessel. This likely is not of clinical relevance.

For further assessment, endoscopic evaluation and sampling could be performed next. Currently, there are no signs of an aggressive or invasive lesion as seen with neoplasia.





## PATIENT

Harper Greevy

## SPECIES

Canine

## BREED

Beagle

## SEX

FS

## AGE

7Y, 8M

## WEIGHT

15.2kg

## INTERPRETED BY

Sebastian Jawinski,  
German Board  
Certified Vet Specialist  
in Diagnostic Imaging

## IMAGING PERFORMED BY

Ana

## HOSPITAL NAME

Animal Trust - Bolton

## REFERRING VET

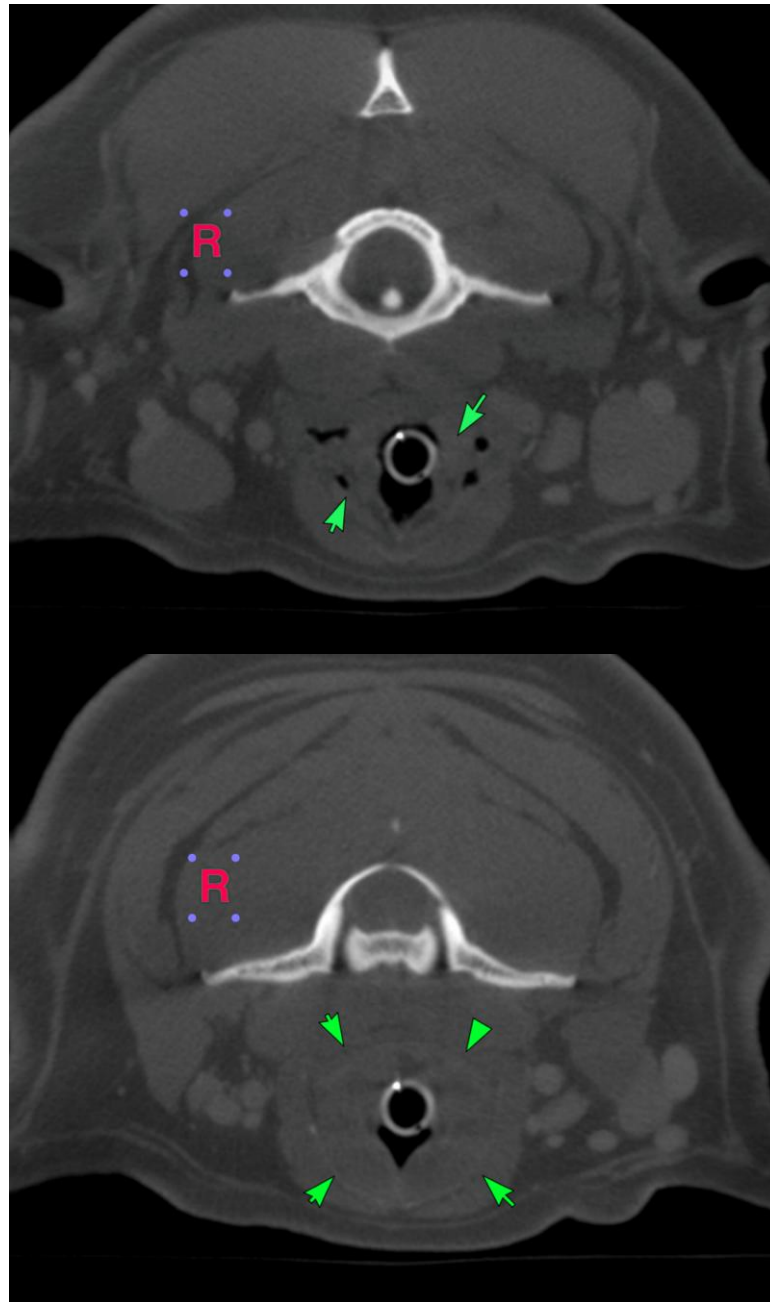
Ana Valega

## INVOICE

72536

## DATE

11-6-25





## PATIENT

Harper Greevy

## SPECIES

Canine

## BREED

Beagle

## SEX

FS

## AGE

7Y, 8M

## WEIGHT

15.2kg

## INTERPRETED BY

Sebastian Jawinski,  
German Board  
Certified Vet Specialist  
in Diagnostic Imaging

## IMAGING PERFORMED BY

Ana

## HOSPITAL NAME

Animal Trust - Bolton

## REFERRING VET

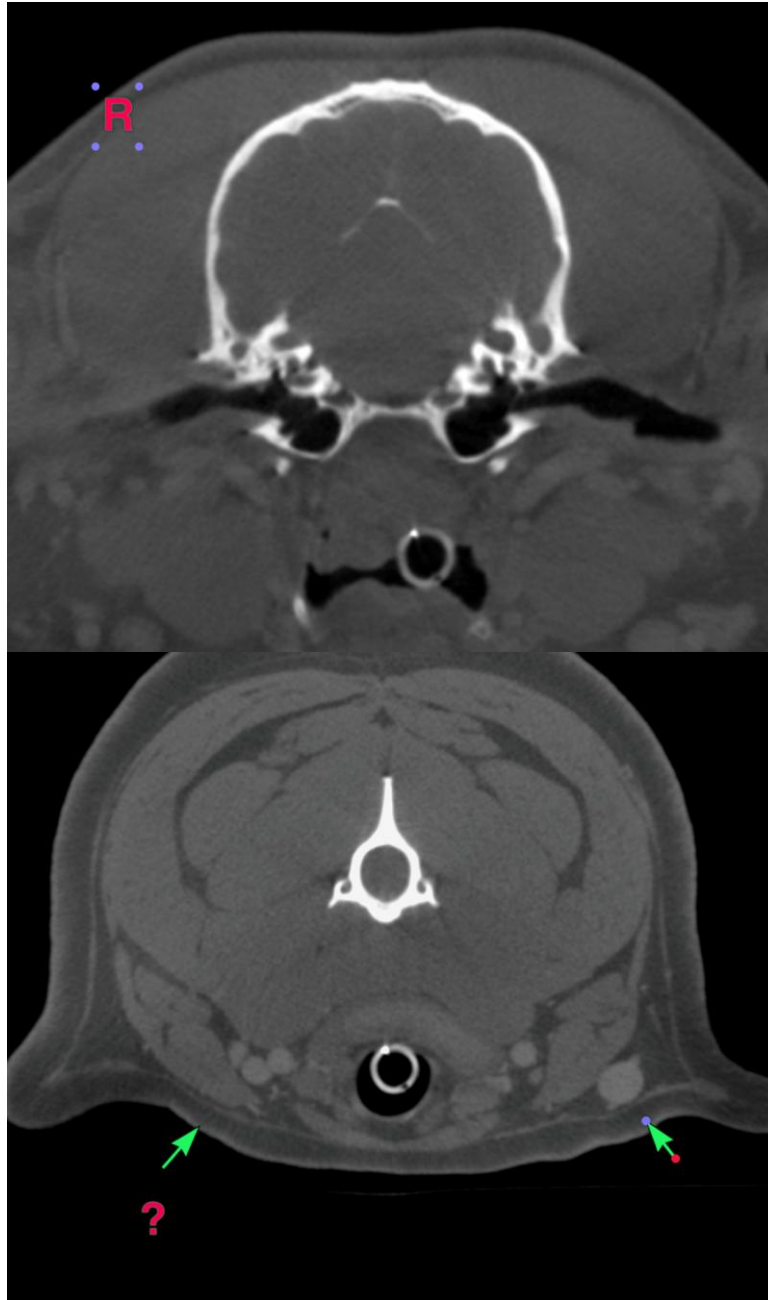
Ana Valega

## INVOICE

72536

## DATE

11-6-25





## PATIENT

Harper Greevy

## SPECIES

Canine

## BREED

Beagle

## SEX

FS

## AGE

7Y, 8M

## WEIGHT

15.2kg

## INTERPRETED BY

Sebastian Jawinski,  
German Board  
Certified Vet Specialist  
in Diagnostic Imaging

## IMAGING PERFORMED BY

Ana

## HOSPITAL NAME

Animal Trust - Bolton

## REFERRING VET

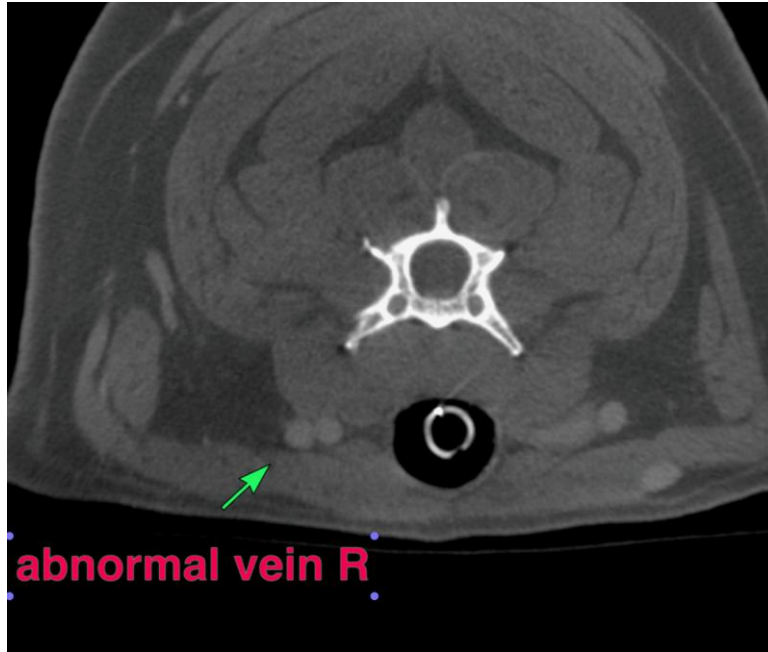
Ana Valega

## INVOICE

72536

## DATE

11-6-25



The information and recommendations provided are based on the images presented by the referring veterinarian/sonographer. No evaluation can be communicated regarding pathology that was not visible in the image/video clips provided.

Thank you for this referral. If the clinical or image interpretation does not parallel your findings or if I can be of any further assistance, please contact me.

Sebastian Jawinski, German Board Certified Vet Specialist in Diagnostic Imaging  
[info@sonopath.com](mailto:info@sonopath.com)