

## PATIENT

Flower Negro

## SPECIES

Canine

## BREED

English Bulldog

## SEX

Spayed Female

## AGE

2

## WEIGHT

22

## INTERPRETED BY

Sebastian Jawinski,  
German Board  
Certified Vet Specialist  
in Diagnostic Imaging

## IMAGING PERFORMED BY

David

## HOSPITAL NAME

ASC Oceanside

## REFERRING VET

Dr. Infernuso

## INVOICE

35433

## DATE

11/6/25

## PRESENTING CLINICAL SIGNS

History: Respiratory issues

## COMPUTED TOMOGRAPHIC STUDY OF THE HEAD, NECK, CHEST

The head presents a severe brachycephalic formation with a significant inferior brachygnathia, a shortening of the nasal cavities, signs of mucous membrane swelling and a severe hyperplasia of the soft palate. The latter shows transverse diameters of approximately 1.9 cm, leading to an obstruction of the laryngeal and pharyngeal region.

The trachea appears hypoplastic with severe malformations of the spine and the /chest and sternum. Especially the thoracic inlet is markedly narrowed with an estimated diameter of 2.5 cm. Due to the narrowed thoracic inlet, the course of the trachea is turning and located more on the right side. The bronchi appear narrowed as well.

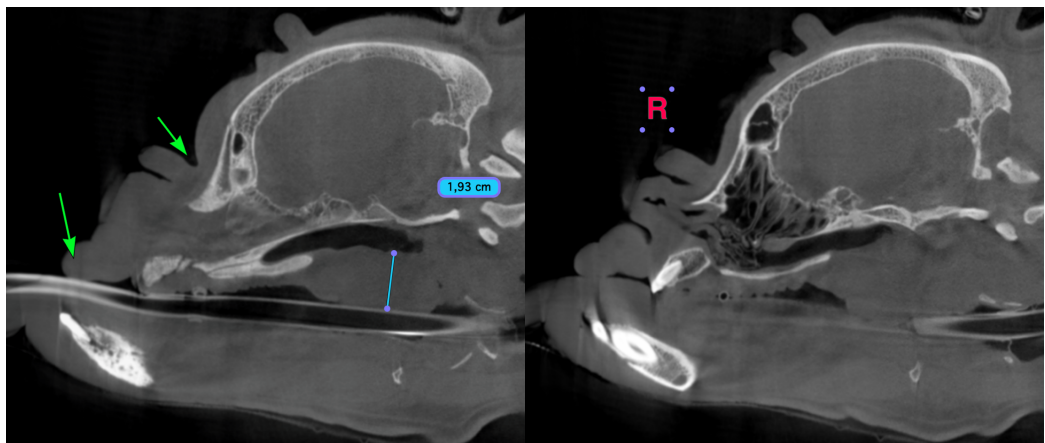
The pulmonary structures present an increased interstitial density with mild bronchial thickening and peri-bronchial infiltrates. Relevant nodular or focal pulmonary changes are not noted. The mediastinum is thickened, presenting a shift to the left side due to the chest malformation.

## COMPUTED TOMOGRAPHIC DIAGNOSIS

- Brachycephalic airway obstruction due to a severe brachycephalic head formation, soft palate hyperplasia and hypoplasia of the trachea as well as malformations of the chest
- Broncho-interstitial lung pattern

## INTERPRETATION OF THE FINDINGS & FURTHER RECOMMENDATIONS

The changes and malformations of the head and the chest are somewhat breed-expected and do explain the reported patient's history of breathing difficulties. Especially the hyperplasia of the soft palate and the shortening of the nasal cavities, as well as the hypoplasia of the trachea and the chest malformations would underline this assumption. These are chronic and congenital findings. Acute onsets and secondary bacterial infections are possible. The broncho-interstitial lung pattern likely present mild and chronic bronchopneumonia.





## PATIENT

Flower Negro

## SPECIES

Canine

## BREED

English Bulldog

## SEX

Spayed Female

## AGE

2

## WEIGHT

22

## INTERPRETED BY

Sebastian Jawinski,  
German Board  
Certified Vet Specialist  
in Diagnostic Imaging

## IMAGING PERFORMED BY

David

## HOSPITAL NAME

ASC Oceanside

## REFERRING VET

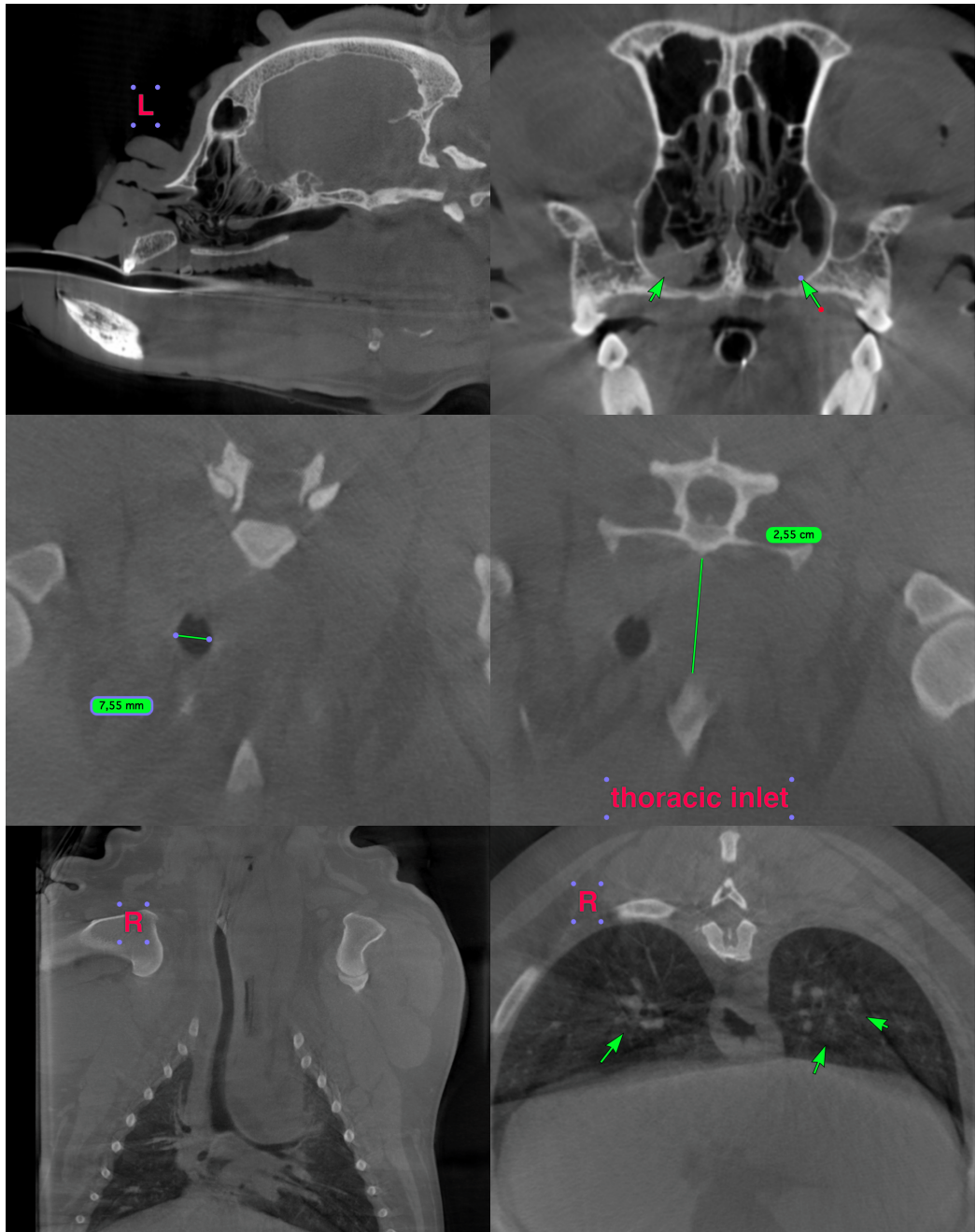
Dr. Infernuso

## INVOICE

35433

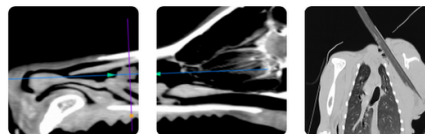
## DATE

11/6/25



The information and recommendations provided are based on the images presented by the referring veterinarian/sonographer. No evaluation can be communicated regarding pathology that was not visible in the image/video clips provided.

Thank you for this referral. If the clinical or image interpretation does not parallel your findings or if I can be of any further assistance, please contact me.



## PATIENT

**Sebastian Jawinski, German Board Certified Vet Specialist in Diagnostic Imaging**

[info@sonopath.com](mailto:info@sonopath.com)

Flower Negro

## SPECIES

Canine

## BREED

English Bulldog

## SEX

Spayed Female

## AGE

2

## WEIGHT

22

## INTERPRETED BY

Sebastian Jawinski,  
German Board  
Certified Vet Specialist  
in Diagnostic Imaging

## IMAGING PERFORMED BY

David

## HOSPITAL NAME

ASC Oceanside

## REFERRING VET

Dr. Infernuso

## INVOICE

35433

## DATE

11/6/25