



PATIENT

Luca Grasso

SPECIES

Canine

BREED

Yorkie

SEX

Neutered Male

AGE

6Y

WEIGHT

11.5lbs

INTERPRETED BY

Sebastian Jawinski,
German Board
Certified Vet Specialist
in Diagnostic Imaging

IMAGING PERFORMED BY

GC/JA

HOSPITAL NAME

The Pet Hospital of
Stratford

REFERRING VET

Dr. Bashkin, DVM

INVOICE

72481

DATE

11-4-25

PRESENTING CLINICAL SIGNS

Luca presents for v/d. Diarrhea started on Thursday and has gotten worse - went from soft, to liquid to now mostly bloody with mucus. He vomited 2x today (food, then water). No hx of toxin exposure. Nothing he could have gotten into. Still eating, BAR.

RADIOGRAPHIC FINDINGS

Abdomen

The displayed bony structures of spine, pelvis and thorax are within normal limits.

Liver and spleen present as expected and are well defined. The serosal detail is within normal limits. Stomach and intestines are predominantly empty with prominent distention and gas filling of the intestinal loops and the colon. Besides that, some fluid filled small intestinal loops are recognized. There is residual "structured" ingesta noted likely in the ileocecal course.

Both kidneys are not well visualized but considered to be normal. There are no signs of peritoneal or retroperitoneal effusion. Urinary bladder is nearly empty without signs of radiopaque cystic calculi.

RADIOGRAPHIC DIAGNOSIS

- Prominent distention of the gastrointestinal tract with a mixed pattern of fluid- and gas filled loops
- Questionable "structured" ileocecal ingesta

INTERPRETATION OF THE FINDINGS & FURTHER RECOMMENDATIONS

The prominent distention of the intestinal loops and gas filling are commonly recognized with nonspecific and inflammatory issues as seen with enteritis/gastritis. The questionable structured ingesta in the ileocecal course may represent residuals of normal ingesta. The structured and tissue-like pattern may indicate foreign material. The radiographs currently do not justify the diagnosis of an obstructive or paralytic ileus. This may change with the temporal course. As far as can be assessed, there are no significant signs of a generalized inflammation as noted with peritonitis and pancreatitis.



PATIENT

Luca Grasso

SPECIES

Canine

BREED

Yorkie

SEX

Neutered Male

AGE

6Y

WEIGHT

11.5lbs

INTERPRETED BY

Sebastian Jawinski,
German Board
Certified Vet Specialist
in Diagnostic Imaging

IMAGING PERFORMED BY

GC/JA

HOSPITAL NAME

The Pet Hospital of
Stratford

REFERRING VET

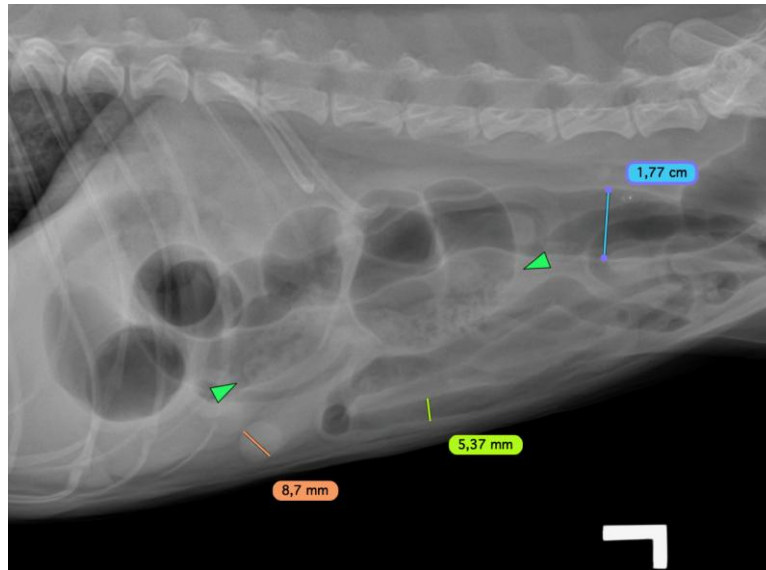
Dr. Bashkin, DVM

INVOICE

72481

DATE

11-4-25



The information and recommendations provided are based on the images presented by the referring veterinarian/sonographer. No evaluation can be communicated regarding pathology that was not visible in the image/video clips provided.

Thank you for this referral. If the clinical or image interpretation does not parallel your findings or if I can be of any further assistance, please contact me.

Sebastian Jawinski, German Board Certified Vet Specialist in Diagnostic Imaging
info@sonopath.com