



PATIENT

Buddha Depasquale

SPECIES

Canine

BREED

Multipoo

SEX

MN

AGE

12Y

WEIGHT

22

INTERPRETED BY

Sebastian Jawinski,
German Board
Certified Vet Specialist
in Diagnostic Imaging

IMAGING PERFORMED BY

Shari Reffi, CVT

HOSPITAL NAME

All Creatures Great
and Small Denville

REFERRING VET

Dr. Silas

INVOICE

72462

DATE

11-3-25

PRESENTING CLINICAL SIGNS

Limping R leg + Painful. Drawer test + possible partial or total rupture ACL R Leg

ULTRASONOGRAPHIC FINDINGS

Right Stifle

The displayed bony surfaces present mild osteophytic reactions at the proximal and distal tip of the patella and the tibial and femoral bone surfaces. The chondral structures appear regular as far as can be assessed. The infrapatellar fat body is mildly inhomogeneous without relevant signs of effusion. The patellar ligament appears inconspicuous.

There are fibers following the course of the anterior cruciate ligament (ACL) with a broad and hypo- to anechoic halo. In the flexed loops, a hyperechoic, stump-like structure is recognized, just cranial to the ACL. The medial meniscus shows a prolapse without signs of an intrameniscal lesion. The lateral meniscus is inconspicuous.

Left Stifle

In comparison to the right side, the left stifle presents more prominent degenerative findings with moderate osteophytic reactions at all joint levels and a more inhomogeneous infrapatellar fat body. There is a scant amount of joint effusion noted in the suprapatellar area. The patellar ligament is intact and inconspicuous. The anterior cruciate ligament is normal in cause and diameter, presenting mild inhomogeneous and hyperechoic changes within the ligament. A significant halo and/or swelling are not noted. Both menisci present degenerative findings without obvious evidence of a rupture/tear.

ULTRASONOGRAPHIC DIAGNOSIS

- Suspected partial tear of the right ACL with ligamentous edema
- Suspected lesion right medial meniscus
- Mild degenerative findings right stifle
- Moderate degenerative findings left stifle consistent with moderate and "age-expected" osteoarthritis

INTERPRETATION OF THE FINDINGS & FURTHER RECOMMENDATIONS

The indicated hyperechoic stump and the hypo - to anechoic halo surrounding the ACL are suspicious for a partial rupture/tear of the ACL. There are fibers recognized following the normal course of the ACL which would speak against a complete rupture. The protruding medial meniscus indicates a lesion of the latter. The mild degenerative findings of the bony surfaces are somewhat age-expected. Signs of relevant reactive/inflammatory or even aggressive lesion are missing.



PATIENT

Buddha Depasquale

SPECIES

Canine

BREED

Maltipoo

SEX

MN

AGE

12Y

WEIGHT

22

INTERPRETED BY

Sebastian Jawinski,
German Board
Certified Vet Specialist
in Diagnostic Imaging

IMAGING PERFORMED BY

Shari Reffi, CVT

HOSPITAL NAME

All Creatures Great
and Small Denville

REFERRING VET

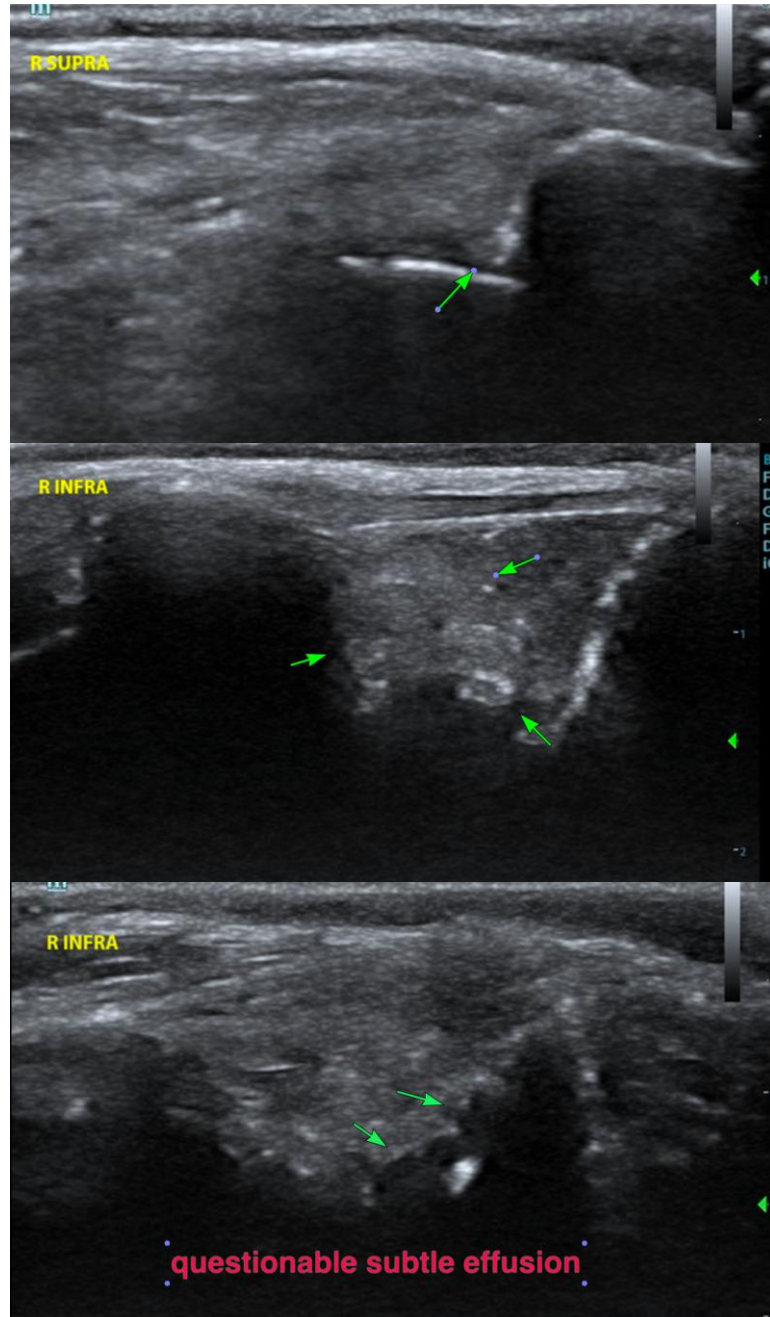
Dr. Silas

INVOICE

72462

DATE

11-3-25





PATIENT

Buddha Depasquale

SPECIES

Canine

BREED

Maltipoo

SEX

MN

AGE

12Y

WEIGHT

22

INTERPRETED BY

Sebastian Jawinski,
German Board
Certified Vet Specialist
in Diagnostic Imaging

IMAGING PERFORMED BY

Shari Reffi, CVT

HOSPITAL NAME

All Creatures Great
and Small Denville

REFERRING VET

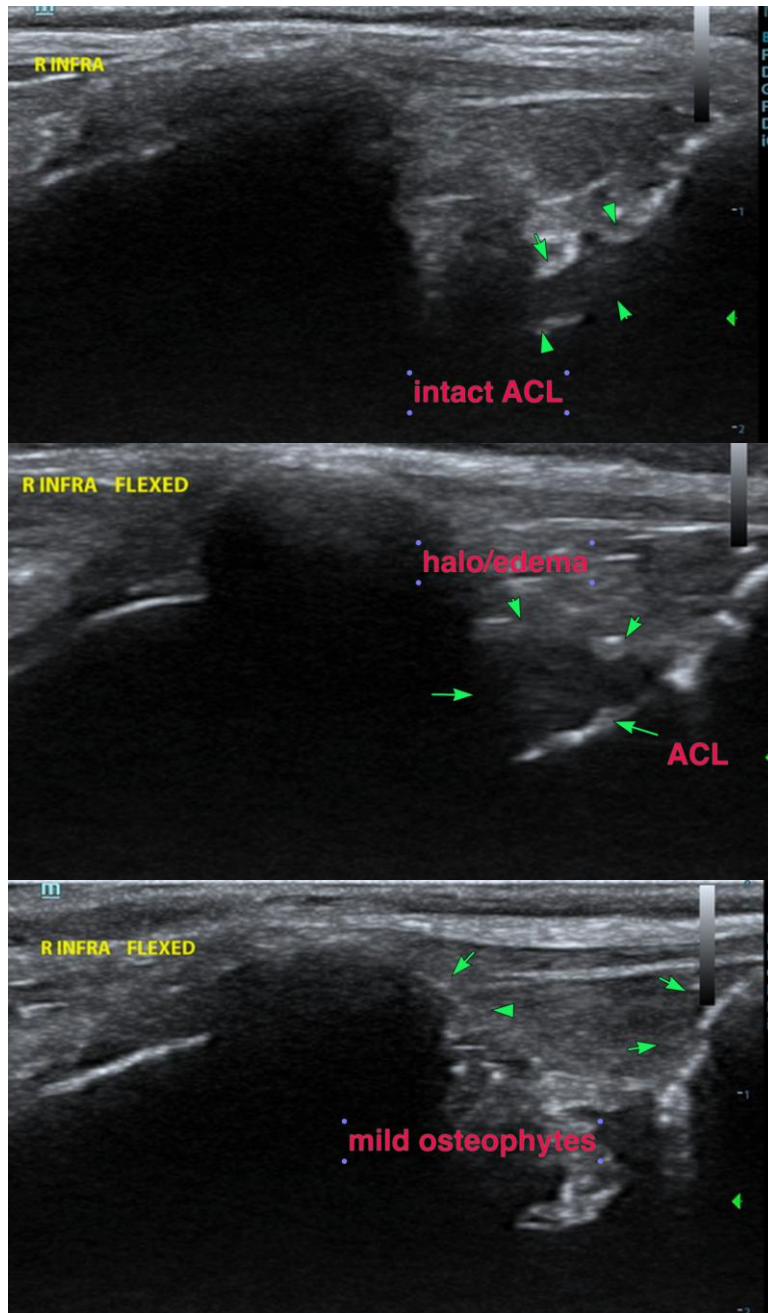
Dr. Silas

INVOICE

72462

DATE

11-3-25





PATIENT

Buddha Depasquale

SPECIES

Canine

BREED

Maltipoo

SEX

MN

AGE

12Y

WEIGHT

22

INTERPRETED BY

Sebastian Jawinski,
German Board
Certified Vet Specialist
in Diagnostic Imaging

IMAGING PERFORMED BY

Shari Reffi, CVT

HOSPITAL NAME

All Creatures Great
and Small Denville

REFERRING VET

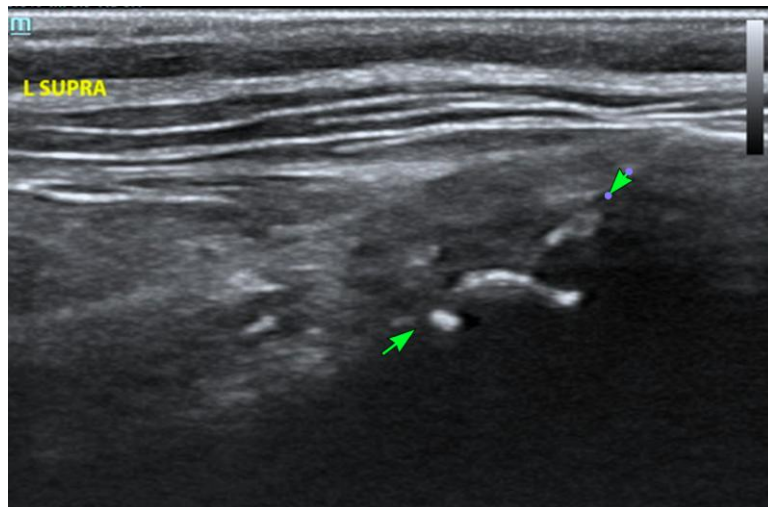
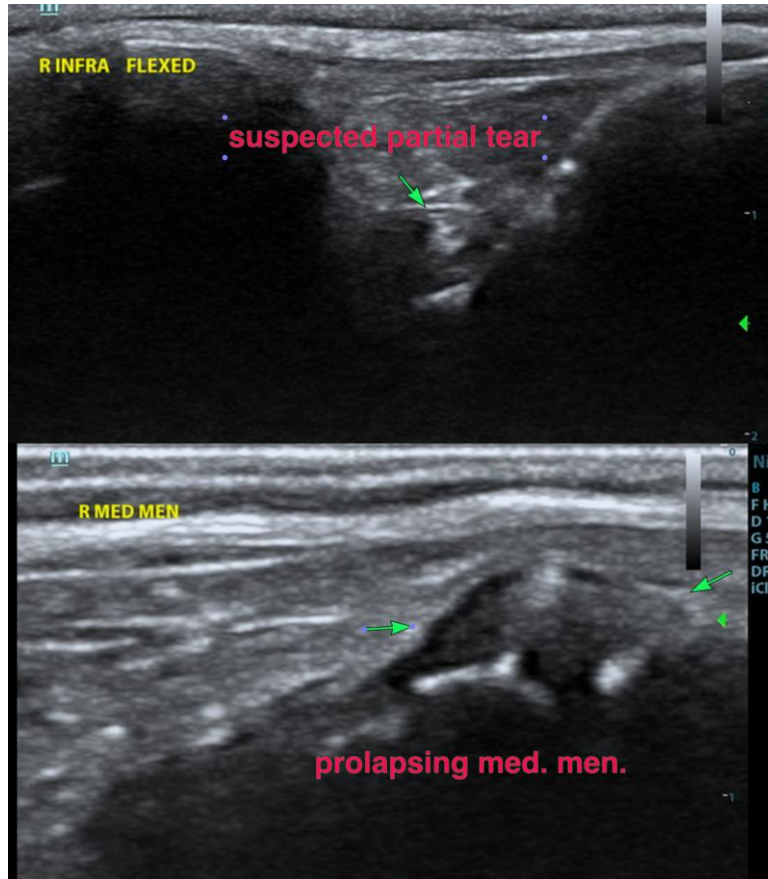
Dr. Silas

INVOICE

72462

DATE

11-3-25





PATIENT

Buddha Depasquale

SPECIES

Canine

BREED

Maltipoo

SEX

MN

AGE

12Y

WEIGHT

22

INTERPRETED BY

Sebastian Jawinski,
German Board
Certified Vet Specialist
in Diagnostic Imaging

IMAGING PERFORMED BY

Shari Reffi, CVT

HOSPITAL NAME

All Creatures Great
and Small Denville

REFERRING VET

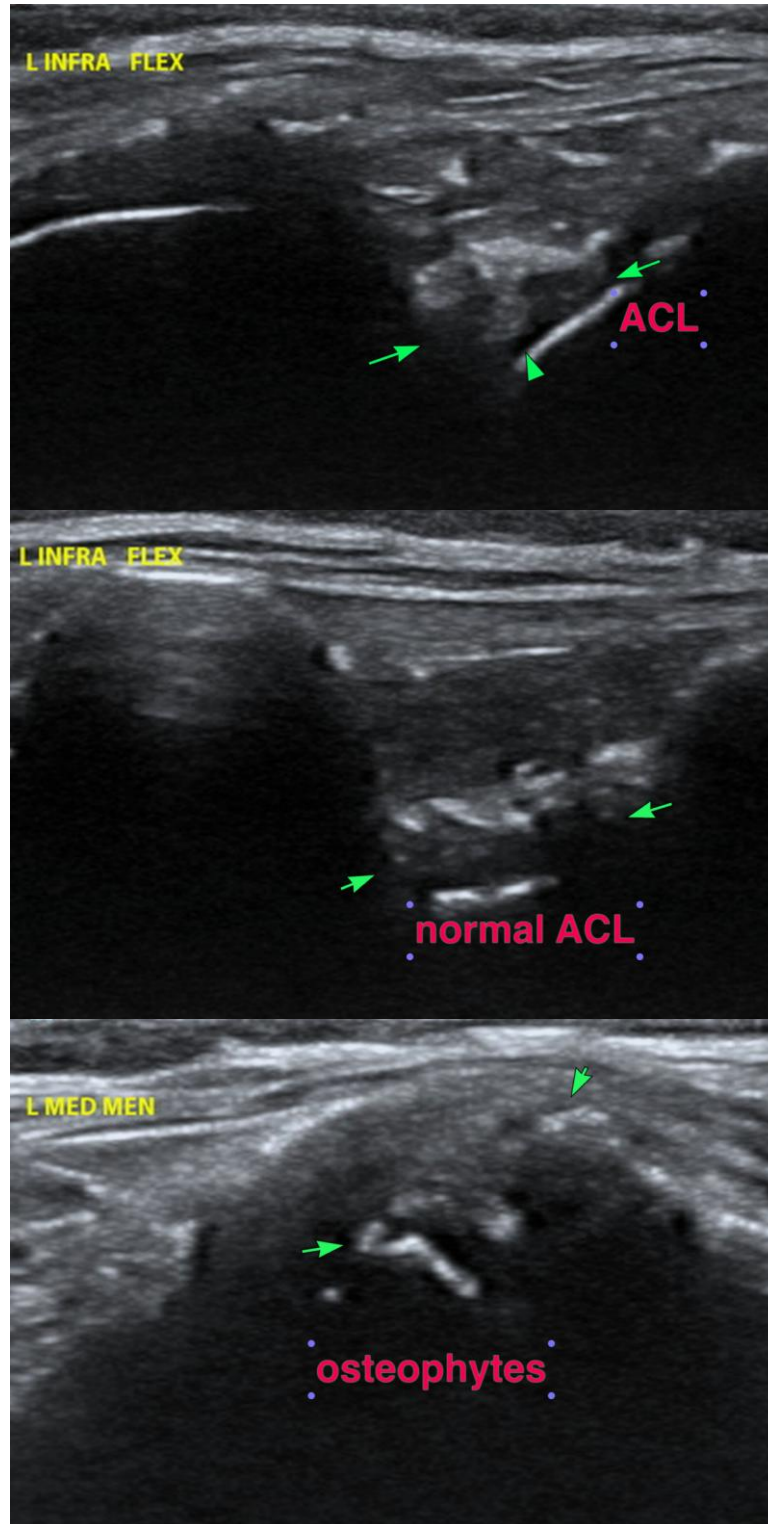
Dr. Silas

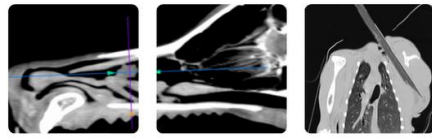
INVOICE

72462

DATE

11-3-25





PATIENT

Buddha Depasquale

SPECIES

Canine

BREED

Maltipoo

SEX

MN

AGE

12Y

WEIGHT

22

INTERPRETED BY

Sebastian Jawinski,
German Board
Certified Vet Specialist
in Diagnostic Imaging

IMAGING PERFORMED BY

Shari Reffi, CVT

HOSPITAL NAME

All Creatures Great
and Small Denville

REFERRING VET

Dr. Silas

INVOICE

72462

DATE

11-3-25

The information and recommendations provided are based on the images presented by the referring veterinarian/sonographer. No evaluation can be communicated regarding pathology that was not visible in the image/video clips provided.

Thank you for this referral. If the clinical or image interpretation does not parallel your findings or if I can be of any further assistance, please contact me.

Sebastian Jawinski, German Board Certified Vet Specialist in Diagnostic Imaging
info@sonopath.com