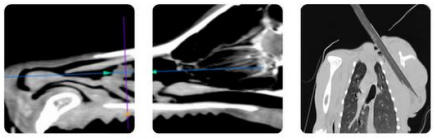

PATIENT
Zuko Leineke

SPECIES
Canine

BREED
Pit Bull Mix

SEX
MN

AGE
6Y

WEIGHT
24.3kg

INTERPRETED BY
Sebastian Jawinski, German Board Certified Vet Specialist in Diagnostic Imaging

IMAGING PERFORMED BY
Dr. Laura Baumert

HOSPITAL NAME
Wilson Veterinary Hospital

REFERRING VET
Outside clinic

INVOICE
72747

DATE
11-25-25

PRESENTING CLINICAL SIGNS

Pet presented to primary care DVM for PU/PD, polyphagia and weight loss. Was diagnosed as hyperthyroid with a cystic L thyroid mass noted on ultrasound. A CT was advised to plan surgical removal
Abnormal PE/Chem/CBC/UA Results: Increased t4

COMPUTED TOMOGRAPHY OF THE NECK

Pre/post contrast studies are provided for review.

COMPUTED TOMOGRAPHIC FINDINGS

The left thyroid gland shows a mass of 3.6 x 2.3 x 2.2 cm being well marginated and encapsulated. There is central fluid filling noted with capsular enhancement. The peripheral structures, especially the interfascial fat tissue, the common carotid artery and the tracheal wall as well as the esophagus are inconspicuous. Invasion is not noted. The cranial pole of the mass presents mild hypertrophic vessels, which are still clearly defined. The mass leads to a mild deviation of the laryngeal structures and the trachea. The right thyroid gland is inconspicuous.

The soft tissues of the head and neck are inconspicuous, especially the retropharyngeal lymph node on the left side. The bony structures of the hyoid apparatus and the laryngeal structures are within normal limits.

COMPUTED TOMOGRAPHIC DIAGNOSIS

- Thyroid mass left side without signs of an aggressive or invasive biological behavior

INTERPRETATION OF THE FINDINGS & FURTHER RECOMMENDATIONS

The changes of the left thyroid gland are unspecific from a CT perspective. As far as can be assessed, the margins to the peripheral structures are well defined without signs of an aggressive or invasive behavior. Differentials include a thyroidal cyst, cystic adenoma and adenocarcinoma. CT cannot differentiate adenoma from an initial malignant carcinoma in the absence of invasive signs. As far as can be assessed, surgery likely is curative. Signs of regional metastases are not noted.

SonoPath
FOSTERING THE ART OF VETERINARY MEDICINE™

SonoPath.com info@sonopath.com 1.800.838.4268

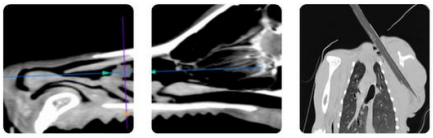

Teleradiology
Educational Teleconsultation Services™

PATIENT

Zuko Leineke

SPECIES

Canine

BREED

Pit Bull Mix

SEX

MN

AGE

6Y

WEIGHT

24.3kg

INTERPRETED BY

Sebastian Jawinski, German Board Certified Vet Specialist in Diagnostic Imaging

IMAGING PERFORMED BY

Dr. Laura Baumert

HOSPITAL NAME

Wilson Veterinary Hospital

REFERRING VET

Outside clinic

INVOICE

72747

DATE

11-25-25

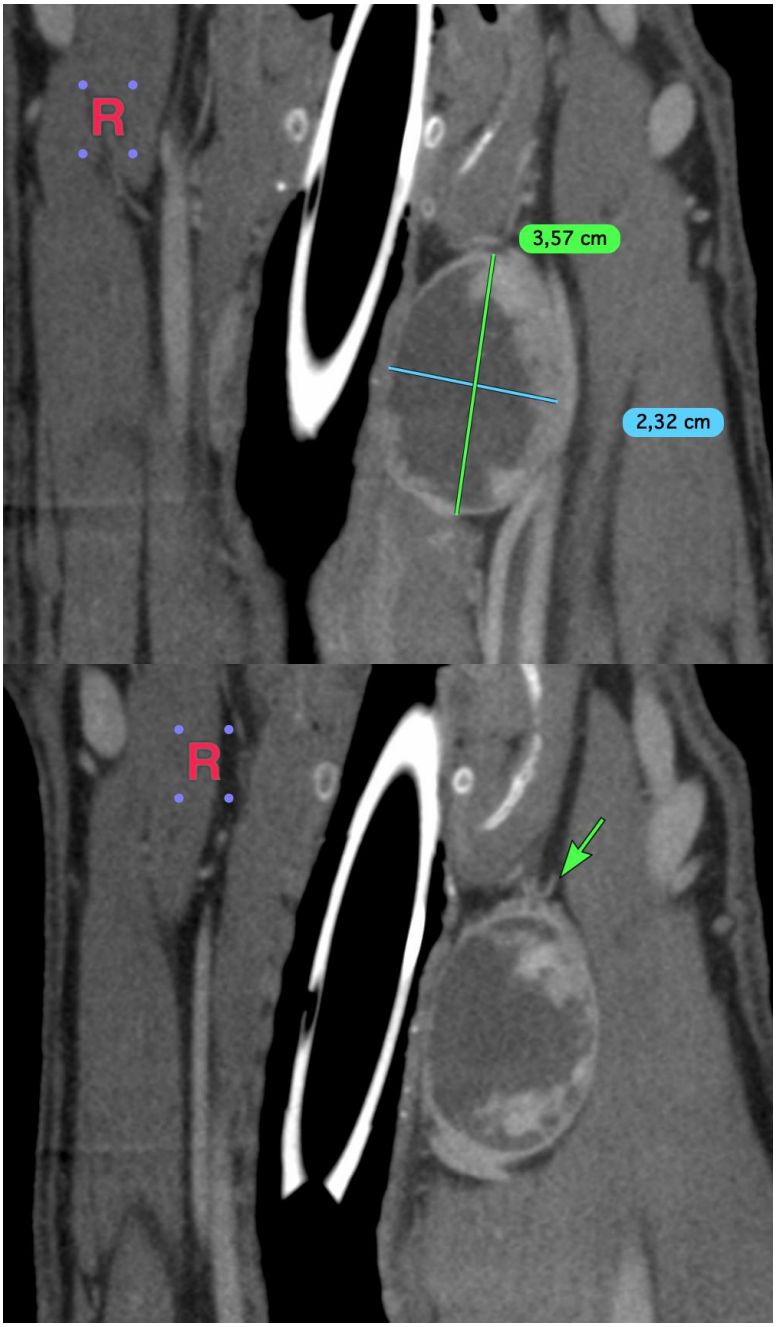

SonoPath
FOSTERING THE ART OF VETERINARY MEDICINE™

SonoPath.com info@sonopath.com 1.800.838.4268

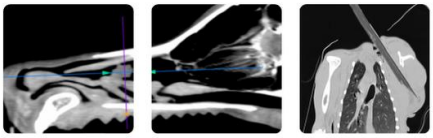

Teleradiology
Educational Teleconsultation Services™

PATIENT

Zuko Leineke

SPECIES

Canine

BREED

Pit Bull Mix

SEX

MN

AGE

6Y

WEIGHT

24.3kg

INTERPRETED BY

Sebastian Jawinski, German Board Certified Vet Specialist in Diagnostic Imaging

IMAGING PERFORMED BY

Dr. Laura Baumert

HOSPITAL NAME

Wilson Veterinary Hospital

REFERRING VET

Outside clinic

INVOICE

72747

DATE

11-25-25

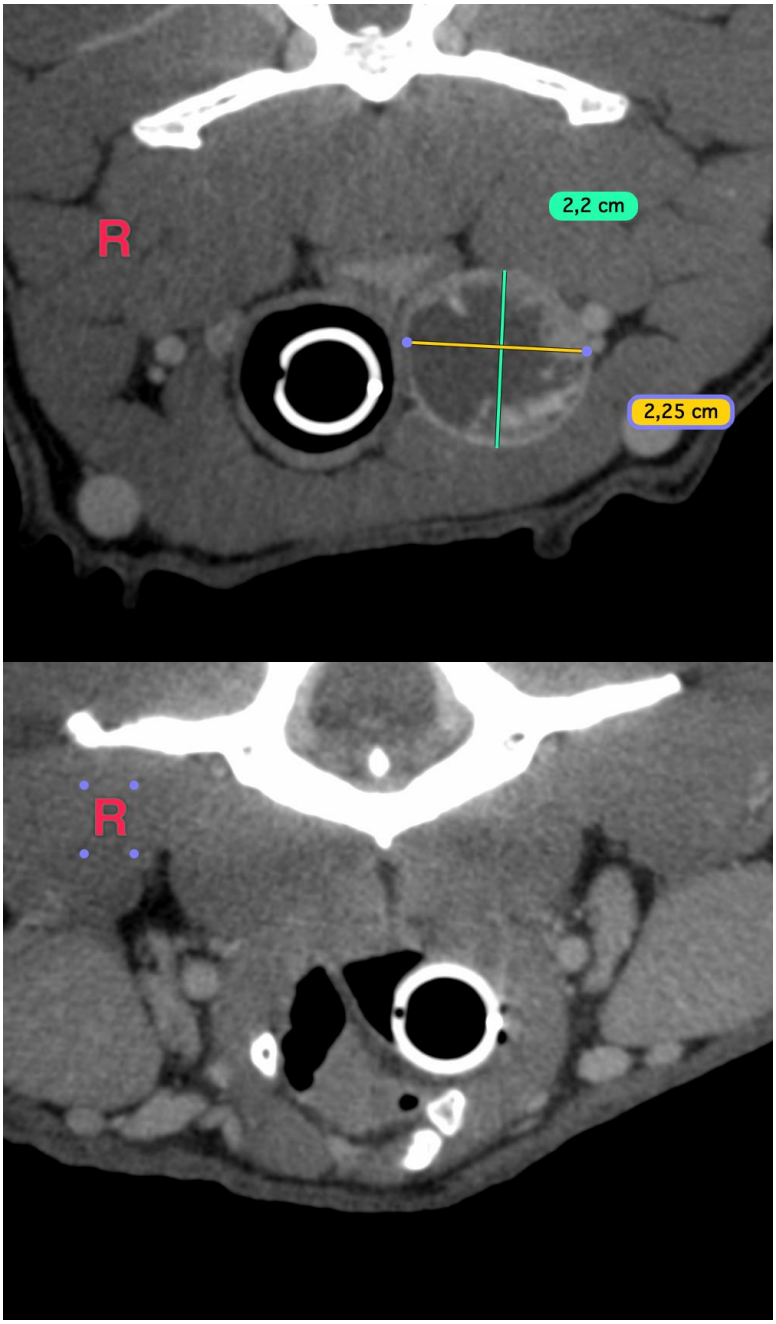

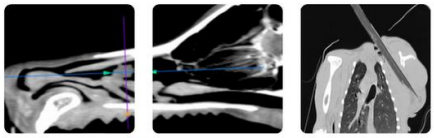

Teleradiology
Educational Teleconsultation Services™

PATIENT

Zuko Leineke

SPECIES

Canine

BREED

Pit Bull Mix

SEX

MN

AGE

6Y

WEIGHT

24.3kg

INTERPRETED BY

Sebastian Jawinski, German Board Certified Vet Specialist in Diagnostic Imaging

IMAGING PERFORMED BY

Dr. Laura Baumert

HOSPITAL NAME

Wilson Veterinary Hospital

REFERRING VET

Outside clinic

INVOICE

72747

DATE

11-25-25

The information and recommendations provided are based on the images presented by the referring veterinarian/sonographer. No evaluation can be communicated regarding pathology that was not visible in the image/video clips provided.

Thank you for this referral. If the clinical or image interpretation does not parallel your findings or if I can be of any further assistance, please contact me.

Sebastian Jawinski, German Board Certified Vet Specialist in Diagnostic Imaging
info@sonopath.com