



PATIENT

Wrangler Cook

SPECIES

Canine

BREED

Golden Retriever

SEX

M

AGE

3Y

WEIGHT

64lbs

INTERPRETED BY

Sebastian Jawinski,
German Board
Certified Vet Specialist
in Diagnostic Imaging

IMAGING PERFORMED BY

Dr. Amanda Causey

HOSPITAL NAME

Fort Lauderdale
Veterinary Center

REFERRING VET

Dr. Gonzalez

INVOICE

72752

DATE

11-25-25

PRESENTING CLINICAL SIGNS

Newly diagnosed idiopathic epileptic. Client wants to rule out possibilities for cause.

COMPUTED TOMOGRAPHY OF THE THORAX & ABDOMEN

Pre/post contrast studies are provided for review.

COMPUTED TOMOGRAPHIC FINDINGS

Chest:

The lungs are regularly ventilated with close contact to the inner thoracic wall on all sides. There is no evidence of pleural thickening, fluid accumulation or free pleural gas. The pulmonary density is within normal limits; there is no evidence of focal or nodular pulmonary lesions.

The mediastinum is regular in width and density. The mediastinal (sternal, tracheal-, bronchial) lymph nodes are considered to be normal. The thoracic trachea and esophagus present as expected.

The heart is inconspicuous as far as can be assessed with CT.

The diaphragm appears normal.

The extra-thoracic soft tissues, the spine as well as the ribs and sternum are unremarkable. There is no evidence of an aggressive bone lesion and/or abnormal sclerosis.

Abdomen:

Liver and spleen appear regular in terms of size, surface, shape and contrast behavior. Relevant focal or nodular lesions are not noted. The gallbladder is inconspicuous without evidence of cholestasis. The common bile duct is considered to be normal. The pancreas presents normal size and shape with a smooth surface. The peripancreatic fat tissue and omentum are inconspicuous.

Both kidneys and adrenal glands are in normal limits.

As far as can be assessed, the stomach and all parts of the intestine are inconspicuous without any indication of wall thickening or a mass. There are no signs of an obstructive or functional ileus.

Both ureters, the urinary bladder, trigone and urethra are presented as expected. There is no evidence of cystic calculi.

Prostate/Uterus and ovaries are inconspicuous.

The abdominal lymph nodes and vessels show no particular findings. Signs of peritoneal/retroperitoneal effusion or free gas are not recognized.

COMPUTED TOMOGRAPHIC DIAGNOSIS

- Normal findings of the thorax and the abdomen



PATIENT

Wrangler Cook

SPECIES

Canine

BREED

Golden Retriever

SEX

M

AGE

3Y

WEIGHT

64lbs

INTERPRETED BY

Sebastian Jawinski,
German Board
Certified Vet Specialist
in Diagnostic Imaging

IMAGING PERFORMED BY

Dr. Amanda Causey

HOSPITAL NAME

Fort Lauderdale
Veterinary Center

REFERRING VET

Dr. Gonzalez

INVOICE

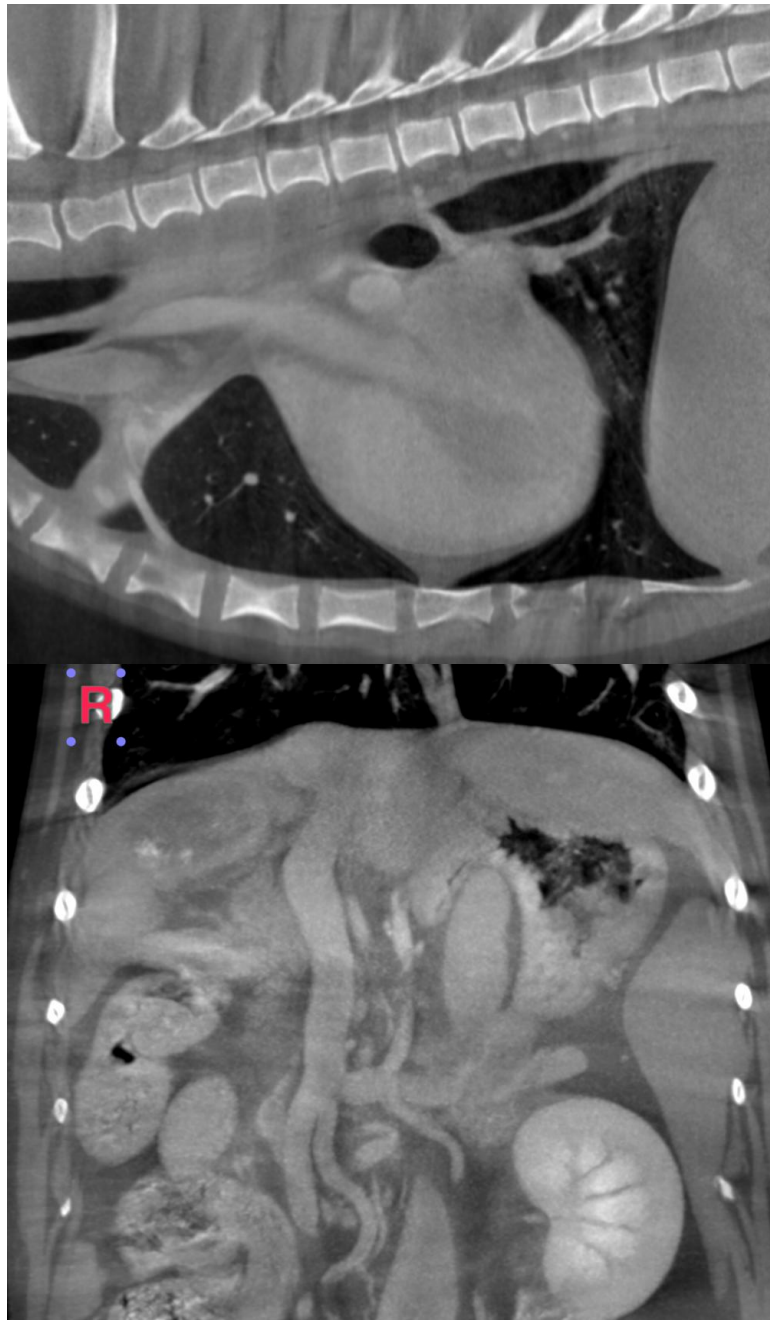
72752

DATE

11-25-25

INTERPRETATION OF THE FINDINGS & FURTHER RECOMMENDATIONS

The CT does not show signs of a congenital issue as seen with PSS. Furthermore, signs of relevant degenerative changes, an inflammatory/reactive or even neoplastic lesion are not noted.





PATIENT

Wrangler Cook

SPECIES

Canine

BREED

Golden Retriever

SEX

M

AGE

3Y

WEIGHT

64lbs

INTERPRETED BY

Sebastian Jawinski,
German Board
Certified Vet Specialist
in Diagnostic Imaging

IMAGING PERFORMED BY

Dr. Amanda Causey

HOSPITAL NAME

Fort Lauderdale
Veterinary Center

REFERRING VET

Dr. Gonzalez

INVOICE

72752

DATE

11-25-25

The information and recommendations provided are based on the images presented by the referring veterinarian/sonographer. No evaluation can be communicated regarding pathology that was not visible in the image/video clips provided.

Thank you for this referral. If the clinical or image interpretation does not parallel your findings or if I can be of any further assistance, please contact me.

Sebastian Jawinski, German Board Certified Vet Specialist in Diagnostic Imaging
info@sonopath.com