



PATIENT

Bruce Owen

SPECIES

Feline

BREED

British Shorthair

SEX

Male

AGE

13 Years

WEIGHT

5.2 kg

INTERPRETED BY

Sebastian Jawinski,
German Board
Certified Vet Specialist
in Diagnostic Imaging

IMAGING PERFORMED BY

Olivia Jarvis

HOSPITAL NAME

Animal Trust Ellesmere
Port

REFERRING VET

Dr. Amber Mahon

INVOICE

35528

DATE

11/14/25

PRESENTING CLINICAL SIGNS

History: Chronic nasal discharge from left nostril, was previously bilateral, hyperthyroid.

COMPUTED TOMOGRAPHIC STUDY OF THE HEAD & NECK

Both nasal cavities present severe atrophy and destruction of the conches, more prominent on the left side than on the right side, with fluid accumulations on the left side. The left frontal sinus is regularly ventilated. The right frontal sinus is completely filled with fluid dense material. There is a mixed pattern of osteolytic and osteoproliferative changes noted at the level of the nasal bones, including the roots of the canine and molar teeth on both sides. The 104 shows osteolysis and resorption of the root with a heterogeneous texture of the alveolar bone, which can be traced far caudally up to the level of the maxillary bone. Changes are similar on the left side but less obvious. An oro-nasal fistula is not noted. The nasal exits and the nasopharyngeal meatus are regularly ventilated. Both tympanic bullae indicate a small amount of fluid/soft tissue dense material aligning with the bulla wall but are predominantly aerated. The tympanic membranes are seemingly intact with ventilated external ear canals.

The cervical lymph nodes are moderately enlarged including the mandibular and medial retropharyngeal lymph nodes. The neurocranium is unremarkable.

Both thyroid glands are moderately enlarged presenting nodular changes with maximum diameters of 1.6 x 0.9 cm on the right side and 1.6 x 0.6 cm on the left side. Both thyroids show an irregular outline. Erosion of the tracheal wall and/or the peripheral structures, especially the adjacent vessels, is not recognized.

COMPUTED TOMOGRAPHIC DIAGNOSIS

- Severe and chronic osteomyelitis nasal and maxillary bones with severe resorptive lesions residual teeth
- Bilateral, chronic-erosive rhinitis and sinusitis
- Moderate cervical lymph adenomegaly
- Bilateral nodular changes thyroids

INTERPRETATION OF THE FINDINGS & FURTHER RECOMMENDATIONS

The changes of the nasal cavities are unspecific but show chronic and erosive inflammatory lesions. The teeth present severe grades of degenerative/inflammatory and resorptive changes. The findings of the nasal cavities, the bony structures and teeth may represent one disease with signs of chronic osteomyelitis due to ongoing/chronic (secondary) bacterial infections. I do not suspect neoplasia. The enlargement of the cervical lymph nodes would match with these assumptions.

Both thyroid glands are at least enlarged and show an irregular outline with nodular changes. Adenomatous hyperplasia and benign adenoma are common differentials. Currently, malignant adenocarcinoma is not suspected.



PATIENT

Bruce Owen

SPECIES

Feline

BREED

British Shorthair

SEX

Male

AGE

13 Years

WEIGHT

5.2 kg

INTERPRETED BY

Sebastian Jawinski,
German Board
Certified Vet Specialist
in Diagnostic Imaging

**IMAGING
PERFORMED BY**

Olivia Jarvis

HOSPITAL NAME

Animal Trust Ellesmere
Port

REFERRING VET

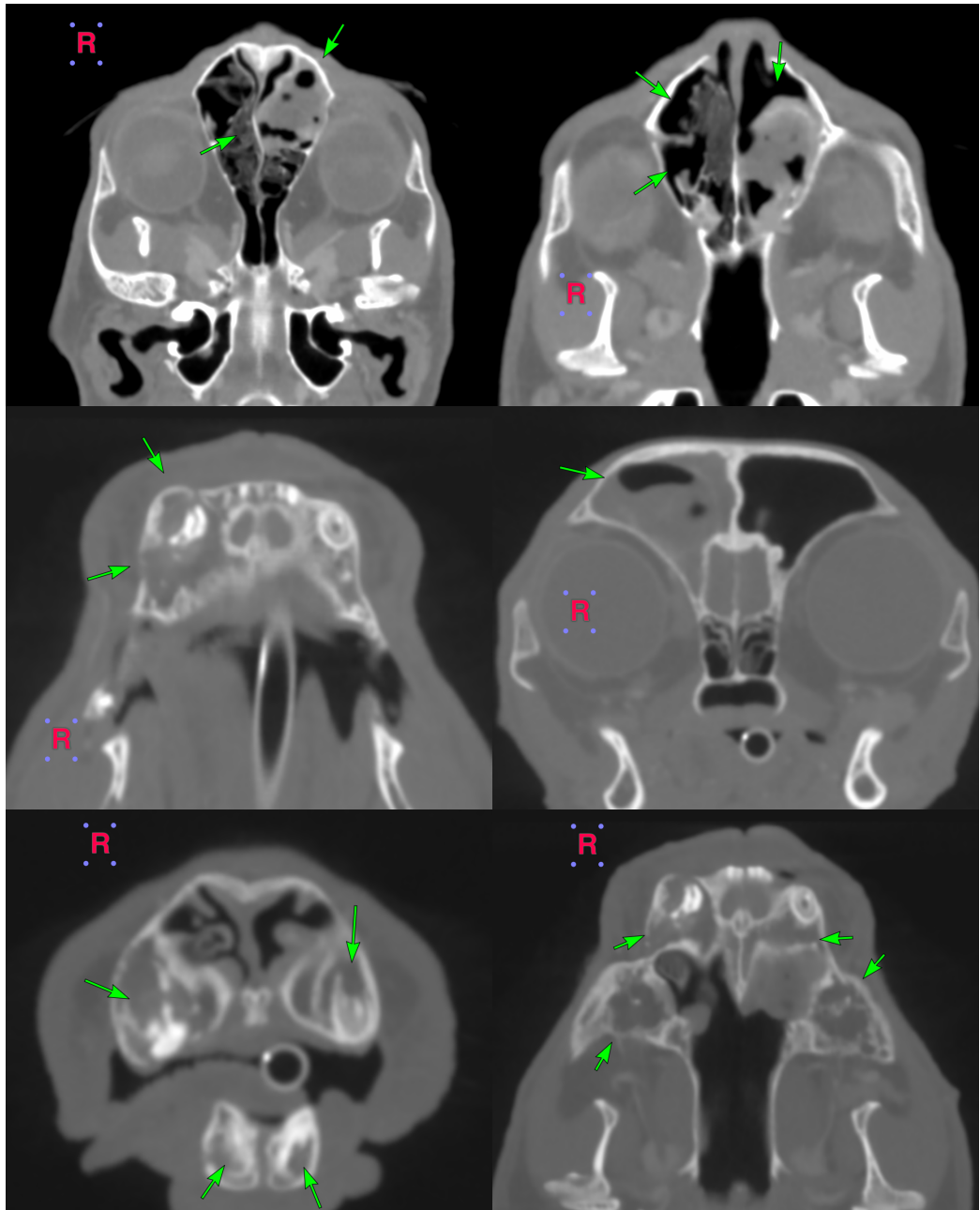
Dr. Amber Mahon

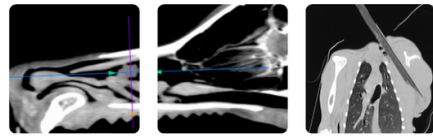
INVOICE

35528

DATE

11/14/25





PATIENT

Bruce Owen

SPECIES

Feline

BREED

British Shorthair

SEX

Male

AGE

13 Years

WEIGHT

5.2 kg

INTERPRETED BY

Sebastian Jawinski,
German Board
Certified Vet Specialist
in Diagnostic Imaging

IMAGING PERFORMED BY

Olivia Jarvis

HOSPITAL NAME

Animal Trust Ellesmere
Port

REFERRING VET

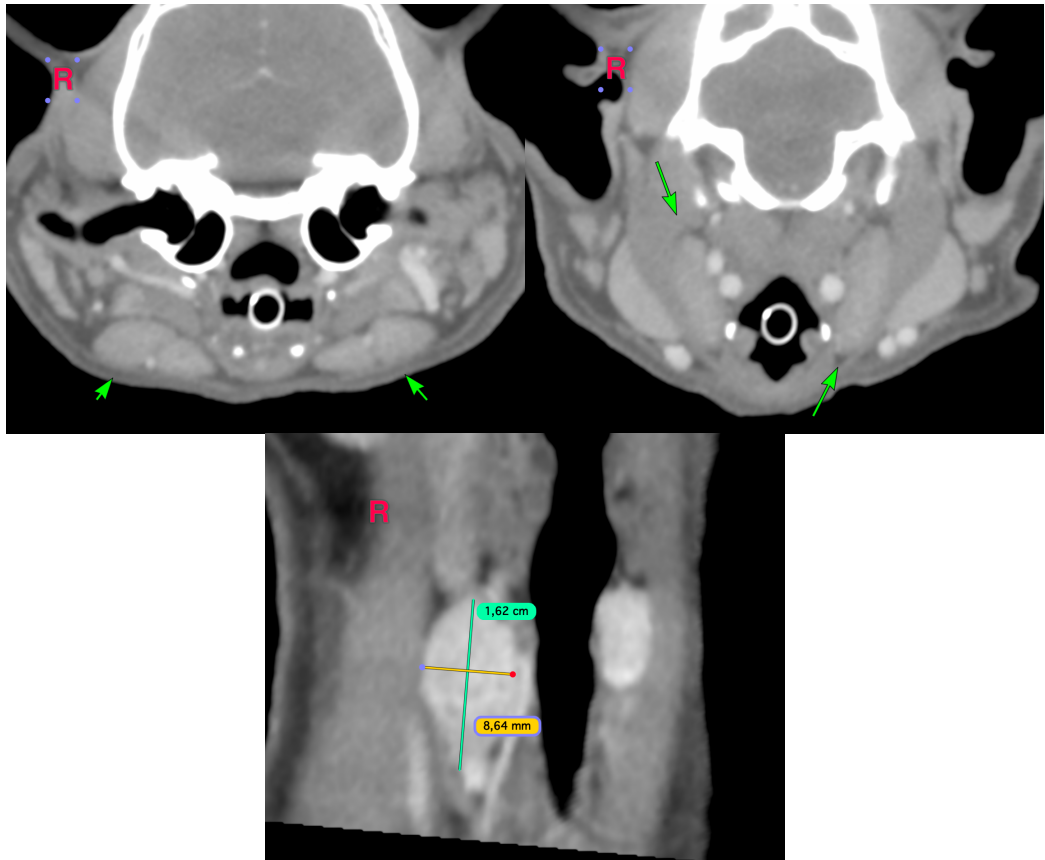
Dr. Amber Mahon

INVOICE

35528

DATE

11/14/25



The information and recommendations provided are based on the images presented by the referring veterinarian/sonographer. No evaluation can be communicated regarding pathology that was not visible in the image/video clips provided.

Thank you for this referral. If the clinical or image interpretation does not parallel your findings or if I can be of any further assistance, please contact me.

Sebastian Jawinski, German Board Certified Vet Specialist in Diagnostic Imaging
info@sonopath.com