



**PATIENT PRESENTING CLINICAL SIGNS**

Ben Lambeau Collins History: Suspected PLE, wanting to look at liver, rule out cancer. Moderate inflammation found during UGI scope

**SPECIES COMPUTED TOMOGRAPHIC STUDY OF THE ABDOMEN**

Canine There is moderate peritoneal effusion noted. The liver appears enlarged and lobulated with rounded margins. The right medial lobe presents an increased lobar uptake of contrast. A small amount of calcified biliary sediment is recognized without signs of cholestasis.

**BREED**

Chesapeake The spleen shows normal findings.  
Both kidneys present an irregular shape but are inconspicuous apart from that.

**SEX**

Neutered Male Adrenal glands are in normal limits.  
As far as can be assessed, the stomach and all parts of intestine are regular.

**AGE**

5 Years Ureters, urinary bladder, trigonum and urethra are presented as expected.

**COMPUTED TOMOGRAPHIC DIAGNOSIS**

- Moderate ascites
- Significant hepatomegaly
- Questionable mass of the right medial liver lobe
- Biliary calculi as an incidental finding
- Chronic bilateral nephropathy

**INTERPRETED BY**

Sebastian Jawinski,  
German Board  
Certified Vet Specialist  
in Diagnostic Imaging

**INTERPRETATION OF THE FINDINGS & FURTHER RECOMMENDATIONS**

**HOSPITAL NAME**

Bluegrass VS

The CT findings are highly suspicious for a neoplastic lesion of the right medial liver. Differentials are numerous and cannot be finally assessed with CT. They include nodular hyperplasia, adenoma and malignant lesions such as adenocarcinoma. Artificial circumstances are possible as well due to asymmetric perfusion in severe liver disease. Hepatomegaly in addition commonly represents diffuse/infiltrative hepatopathy as seen with lipidosis, lymphoma, mast cell or round cell tumors. Portal hypertension with secondary ascites is possible. FNA of the effusion is recommended to rule out abdominal hemorrhage.

**REFERRING VET**

Radhakrishnan

**INVOICE**

13558

**DATE**

10/5/21



**PATIENT**

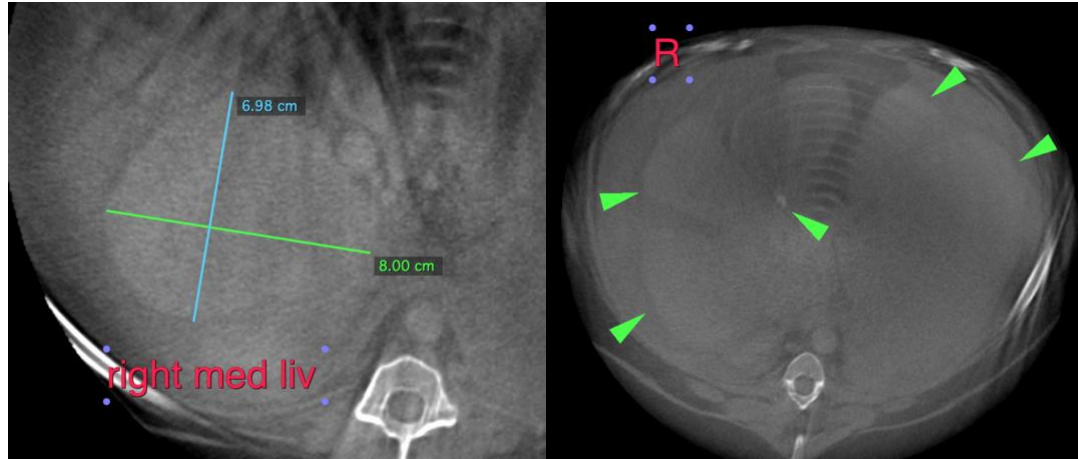
Ben Lambeau Collins

**SPECIES**

Canine

**BREED**

Chesapeake



**SEX**

Neutered Male

The information and recommendations provided are based on the images presented by the referring veterinarian. No evaluation can be communicated regarding pathology that was not visible in the image/video clips provided.

**AGE**

5 Years

Thank you for this referral. If the clinical or image interpretation does not parallel your findings or if I can be of any further assistance please contact me.

**Sebastian Jawinski**, German Board Certified Vet Specialist in Diagnostic Imaging  
info@sonopath.com

**INTERPRETED BY**

Sebastian Jawinski,  
German Board  
Certified Vet Specialist  
in Diagnostic Imaging

**HOSPITAL NAME**

Bluegrass VS

**REFERRING VET**

Radhakrishnan

**INVOICE**

13558

**DATE**

10/5/21