



PATIENT PRESENTING CLINICAL SIGNS

PATIENT Baylee Layne
HISTORY: Presented to dermatologist. Severe erythema and ulcerations throughout the left external ear canal, unable to visualize the ear drum. Discussed total ear canal ablation and bulla osteotomy (a surgical procedure) that could be considered given the severity and chronicity of infection in this ear.

SPECIES

Canine

COMPUTED TOMOGRAPHIC STUDY OF THE HEAD

The neurocranium shows normal findings.

BREED

Golden Retriever

Bony structures of skull and the skull foramina of the cranial nerves are laterally symmetrical and inconspicuous.

SEX

Spayed Female

The right tympanic bulla is completely ventilated with a regular tympanic bulla wall. Integrity of the right tympanic membrane is intact. The right external ear canal is ventilated and shows a mildly thickened wall throughout. Mild metaplastic calcification is noted.

AGE

8 Years

The left tympanic bulla shows a subtle accumulation of fluid, bulla wall is regular. The tympanic membrane seems to be respected but is bulging inwards. The horizontal aspect of the external ear canal is obliterated. The wall is significantly thickened throughout and shows marked metaplastic calcifications.

INTERPRETED BY

Sebastian Jawinski,
 German Board
 Certified Vet Specialist
 in Diagnostic Imaging

The adjacent bony structures, the temporomandibular joints and the nasopharyngeal meatus have no particular findings.

Frontal sinuses and the orbital contents are laterally symmetrical without evidence of a retrobulbar lesion. Nasal cavities are ventilated regularly.

HOSPITAL NAME

Mobile Pet Imaging
 CFL

Post contrast images show no pathological enhancement. The left medial retropharyngeal lymph node appears rounded, is moderately enlarged but presents an inconspicuous periphery.

COMPUTED TOMOGRAPHIC DIAGNOSIS

REFERRING VET

Hares

- Signs of a severe and chronic otitis externa left with subtle fluid accumulation in the tympanic bulla
- Signs of a mild and chronic otitis externa right
- Left retropharyngeal lymphadenopathy

INTERPRETATION OF THE FINDINGS & FURTHER RECOMMENDATIONS

INVOICE

13521

CT findings show severe but chronic signs of an inflammatory process on the left. Integrity of the tympanic membrane seems to be intact but reactive otitis media I assumed. Obliteration of the external ear canal could be caused by severe swelling of the canal wall which shows marked

DATE

10/4/21



PATIENT

Baylee Layne

metaplastic calcifications. Obvious evidence of a neoplastic/aggressive process are missing. The enlargement of the left retropharyngeal lymph node still is compatible with reactive lymphadenitis. FNA is needed for confirmation. TECALBO could be the next therapeutic step.

SPECIES

Canine

BREED

Golden Retriever

SEX

Spayed Female

AGE

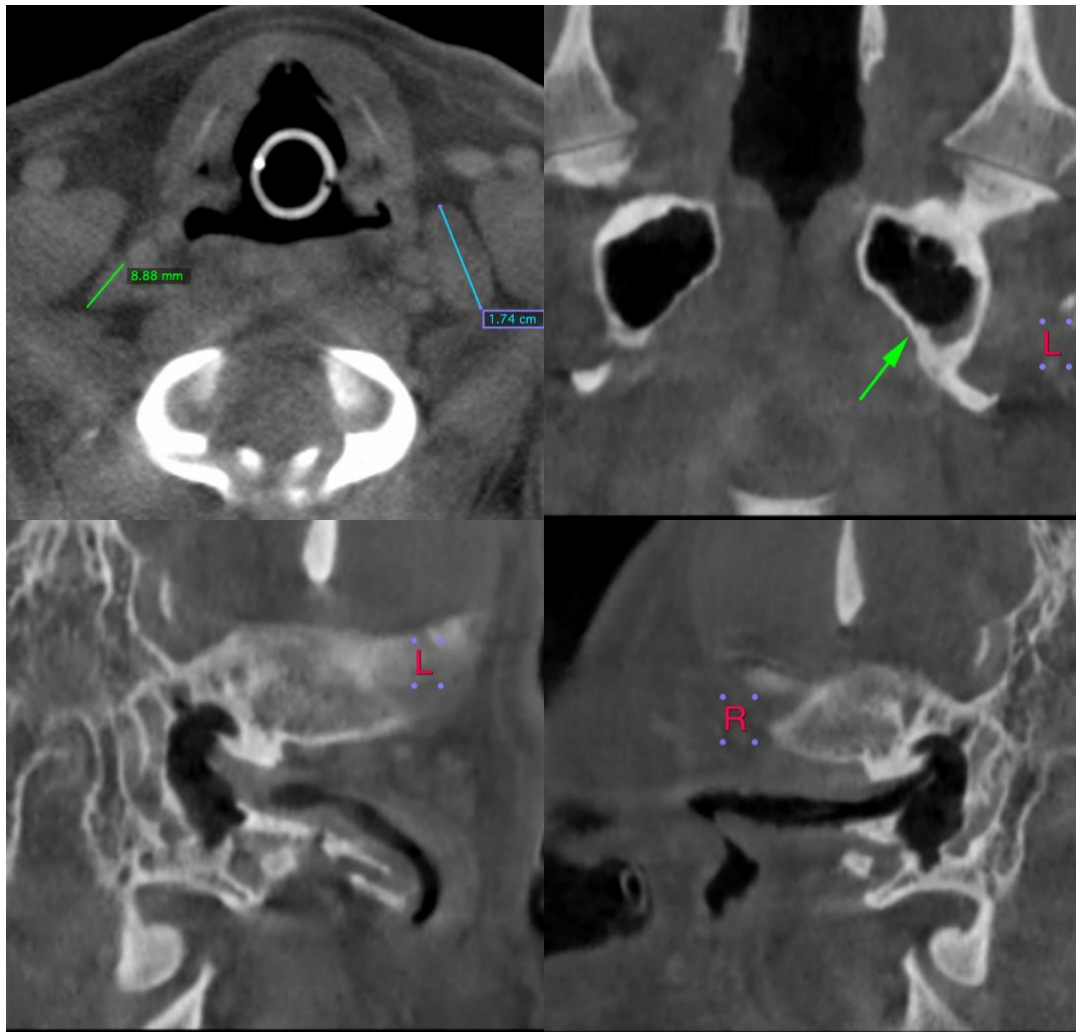
8 Years

INTERPRETED BY

Sebastian Jawinski,
German Board
Certified Vet Specialist
in Diagnostic Imaging

HOSPITAL NAME

Mobile Pet Imaging
CFL



REFERRING VET

Hares

INVOICE

13521

DATE

10/4/21



PATIENT

Baylee Layne

SPECIES

Canine

BREED

Golden Retriever

SEX

Spayed Female

AGE

8 Years

INTERPRETED BY

Sebastian Jawinski,
German Board
Certified Vet Specialist
in Diagnostic Imaging

HOSPITAL NAME

Mobile Pet Imaging
CFL

REFERRING VET

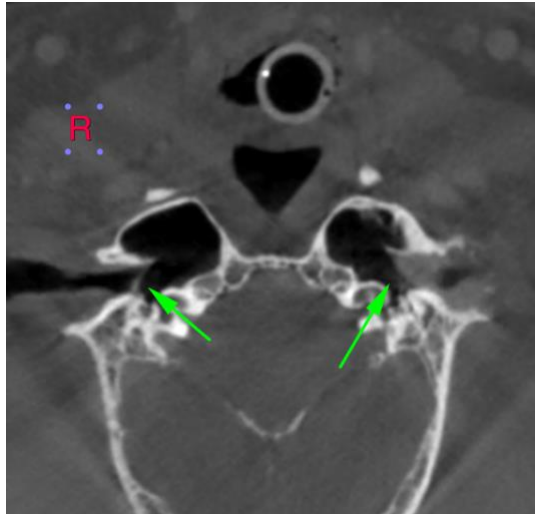
Hares

INVOICE

13521

DATE

10/4/21



The information and recommendations provided are based on the images presented by the referring veterinarian. No evaluation can be communicated regarding pathology that was not visible in the image/video clips provided.

Thank you for this referral. If the clinical or image interpretation does not parallel your findings or if I can be of any further assistance please contact me.

Sebastian Jawinski, German Board Certified Vet Specialist in Diagnostic Imaging
info@sonopath.com