



PATIENT

Rosco Fox

SPECIES

Canine

BREED

Pug Mix

SEX

Neutered Male

AGE

5 Years, 8 Months

INTERPRETED BY

Sebastian Jawinski,
German Board
Certified Vet
Specialist in
Diagnostic Imaging

HOSPITAL NAME

Neel Veterinary
Hospital

REFERRING VET

Dr. Deepan Kishore

INVOICE

48007

DATE

10-26-21

PRESENTING CLINICAL SIGNS

Patient presented on 10/24 for having loose stool and a distended abdomen. On 10/24 did an abdominocentesis (2550ml of light tan low protein fluid), BW (HCT 29.5, regenerative anemia, inflammatory leukogram, ALT/ALP elevated, ammonium biurate crystals+++ in urine) 10/26 Performed abdominocentesis and got 1,850 mls , prior to CT Scan. r/o: liver shunt v other liver vessel abnormalities v undiagnosed heart disease. Bile Acids were greater than 150.

Abnormal PE/Chem/CBC/UA Results: Elevated Values: Reticulocytes-123.3 K/uL, WBC-19.48 K/uL, Neutrophils-15.20 K/uL, Monocytes-2.47 K/uL, ALT-302 U/L, ALP-281 U/L
Decreased Values: Hematocrit- 29.5%, Hemoglobin-10.3 g/dL, MCV-50.3 fL, MCH-17.5 pg, Reticulocyte Hemoglobin-19.6 pg, PDW-7.5 fL, BUN-6 mg/dL, Calcium- 7.7 mg/dL, Albumin-1.9 g/dL, Cholesterol-94 mg/dL

COMPUTED TOMOGRAPHIC STUDY OF THE ABDOMEN

Pre/post contrast studies provided for review.

COMPUTED TOMOGRAPHIC FINDINGS

The liver impresses with a significantly reduced size and multiple nodular changes. Furthermore, a very prominent portal system is recognized with secondary distension of the tributary veins, including the renal and gastric/splenic veins. Multiple collaterals are noted caudal to the stomach, in the periphery of the caudal vena cava and the esophagus. Diameter of the CVC is severely enlarged in the transit through the liver and diaphragm. The gastric wall presents moderate thickening, the pancreas is severely enlarged with multiple distended vessels.

The spleen shows normal findings in terms of size, surface, shape and contrast behavior. Both kidneys appear enlarged. Adrenal glands are in normal limits.

Ureters, trigone and urethra are presented as expected. The urinary bladder shows multiple, small cystic calculi.

Signs of peritoneal/retroperitoneal effusion or free gas are not recognized.

COMPUTED TOMOGRAPHIC DIAGNOSIS

- Advanced liver disease (microhepatica/liver cirrhosis) with severe portal hypertension and formation of multiple intra- and extrahepatic collaterals.
- Secondary renomegaly, enlargement stomach and pancreas, cystic calculi.

INTERPRETATION OF THE FINDINGS & FURTHER RECOMMENDATIONS

CT findings are highly suspicious for advanced liver cirrhosis. Portal hypertension is obvious. The microhepatica and the multiple collateral vessels indicate a chronic disease. Liver changes are severe and generally of bad prognosis. Treatment of a chronic hepatitis/inflammatory



PATIENT

Rosco Fox

hepatopathy (prednisolone, antibiotics, spironolactone, hepatic diet) may improve clinical symptoms and reduce ascites. Liver neoplasia is unlikely but cannot be fully excluded.

SPECIES

Canine

BREED

Pug Mix

SEX

Neutered Male

AGE

5 Years, 8 Months

INTERPRETED BY

Sebastian Jawinski,
German Board
Certified Vet
Specialist in
Diagnostic Imaging

HOSPITAL NAME

Neel Veterinary
Hospital

REFERRING VET

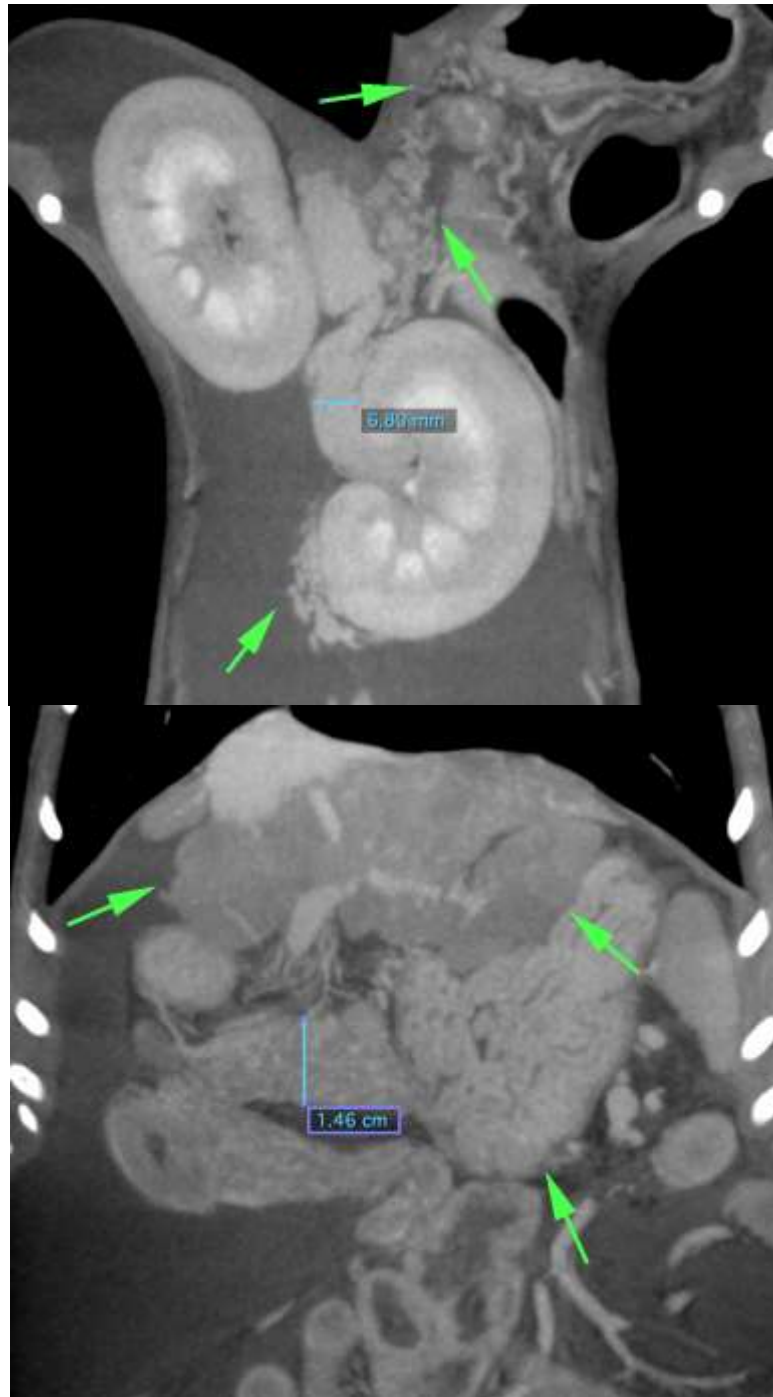
Dr. Deepan Kishore

INVOICE

48007

DATE

10-26-21





PATIENT

Rosco Fox

SPECIES

Canine

BREED

Pug Mix

SEX

Neutered Male

AGE

5 Years, 8 Months

INTERPRETED BY

Sebastian Jawinski,
German Board
Certified Vet
Specialist in
Diagnostic Imaging

HOSPITAL NAME

Neel Veterinary
Hospital

REFERRING VET

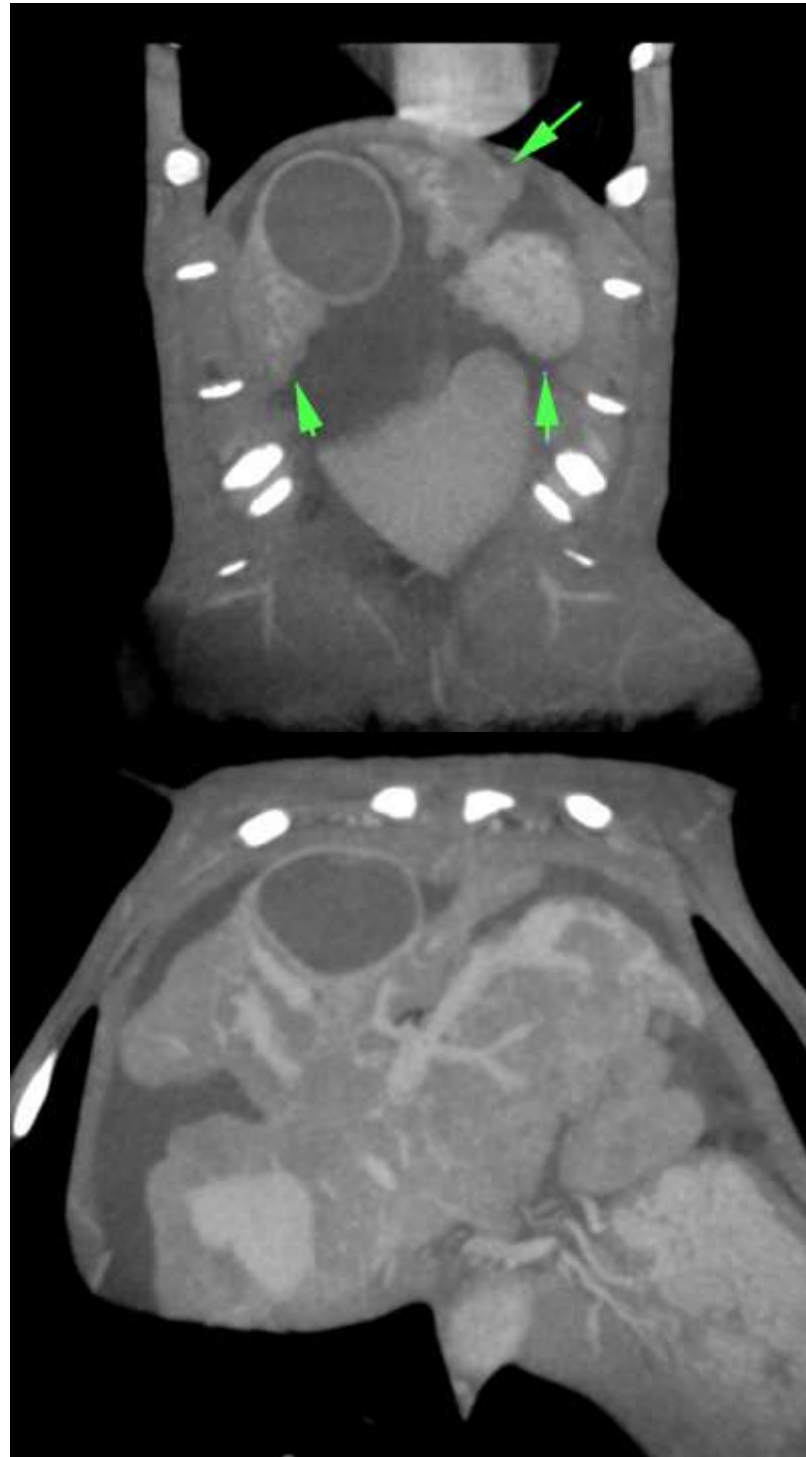
Dr. Deepan Kishore

INVOICE

48007

DATE

10-26-21





PATIENT

Rosco Fox

The information and recommendations provided are based on the images presented by the referring veterinarian. No evaluation can be communicated regarding pathology that was not visible in the image/video clips provided.

SPECIES

Canine

Thank you for this referral. If the clinical or image interpretation does not parallel your findings or if I can be of any further assistance, please contact me.

Sebastian Jawinski, German Board Certified Vet Specialist in Diagnostic Imaging
Sebastian.Jawinski@sonopath.com

BREED

Pug Mix

SEX

Neutered Male

AGE

5 Years, 8 Months

INTERPRETED BY

Sebastian Jawinski,
German Board
Certified Vet
Specialist in
Diagnostic Imaging

HOSPITAL NAME

Neel Veterinary
Hospital

REFERRING VET

Dr. Deepan Kishore

INVOICE

48007

DATE

10-26-21