



PATIENT PRESENTING CLINICAL SIGNS

Keys Carey History: severe reverse sneezing

COMPUTED TOMOGRAPHIC STUDY OF THE HEAD

SPECIES

Canine

The neurocranium shows normal findings. Bony structures of skull and the skull foramina of the cranial nerves are laterally symmetrical and inconspicuous. Both tympanic bullae are completely ventilated with a regular tympanic bulla wall. External ear canals are ventilated in all sections, walls of the external ear canals, the adjacent temporomandibular joints and the nasopharyngeal meatus have no particular findings.

BREED

Mixed

Frontal sinuses and the orbital contents are laterally symmetrical without evidence of a retrobulbar lesion. Nasal cavities are ventilated regularly.

SEX

Spayed Female

Post contrast images show no pathological enhancement. The soft palate appears elongated and reaches the level of the rostral larynx. Larynx is inconspicuous. Soft tissues of the head and neck are symmetrical and of homogeneous density, especially the medial retropharyngeal lymph nodes.

AGE

5 Years

Chest

The lungs are regularly ventilated with close contact to the inner thoracic wall on all sides. No evidence of pleural thickening, fluid accumulation or free pleural gas is noticed.

INTERPRETED BY

Sebastian Jawinski,
German Board
Certified Vet Specialist
in Diagnostic Imaging

Pulmonary density is within normal limits, there is no evidence of focal or nodular pulmonary lesions.

Mediastinum is regular in width and density. Mediastinal (sternal, tracheal-, bronchial) lymph nodes are considered to be normal. The trachea presents a mildly alternating diameter in its cervical and thoracic course but is regularly ventilated. The esophagus presents as expected.

HOSPITAL NAME

AMC of Mt. Pleasant

COMPUTED TOMOGRAPHIC DIAGNOSIS

- Mild elongation of the soft palate
- Mild alternating diameter of the trachea

REFERRING VET

Dr. Steven Epstein

INTERPRETATION OF THE FINDINGS & FURTHER RECOMMENDATIONS

CT findings show no signs of a neoplastic or a relevant inflammatory process. Both diagnoses are of questionable clinical relevance but may cause dynamic narrowing of the upper airways.

INVOICE

13883

DATE

10/19/21



PATIENT

Keys Carey

SPECIES

Canine

BREED

Mixed

SEX

Spayed Female

AGE

5 Years

INTERPRETED BY

Sebastian Jawinski,
German Board
Certified Vet Specialist
in Diagnostic Imaging

HOSPITAL NAME

AMC of Mt. Pleasant

REFERRING VET

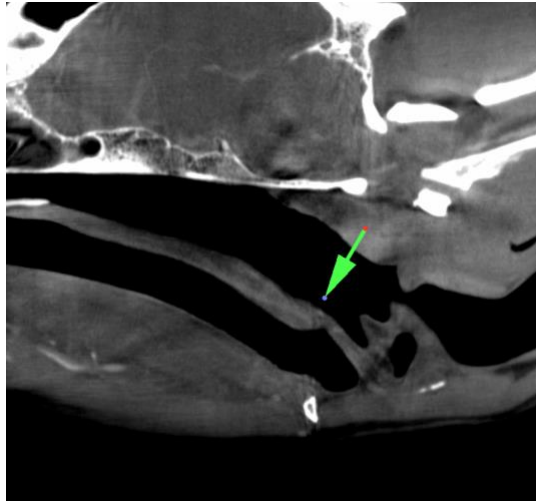
Dr. Steven Epstein

INVOICE

13883

DATE

10/19/21



The information and recommendations provided are based on the images presented by the referring veterinarian. No evaluation can be communicated regarding pathology that was not visible in the image/video clips provided.

Thank you for this referral. If the clinical or image interpretation does not parallel your findings or if I can be of any further assistance please contact me.

Sebastian Jawinski, German Board Certified Vet Specialist in Diagnostic Imaging
info@sonopath.com