



**PATIENT PRESENTING CLINICAL SIGNS**

**Celeste Ru4me** History: rDVM notes from 6/22 Ceruminous discharge present in both ear canals, left worse than right. Discharge left canal moister but no free standing fluid in canal. Able to visualize horizontal canal opening both sides but unable to see tympanum on either side. Opening of horizontal canal on left subjectively more narrow than right but no proliferative mass visible

**SPECIES**

**Feline** Abnormal PE/Chem/CBC/UA Results: Possible polyp Right ear canal; Scab present on caudal aspect of Right pinna

**BREED COMPUTED TOMOGRAPHIC STUDY OF THE HEAD**

**DSH** The neurocranium shows normal findings.

**SEX**

**Female** There is mild hyperostosis of the left frontal sinus and the left tympanic bullae noted. Both are regularly ventilated without signs of a lytic process. The right frontal sinus and tympanic bulla are normal. Mild fluid accumulation is noted adjacent to the right tympanic membrane, integrity of the latter seems to be intact.

**AGE**

**9 Months** Bony structures of skull and the skull foramina of the cranial nerves are laterally symmetrical and inconspicuous. External ear canals are ventilated in all sections, walls of the external ear canals, the adjacent temporomandibular joints and the nasopharyngeal meatus have no particular findings.

**INTERPRETED BY**

Sebastian Jawinski,  
German Board  
Certified Vet Specialist  
in Diagnostic Imaging

The orbital contents are laterally symmetrical without evidence of a retrobulbar lesion. Nasal cavities are ventilated regularly with bilateral, prominent and even swelling of the mucous membranes. Conches look normal. The maxillary/mandibular teeth show no particular findings.

Post contrast images show no pathological enhancement. Soft tissues of the head and neck are symmetrical and of homogeneous density, especially the medial retropharyngeal lymph nodes which appear mildly enlarged. Structures of the larynx and cranial neck are inconspicuous.

**HOSPITAL NAME**

Mobile Pet Imaging

**COMPUTED TOMOGRAPHIC DIAGNOSIS**

- Bilateral and unspecific swelling of the nasal mucous membranes
- Mild enlargement of the medial retropharyngeal lymph nodes
- Mild fluid-accumulation horizontal part of the right external canal
- Mild hyperostosis of the left frontal sinus and bulla wall

**REFERRING VET**

Meaux

**INTERPRETATION OF THE FINDINGS & FURTHER RECOMMENDATIONS**

**INVOICE**

13876

Orbital contents and both eyes are symmetrical without signs of an active process. The fluid accumulation adjacent to the right tympanic membrane is an indirect sign for otitis externa which is unspecific from a CT perspective as well as the mild swelling of the nasal mucous membranes.

**DATE**

10/19/21



**PATIENT**

Celeste Ru4me

Differentials include but are not limited to eosinophilic and lympho-plasmocytic rhinitis. There is no evidence of an aggressive/erosive lesion recognized. The mild swelling of the retropharyngeal lymph nodes likely represents mild reactive inflammation. The hyperostosis may show residual inflammation without signs of active/aggressive process.

**SPECIES**

Feline

**BREED**

DSH

**SEX**

Female

**AGE**

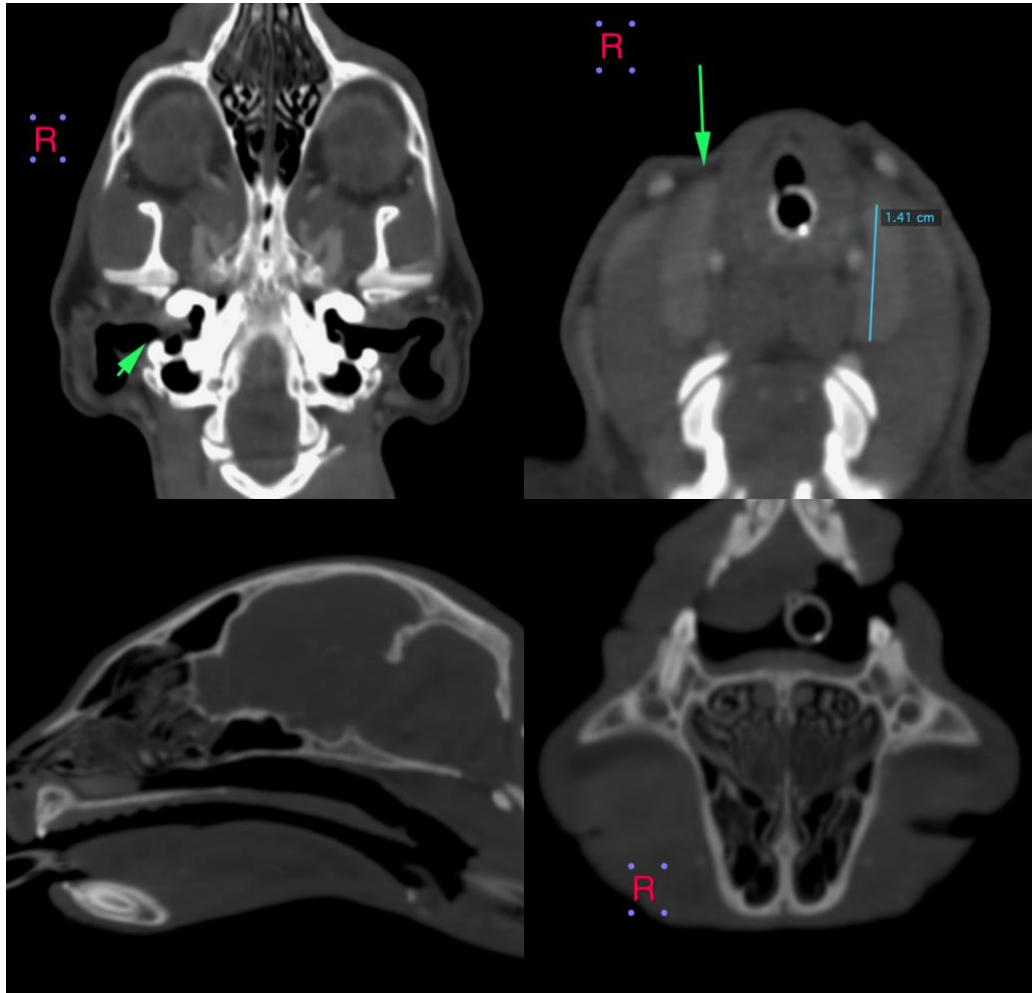
9 Months

**INTERPRETED BY**

Sebastian Jawinski,  
German Board  
Certified Vet Specialist  
in Diagnostic Imaging

**HOSPITAL NAME**

Mobile Pet Imaging



**REFERRING VET**

Meaux

**INVOICE**

13876

**DATE**

10/19/21



**PATIENT**

Celeste Ru4me

**SPECIES**

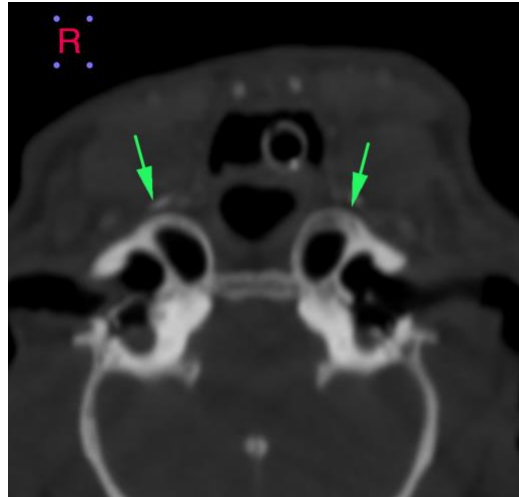
Feline

**BREED**

DSH

**SEX**

Female



**The information and recommendations provided are based on the images presented by the referring veterinarian. No evaluation can be communicated regarding pathology that was not visible in the image/video clips provided.**

**AGE**

9 Months

Thank you for this referral. If the clinical or image interpretation does not parallel your findings or if I can be of any further assistance please contact me.

**Sebastian Jawinski**, German Board Certified Vet Specialist in Diagnostic Imaging  
info@sonopath.com

**INTERPRETED BY**

Sebastian Jawinski,  
German Board  
Certified Vet Specialist  
in Diagnostic Imaging

**HOSPITAL NAME**

Mobile Pet Imaging

**REFERRING VET**

Meaux

**INVOICE**

13876

**DATE**

10/19/21