



## PATIENT

Kennedy Dunn

## SPECIES

Canine

## BREED

English Springer  
Spaniel

## SEX

Male

## AGE

6 Years 4 Months

## WEIGHT

21.2 kg

## INTERPRETED BY

Sebastian Jawinski,  
German Board  
Certified Vet Specialist  
in Diagnostic Imaging

## IMAGING PERFORMED BY

Ana

## HOSPITAL NAME

Animal Trust Bolton

## REFERRING VET

Dr. Ana Valega

## INVOICE

35354

## DATE

1/9/36

## PRESENTING CLINICAL SIGNS

History: working dog 12mo ago started to limp on LFL then resolved and was fine over the summer 3wks ago had a slight limp that progressed to non-weight bearing before Christmas been holding up/nwb since.

Abnormal PE/Chem/CBC/UA Results: WNL

## COMPUTED TOMOGRAPHIC STUDY OF THE ELBOW JOINTS

The right elbow presents an intercondylar fissure line of the distal humerus that has contact to both surfaces being mildly irregular with smooth margins. There is no relevant dislocation and/or fracture noted. The elbow joint on the right side shows mild secondary osteoarthritis. The medial coronoid process is inconspicuous. The displayed long bones adjacent to the right elbow joint are unremarkable.

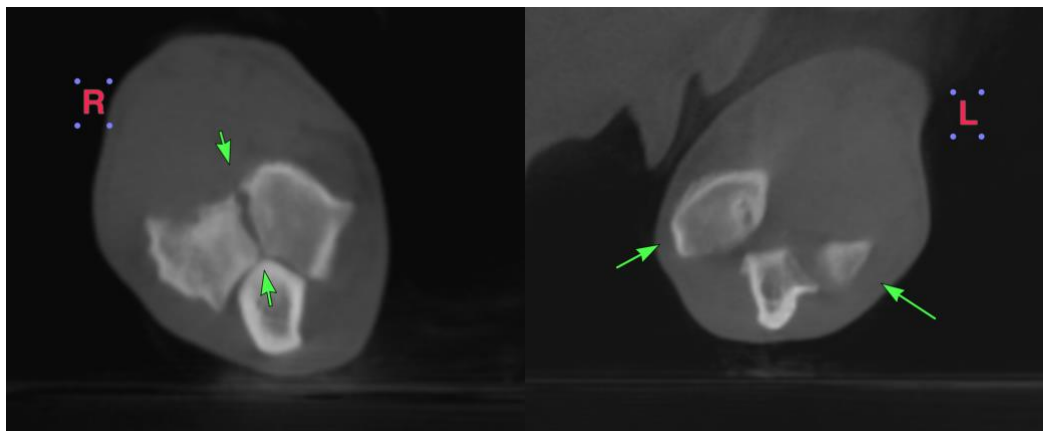
The left side presents a dislocated fracture of the lateral epicondyle with subluxation of the elbow joint and moderate osteophytic changes at the joint margins. There is marked periarticular swelling noted. The images after contrast application impress with severe joint diffusion and synovial enhancement.

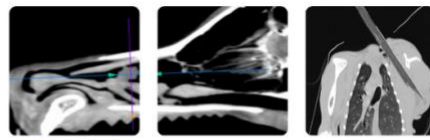
## COMPUTED TOMOGRAPHIC DIAGNOSIS

- Dislocated fracture left lateral humeral condyle
- IOHC right elbow

## INTERPRETATION OF THE FINDINGS & FURTHER RECOMMENDATIONS

The CT findings of the left elbow do match with the reported patient's history. There is a marked dislocated fracture of the lateral humeral condyle noted, likely after IOHC and trauma. Activated osteoarthritis and synovitis are recognized. The right elbow shows similar findings without a present dislocated fracture. Both sides present mild (right) and moderate (left) secondary osteoarthritis.





## PATIENT

Kennedy Dunn

## SPECIES

Canine

## BREED

English Springer  
Spaniel

## SEX

Male

## AGE

6 Years 4 Months

## WEIGHT

21.2 kg

## INTERPRETED BY

Sebastian Jawinski,  
German Board  
Certified Vet Specialist  
in Diagnostic Imaging

## IMAGING PERFORMED BY

Ana

## HOSPITAL NAME

Animal Trust Bolton

## REFERRING VET

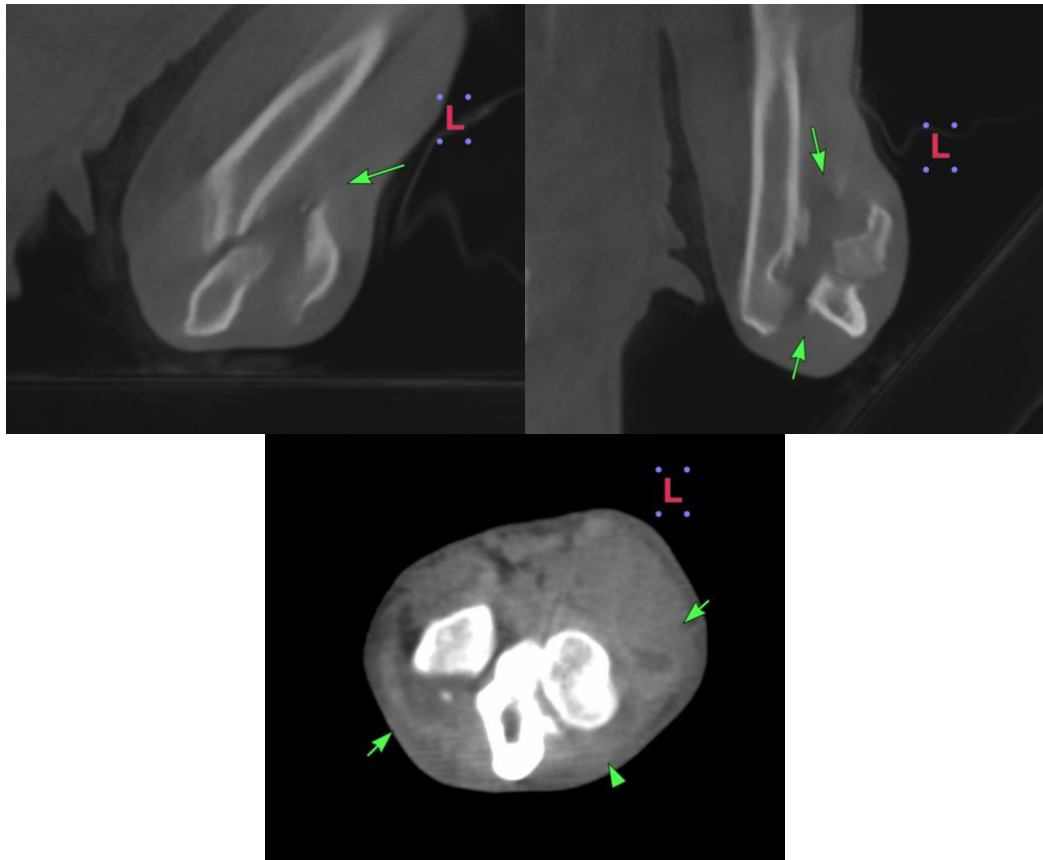
Dr. Ana Valega

## INVOICE

35354

## DATE

1/9/36



**The information and recommendations provided are based on the images presented by the referring veterinarian/sonographer. No evaluation can be communicated regarding pathology that was not visible in the image/video clips provided.**

Thank you for this referral. If the clinical or image interpretation does not parallel your findings or if I can be of any further assistance, please contact me.

**Sebastian Jawinski, German Board Certified Vet Specialist in Diagnostic Imaging**  
[info@sonopath.com](mailto:info@sonopath.com)