



PATIENT PRESENTING CLINICAL SIGNS

Shadow Schmidt History: Patient presents for a COHAT. A survey CT of the skull with emphasis on the dental arcade is submitted for review.

SPECIES COMPUTED TOMOGRAPHIC STUDY OF THE HEAD

Canine The skull bone and the bony skull foramina of cranial nerves are unremarkable. Both tympanic bullae are completely ventilated with an inconspicuous tympanic bulla wall. The external ear canals are ventilated as far as displayed in all sections, the adjacent temporomandibular joints and the nasopharyngeal meatus have no particular findings. The frontal sinuses and the orbital contents are laterally symmetrical without evidence of a retrobulbar lesion and/or an oro-nasal fistula. The nasal septum shows marked deviation to the left side which is considered to be a normal variant. Nasal cavities/conches are ventilated.

BREED

Papillon

SEX

Neutered Male

The teeth show different grades of tartar and degenerative changes with mild resorptive root changes and periapical loss of alveolar bone including 105, 106, 107, 204, 205, 206 and 207. Both rostral roots of 108 present significant periapical lysis with contact to the subcutaneous region. Relevant soft tissue swelling is not noted.

AGE

8 Years 7 Months

COMPUTED TOMOGRAPHIC DIAGNOSIS

- Root abscess/fistula 108 (rostral buccal and palatine root)
- Degenerative teeth disease with marked tartar and periapical bone loss and mild resorptive root lesions (s. above)
-

INTERPRETED BY

Sebastian Jawinski,
German Board
Certified Vet Specialist
in Diagnostic Imaging

INTERPRETATION OF THE FINDINGS & FURTHER RECOMMENDATIONS

Extraction of 108 is recommended. CT findings must be correlated with the clinical presentation but consider extraction of 105-107 and 204, 205 - 207 as well. Currently oro-nasal fistulas are not recognized. Signs of a dental rhinitis are missing.

HOSPITAL NAME

South Bay AH

REFERRING VET

Ravinder Atwal, DVM,
CCRP

INVOICE

13303

DATE

1/6/22



PATIENT

Shadow Schmidt

SPECIES

Canine

BREED

Papillon

SEX

Neutered Male

AGE

8 Years 7 Months

INTERPRETED BY

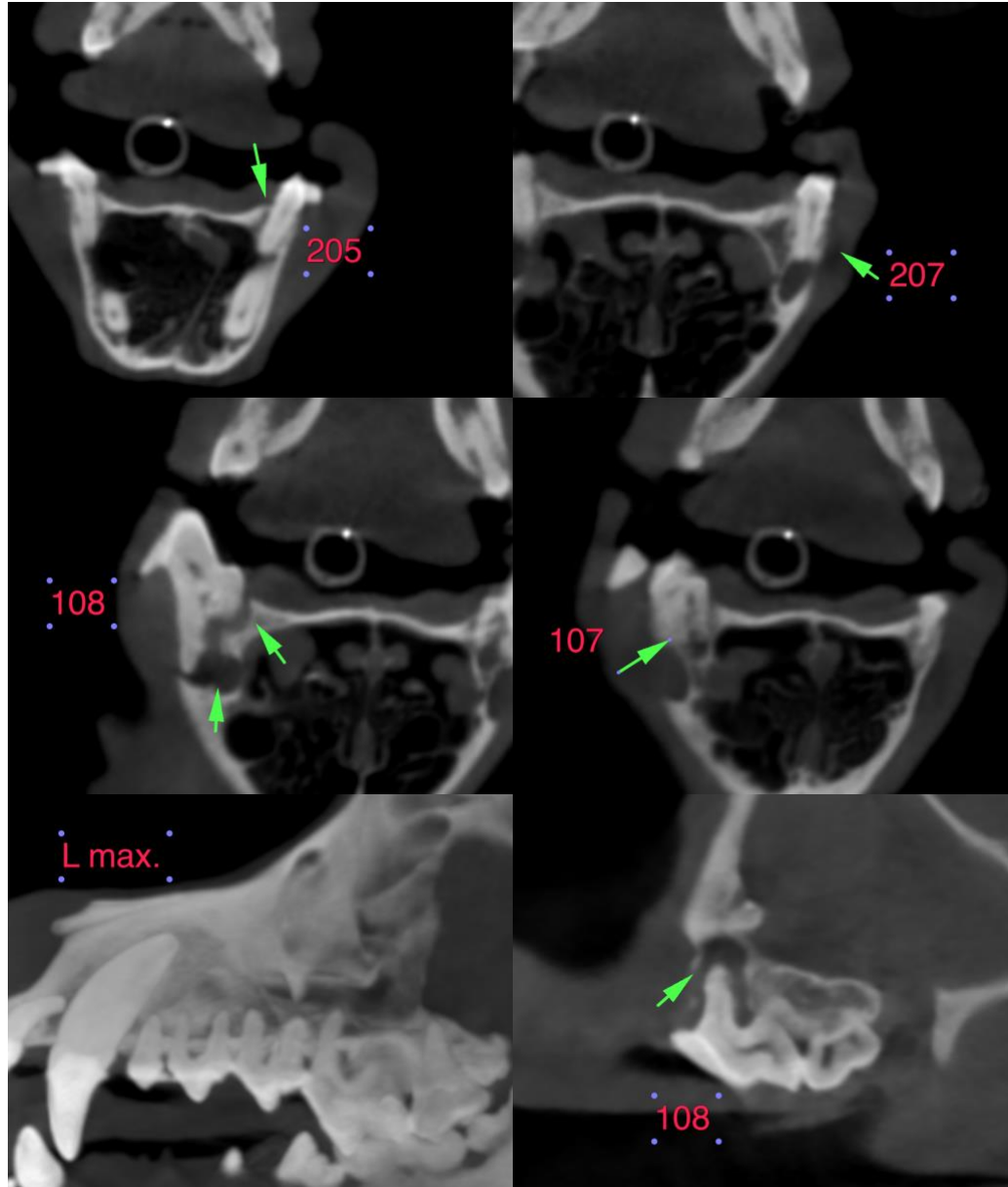
Sebastian Jawinski,
German Board
Certified Vet Specialist
in Diagnostic Imaging

HOSPITAL NAME

South Bay AH

REFERRING VET

Ravinder Atwal, DVM,
CCRP



INVOICE

13303

DATE

1/6/22



PATIENT

Shadow Schmidt

SPECIES

Canine

BREED

Papillon

SEX

Neutered Male

AGE

8 Years 7 Months

INTERPRETED BY

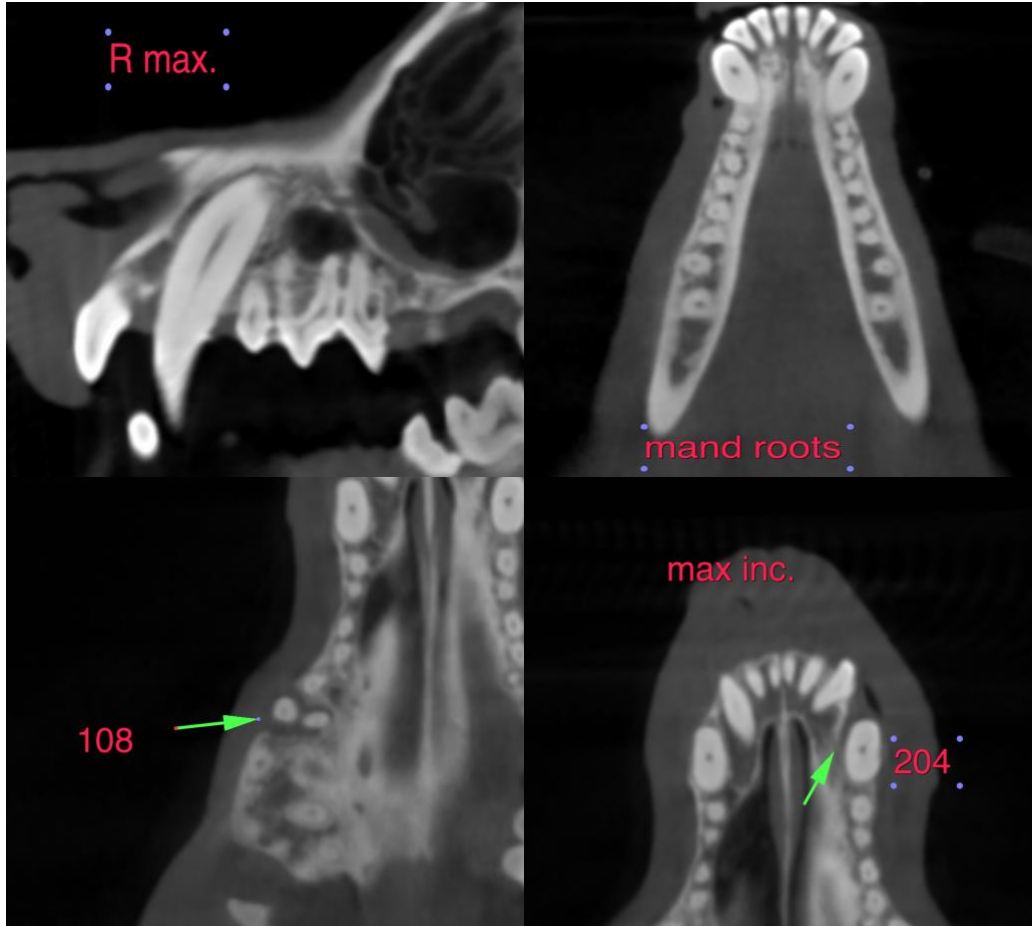
Sebastian Jawinski,
German Board
Certified Vet Specialist
in Diagnostic Imaging

HOSPITAL NAME

South Bay AH

REFERRING VET

Ravinder Atwal, DVM,
CCRP



The information and recommendations provided are based on the images presented by the referring veterinarian. No evaluation can be communicated regarding pathology that was not visible in the image/video clips provided.

Thank you for this referral. If the clinical or image interpretation does not parallel your findings or if I can be of any further assistance please contact me.

Sebastian Jawinski, German Board Certified Vet Specialist in Diagnostic Imaging
info@sonopath.com

INVOICE

13303

DATE

1/6/22