

**PATIENT**

Tommy Rodriguez

**PRESENTING CLINICAL SIGNS**

Owner reports coughing. X-ray concerning for tracheal collapse vs cranial mediastinal mass?

**SPECIES**

Canine

**COMPUTED TOMOGRAPHY OF THE THORAX**

Pre/post contrast studies provided for review.

**BREED**

Yorkie Mix

**COMPUTED TOMOGRAPHIC FINDINGS**

The lungs are regularly ventilated with close contact to the inner thoracic wall on all sides. There is no evidence of pleural thickening, fluid accumulation or free pleural gas. Pulmonary density is within normal limits, there is no evidence of focal or nodular pulmonary lesions. The mediastinum is regular in width and density. Mediastinal (sternal, tracheal-, bronchial) lymph nodes are considered to be normal.

**SEX**

Intact Male

The cervical and thoracic section of the trachea present mild flattening. The tracheal course and esophagus are as expected. The left main stem bronchus appears mildly compressed in the transit between the LA and aorta. The heart is inconspicuous as far as can be assessed with CT.

**AGE**

13 Years

The diaphragm appears normal.

**INTERPRETED BY**

Sebastian Jawinski,  
German Board  
Certified Vet  
Specialist in  
Diagnostic Imaging

The extra-thoracic soft tissues, thoracic spine as well as ribs and sternum are unremarkable. There is no evidence of bony lysis or abnormal sclerosis.

**COMPUTED TOMOGRAPHIC DIAGNOSIS**

- Indirect signs for tracheal collapse and left bronchial compression
- Normal findings of the thorax part from that

**HOSPITAL NAME**

Mobile Pet Imaging

**INTERPRETATION OF THE FINDINGS & FURTHER RECOMMENDATIONS**

The CT findings most likely present a mild grade of tracheal collapse. Presence and grade need to be confirmed with endoscopy, but this finding would match with the reported patient's history as well as the suspected compression of the left main stem bronchus.

**REFERRING VET**

Meaux

Signs of a relevant inflammatory or even neoplastic process are not recognized.

**INVOICE**

49734

**DATE**

1-21-22



**PATIENT**

Tommy Rodriguez

**SPECIES**

Canine

**BREED**

Yorkie Mix

**SEX**

Intact Male

**AGE**

13 Years

**INTERPRETED BY**

Sebastian Jawinski,  
German Board  
Certified Vet  
Specialist in  
Diagnostic Imaging

**HOSPITAL NAME**

Mobile Pet Imaging

**REFERRING VET**

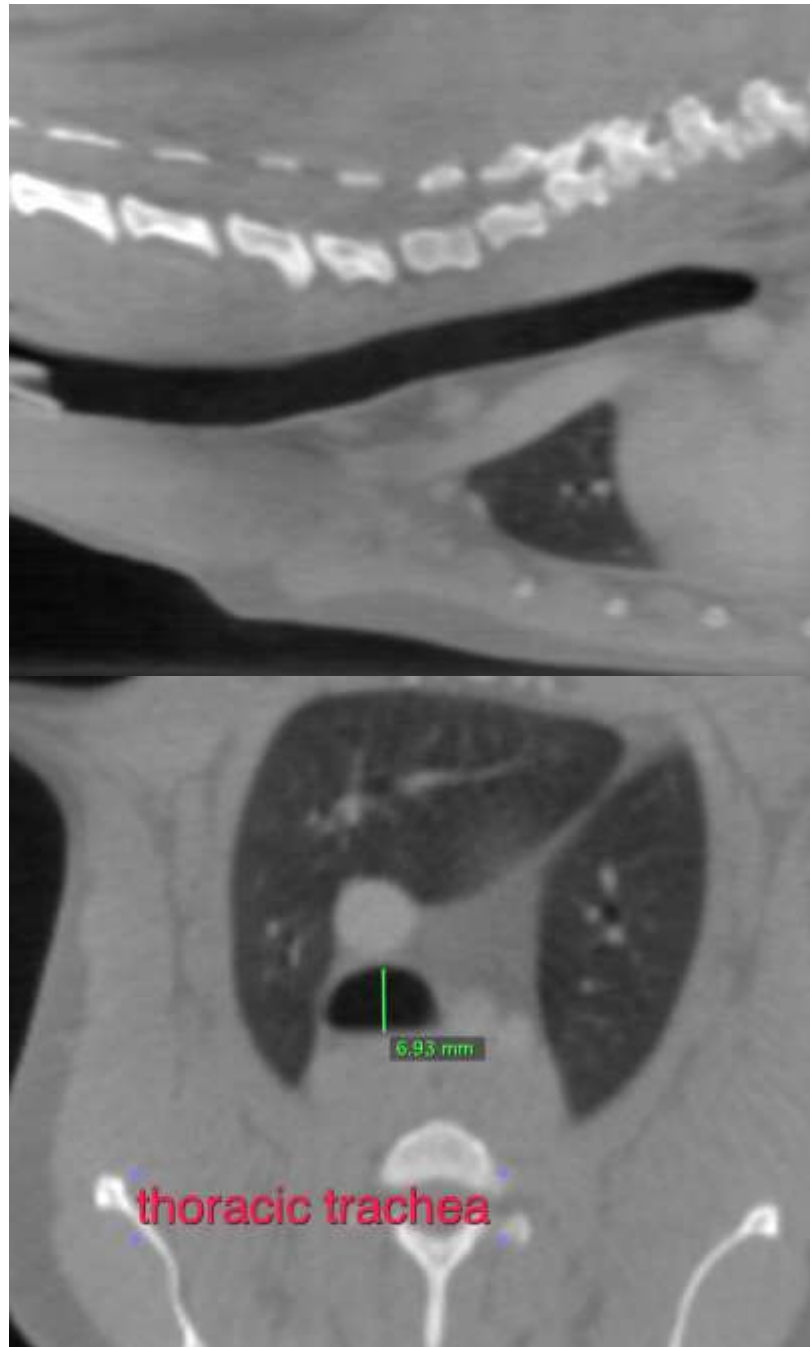
Meaux

**INVOICE**

49734

**DATE**

1-21-22





**PATIENT**

Tommy Rodriguez

**SPECIES**

Canine

**BREED**

Yorkie Mix

**SEX**

Intact Male

**AGE**

13 Years

**INTERPRETED BY**

Sebastian Jawinski,  
German Board  
Certified Vet  
Specialist in  
Diagnostic Imaging

**HOSPITAL NAME**

Mobile Pet Imaging

**REFERRING VET**

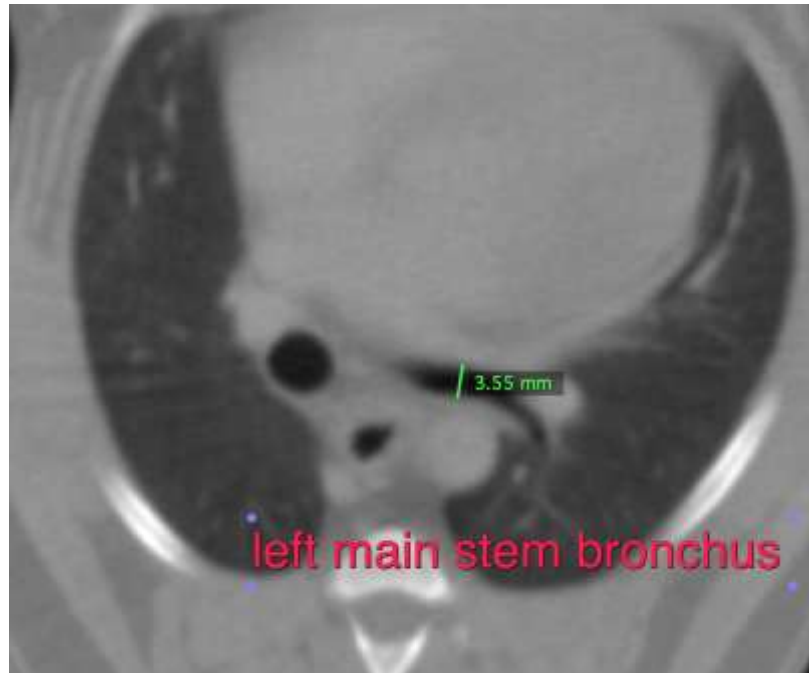
Meaux

**INVOICE**

49734

**DATE**

1-21-22



The information and recommendations provided are based on the images presented by the referring veterinarian/sonographer. No evaluation can be communicated regarding pathology that was not visible in the image/video clips provided.

Thank you for this referral. If the clinical or image interpretation does not parallel your findings or if I can be of any further assistance, please contact me.

**Sebastian Jawinski, German Board Certified Vet Specialist in Diagnostic Imaging**  
Sebastian.Jawinski@sonopath.com