



PATIENT

Hero Lima

PRESENTING CLINICAL SIGNS

Late onset seizures. Suspect intracranial disease, rule out neoplasia.
Abnormal PE/Chem/CBC/UA Results: Elevated platelets

SPECIES

Canine

COMPUTED TOMOGRAPHY OF THE HEAD

Pre/post contrast studies provided for review.

BREED

Chihuahua

COMPUTED TOMOGRAPHIC FINDINGS

There is a marked brachycephalic head formation noted with incomplete closure of the fontanelle and deformation of the caudal fossa and occipital dysplasia. Mild meningeal calcifications are recognized. The interhemispheric gap is in the midline with no evidence of a mass effect. As far as can be assessed, there are regular cortical gyri in the cerebral and cerebellar region with a symmetrical ventricular system. Brain stem and cerebellum are inconspicuous.

SEX

MN

Bony structures of the skull and the skull foramina of the cranial nerves are laterally symmetrical and inconspicuous.

AGE

14.5 Years

Both tympanic bullae are completely obliterated with soft tissue-dense material. The bulla wall appears regular, the tympanic membrane seems to be respected bilaterally with regularly ventilated external ear canals. The adjacent temporomandibular joints and the nasopharyngeal meatus have no particular findings.

INTERPRETED BY

Sebastian Jawinski,
German Board
Certified Vet
Specialist in
Diagnostic Imaging

Frontal sinuses are not noted. The orbital contents are laterally symmetrical without evidence of a retrobulbar lesion. Nasal cavities present pooling of fluid at the level the 204 root which shows marked periapical bone lysis and oro-nasal fistula formation. Mild periapical lysis is recognized at the level of 304.

HOSPITAL NAME

Bridgwater
Veterinary Hospital
and Wellness Centre

Post contrast images show no pathological enhancement. Soft tissues of the head and neck are symmetrical and of homogeneous density, especially the medial retropharyngeal lymph nodes.

COMPUTED TOMOGRAPHIC DIAGNOSIS

REFERRING VET

Dr. S. Klonisch

- Age- and breed-appropriate findings of the neurocranium/head
- Suspected oro-nasal fistula 204 with signs of a focal, dental rhinitis, mild periapical root abscess 304
- Bilateral signs of an otitis media

INVOICE

49675

INTERPRETATION OF THE FINDINGS & FURTHER RECOMMENDATIONS

CT findings show no signs of an intracranial neoplastic or inflammatory process. Intra-axial lesions such as infarcts, small edema or low-grade neoplasia are difficult to recognize in CT and therefore not ruled out completely. Dynamic stenosis due to the occipital dysplasia/cerebellar

DATE

1-19-22



PATIENT

Hero Lima

herniation with obstruction of the CSF outflow and an increased intracranial pressure are possible.

Changes of both bullae must be correlated with the clinical presentation since this finding often is incidental. Extraction of 204/304 are recommended.

SPECIES

Canine

BREED

Chihuahua

SEX

MN

AGE

14.5 Years

INTERPRETED BY

Sebastian Jawinski,
German Board
Certified Vet
Specialist in
Diagnostic Imaging

HOSPITAL NAME

Bridgwater
Veterinary Hospital
and Wellness Centre

REFERRING VET

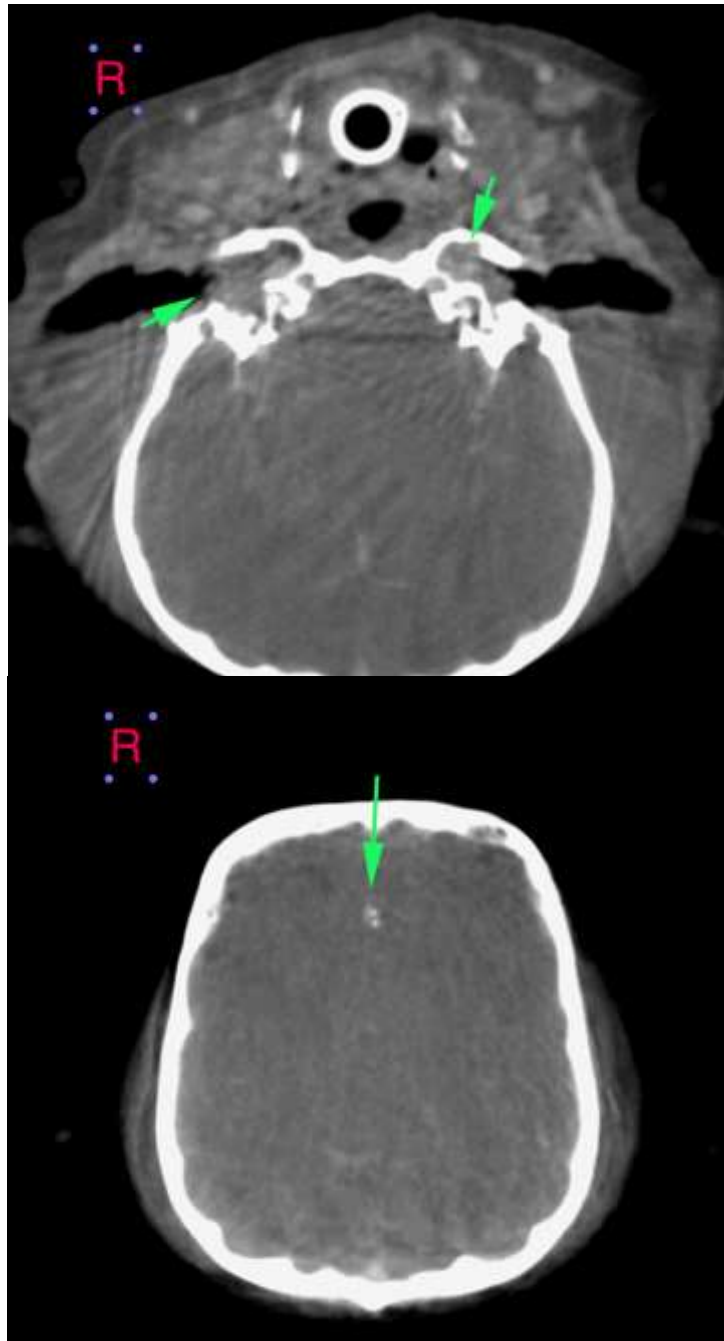
Dr. S. Klonisch

INVOICE

49675

DATE

1-19-22





PATIENT

Hero Lima

SPECIES

Canine

BREED

Chihuahua

SEX

MN

AGE

14.5 Years

INTERPRETED BY

Sebastian Jawinski,
German Board
Certified Vet
Specialist in
Diagnostic Imaging

HOSPITAL NAME

Bridgwater
Veterinary Hospital
and Wellness Centre

REFERRING VET

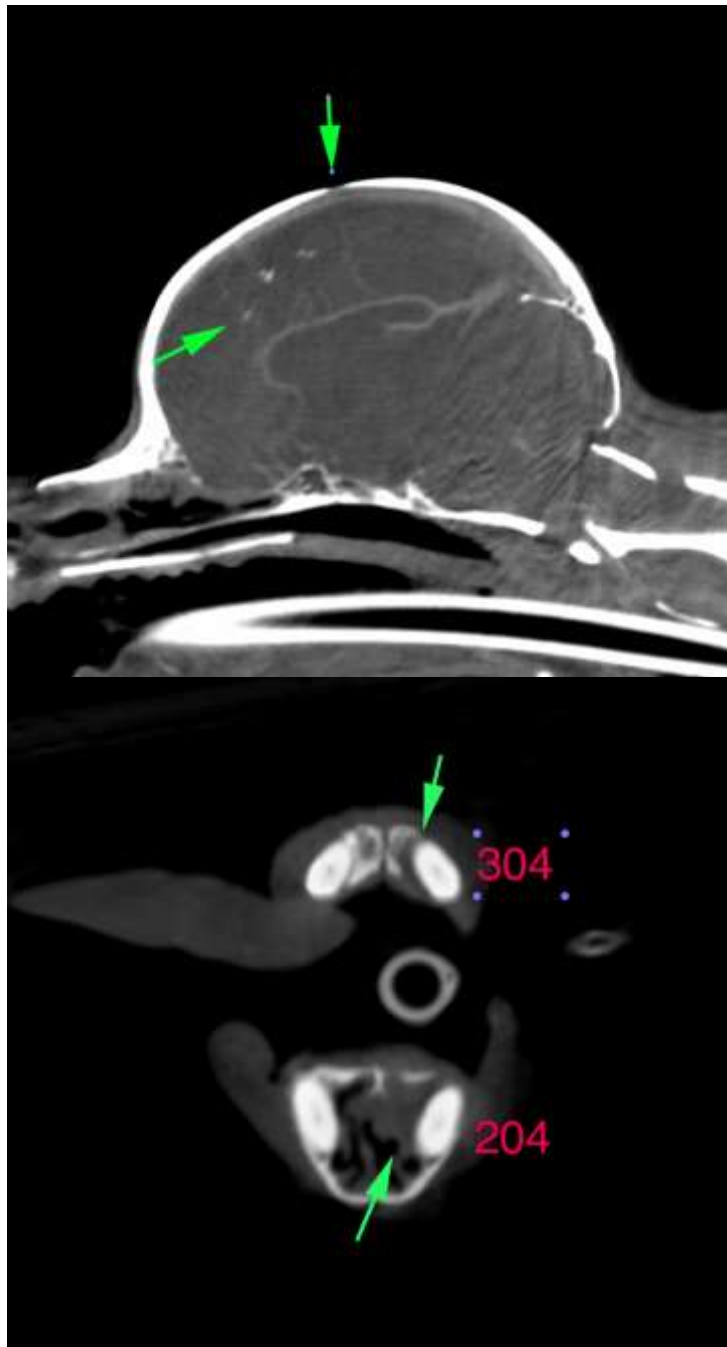
Dr. S. Klonisch

INVOICE

49675

DATE

1-19-22





PATIENT

Hero Lima

The information and recommendations provided are based on the images presented by the referring veterinarian. No evaluation can be communicated regarding pathology that was not visible in the image/video clips provided.

SPECIES

Canine

Thank you for this referral. If the clinical or image interpretation does not parallel your findings or if I can be of any further assistance, please contact me.

BREED

Chihuahua

Sebastian Jawinski, German Board Certified Vet Specialist in Diagnostic Imaging
Sebastian.Jawinski@sonopath.com

SEX

MN

AGE

14.5 Years

INTERPRETED BY

Sebastian Jawinski,
German Board
Certified Vet
Specialist in
Diagnostic Imaging

HOSPITAL NAME

Bridgwater
Veterinary Hospital
and Wellness Centre

REFERRING VET

Dr. S. Klonisch

INVOICE

49675

DATE

1-19-22