



PATIENT

Bubba Van Dok

PRESENTING CLINICAL SIGNS

Right CCL rupture originally seen last year, TTA was delayed as had suspicious area in Tibia that was biopsies. No neoplasia so TTA today.

Abnormal PE/Chem/CBC/UA Results: Positive Cranial drawer and CTT,

SPECIES

Canine

ULTRASONOGRAPHIC FINDINGS

Right Stifle

BREED

Mastiff Cross

There is mild joint effusion and moderate synovial thickening noted. The femoral trochlea shows marked subchondral irregularities with prominent formation of osteophytes at the femoral condyles.

SEX

M

The intraarticular fat body appears significantly inhomogeneous with cystic changes. The cranial cruciate ligament is not seen in continuity. There are hyper- to isoechoic residuals of the CCL noted. Continuous fibers cannot be traced.

AGE

3 Years, 2 Months

The lateral meniscus presents a mildly irregular texture. A relevant dislocation or fragmentation is not recognized.

INTERPRETED BY

Sebastian Jawinski,
German Board
Certified Vet
Specialist in
Diagnostic Imaging

The medial meniscus is prominently protruding with a markedly inhomogeneous texture. In the reviewed study of 11/15/21 a clearly defined line/fissure is recognized most likely representing partial folding of the meniscus. The current study demonstrates marked medial protruding/dislocation.

HOSPITAL NAME

Westview Veterinary
Hospital

ULTRASONOGRAPHIC DIAGNOSIS

- Complete rupture of the CCL
- Irregular texture medial meniscus with suspected dislocation/marked protrusion
- Degenerative changes of the lateral meniscus
- Moderate degenerative changes of the right stifle including osteoarthrosis/-arthritis, joint effusion and synovial thickening

REFERRING VET

Dr. Brian Barnes

INTERPRETATION OF THE FINDINGS & FURTHER RECOMMENDATIONS

The sonographic findings are pathognomonic for a complete rupture of the CCL. Significant chronic and degenerative findings of the right stifle are recognized. The medial meniscus at least shows significant degeneration, a lesion (rupture/folding) is suspected. Evidence of a progressive osteolytic lesion is not noted.

INVOICE

49670

DATE

1-19-22



PATIENT

Bubba Van Dok

SPECIES

Canine

BREED

Mastiff Cross

SEX

M

AGE

3 Years, 2 Months

INTERPRETED BY

Sebastian Jawinski,
German Board
Certified Vet
Specialist in
Diagnostic Imaging

HOSPITAL NAME

Westview Veterinary
Hospital

REFERRING VET

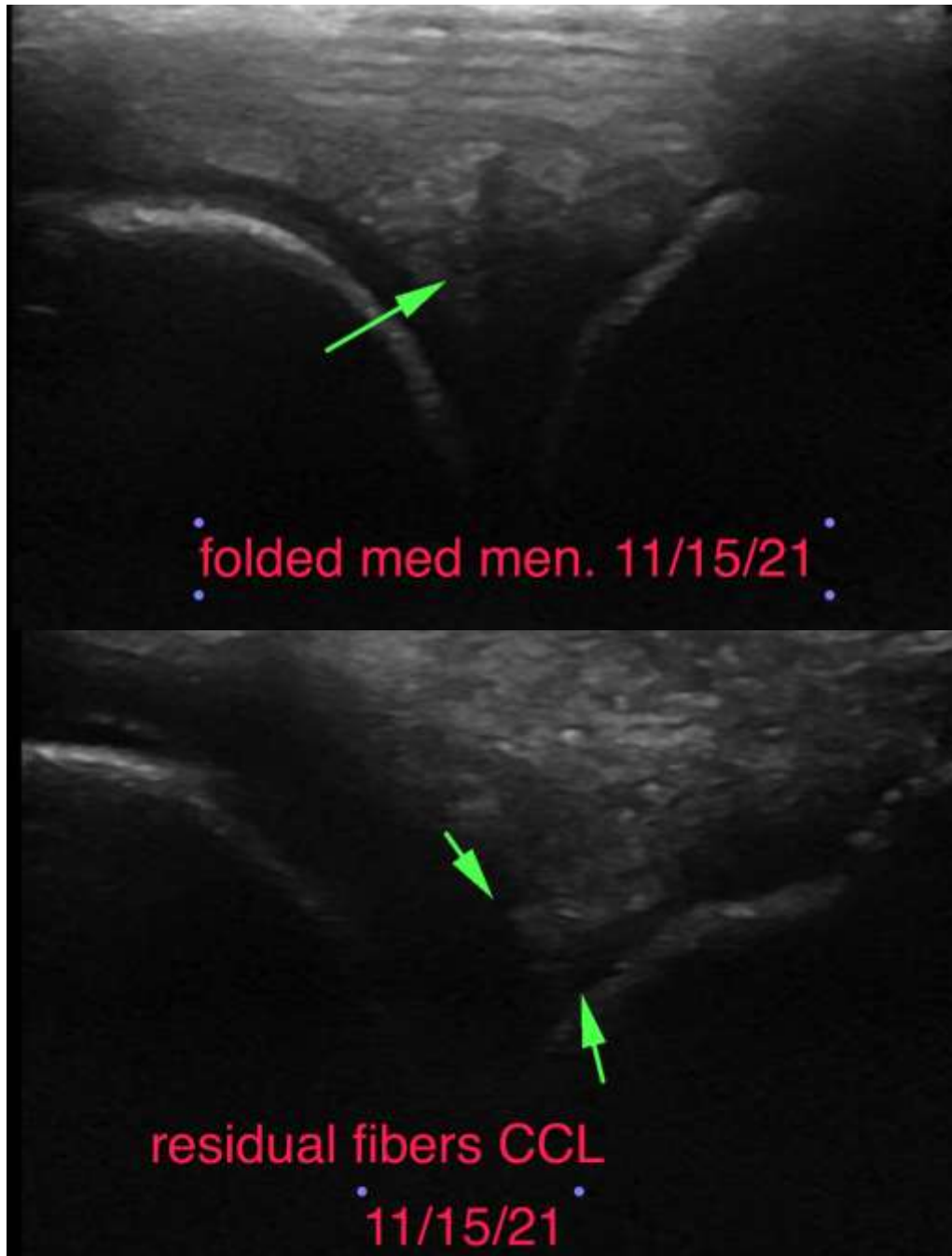
Dr. Brian Barnes

INVOICE

49670

DATE

1-19-22





PATIENT

Bubba Van Dok

SPECIES

Canine

BREED

Mastiff Cross

SEX

M

AGE

3 Years, 2 Months

INTERPRETED BY

Sebastian Jawinski,
German Board
Certified Vet
Specialist in
Diagnostic Imaging

HOSPITAL NAME

Westview Veterinary
Hospital

REFERRING VET

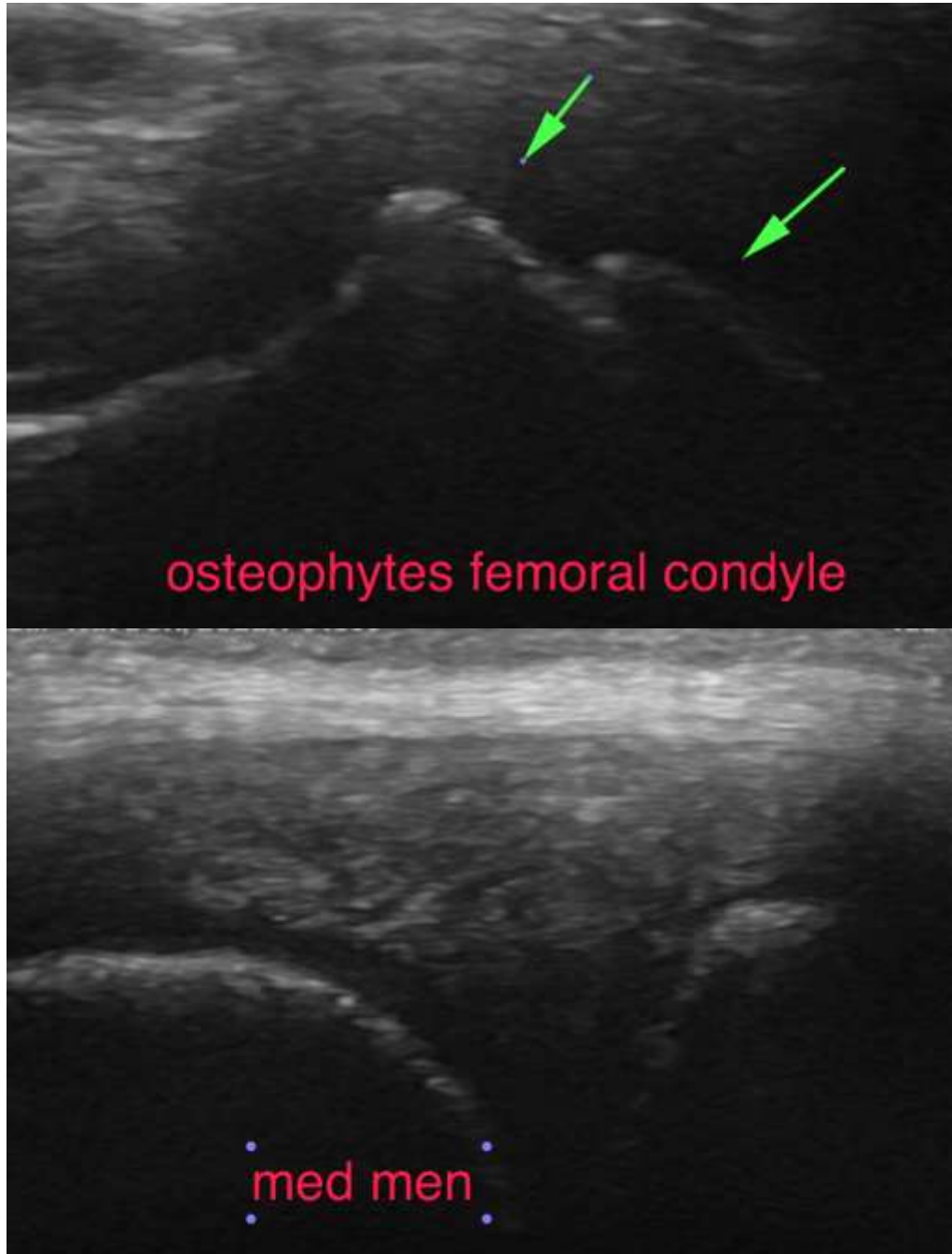
Dr. Brian Barnes

INVOICE

49670

DATE

1-19-22





PATIENT

Bubba Van Dok

SPECIES

Canine

BREED

Mastiff Cross

SEX

M

AGE

3 Years, 2 Months

INTERPRETED BY

Sebastian Jawinski,
German Board
Certified Vet
Specialist in
Diagnostic Imaging

HOSPITAL NAME

Westview Veterinary
Hospital

REFERRING VET

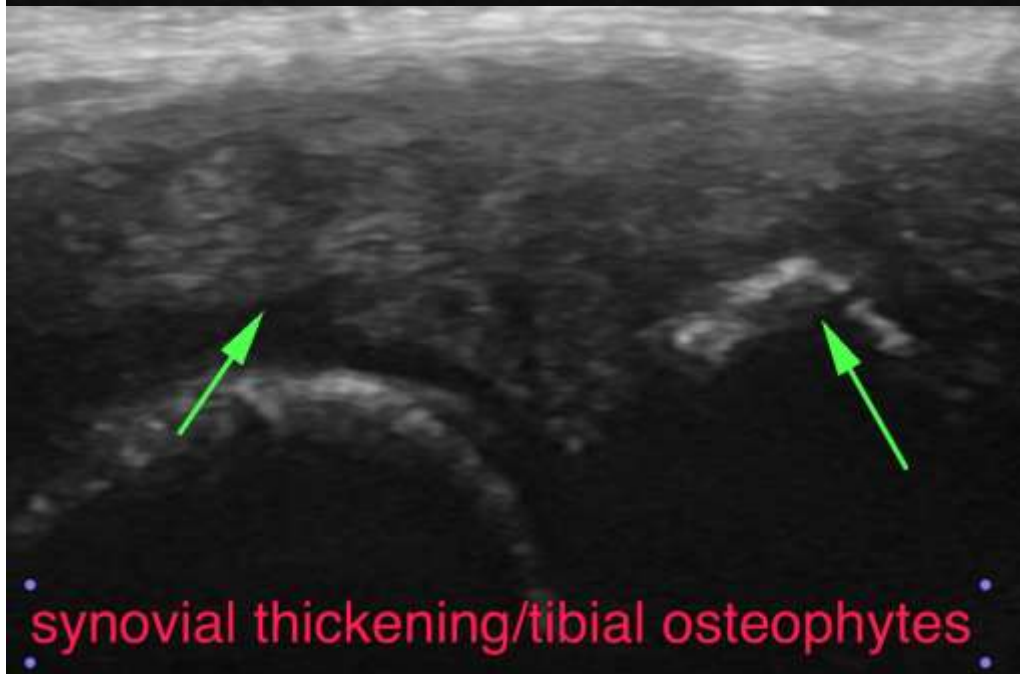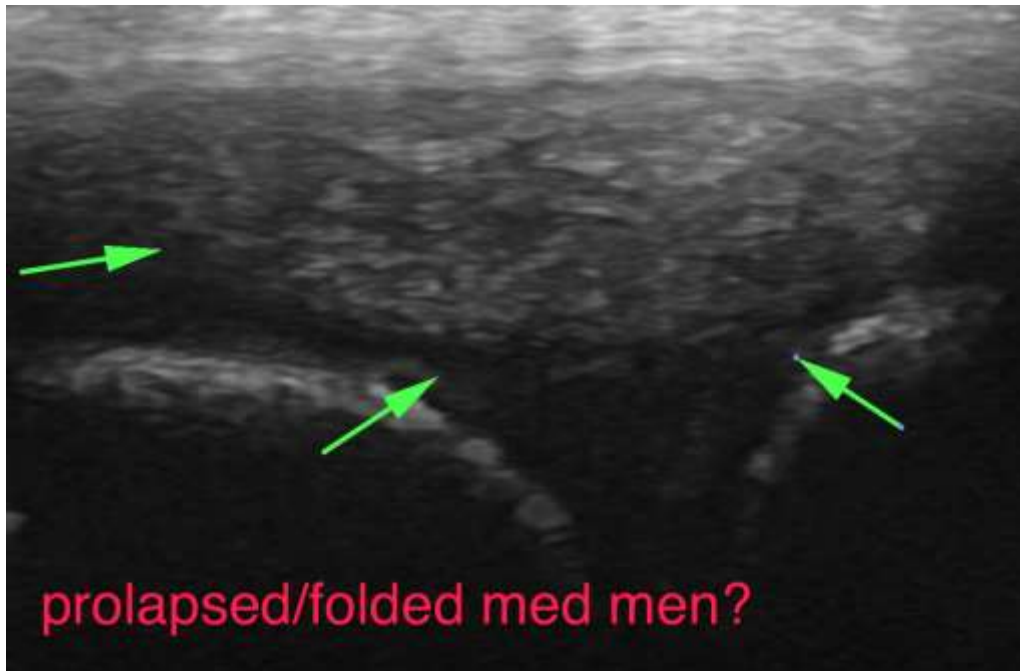
Dr. Brian Barnes

INVOICE

49670

DATE

1-19-22





PATIENT

Bubba Van Dok

SPECIES

Canine

BREED

Mastiff Cross

SEX

M

AGE

3 Years, 2 Months

INTERPRETED BY

Sebastian Jawinski,
German Board
Certified Vet
Specialist in
Diagnostic Imaging

HOSPITAL NAME

Westview Veterinary
Hospital

REFERRING VET

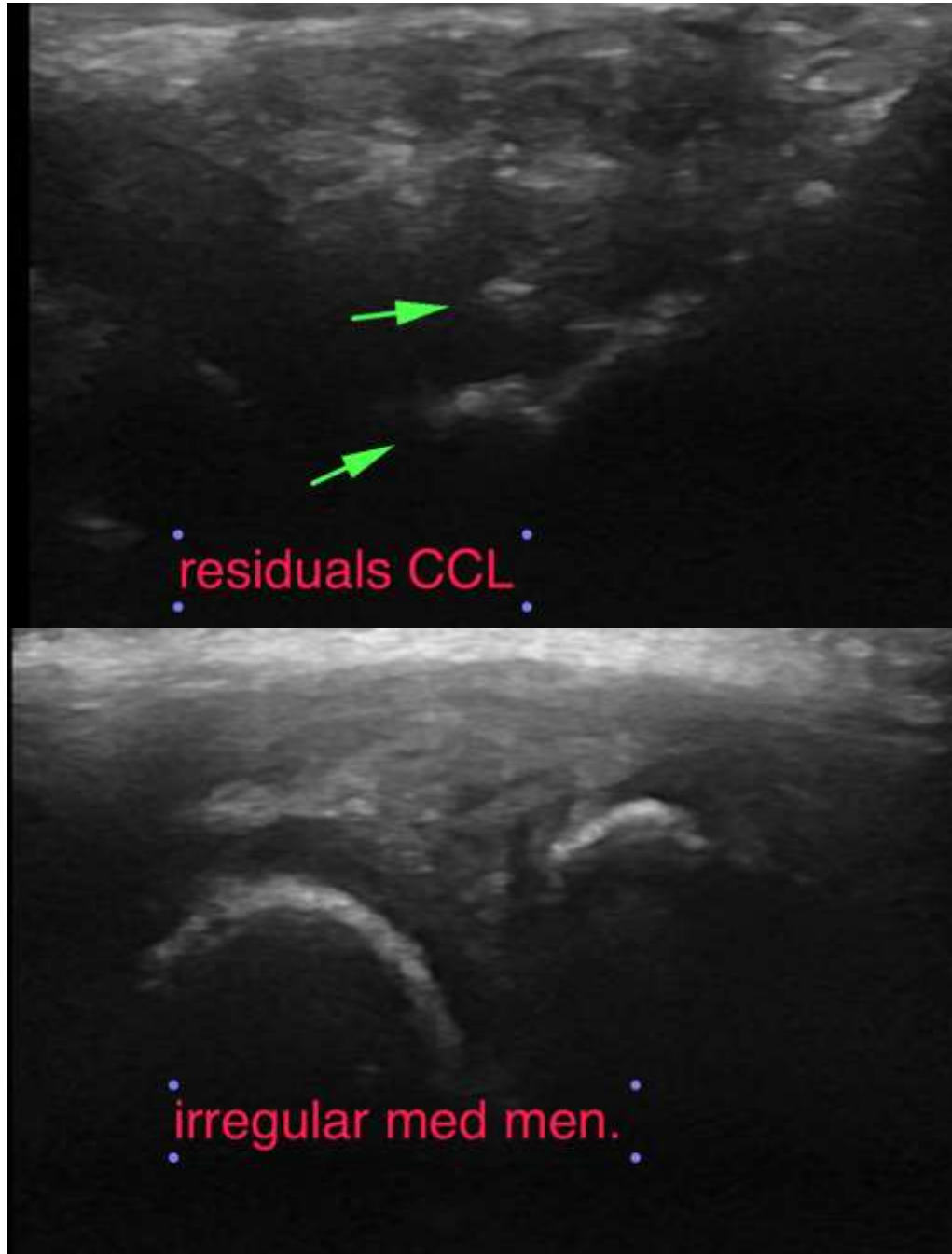
Dr. Brian Barnes

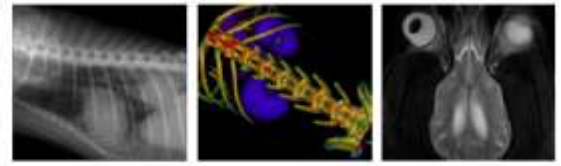
INVOICE

49670

DATE

1-19-22





PATIENT

Bubba Van Dok

The information and recommendations provided are based on the images presented by the referring veterinarian. No evaluation can be communicated regarding pathology that was not visible in the image/video clips provided.

SPECIES

Canine

Thank you for this referral. If the clinical or image interpretation does not parallel your findings or if I can be of any further assistance, please contact me.

BREED

Mastiff Cross

Sebastian Jawinski, German Board Certified Vet Specialist in Diagnostic Imaging
Sebastian.Jawinski@sonopath.com

SEX

M

AGE

3 Years, 2 Months

INTERPRETED BY

Sebastian Jawinski,
German Board
Certified Vet
Specialist in
Diagnostic Imaging

HOSPITAL NAME

Westview Veterinary
Hospital

REFERRING VET

Dr. Brian Barnes

INVOICE

49670

DATE

1-19-22