



**PATIENT**

Raylan Tindall

**PRESENTING CLINICAL SIGNS**

right sided adrenal mass - trying to determine if changed. Dr Jawinski to look at. At the time of this CT he had a partial lung lobe torsion.

**SPECIES**

Canine

**COMPUTED TOMOGRAPHIC STUDY OF THE RIGHT ADRENAL GLAND**

Comparison of the right adrenal gland (RAD) 03/26/21 and 01/11/22.

**BREED**

Shepherd X

**COMPUTED TOMOGRAPHIC FINDINGS**

Diameters in cm

RAD	03/26/21	01/11/22
tra	1.82 x 1.382.17 x 1.95	
sag	2.20 x 1.882.57 x 2.02	
cor	1.83 x 1.522.14 x 2.00	

**SEX**

MN

vessel invasion hypertrophy of the phrenicoabdominal vein noted in both studies  
broad-based contact caudal vena cava

**AGE**

11 Years

Impression CVC no yes

**INTERPRETED BY**

Sebastian Jawinski,  
German Board  
Certified Vet  
Specialist in  
Diagnostic Imaging

**COMPUTED TOMOGRAPHIC DIAGNOSIS**

- Mildly progressive findings of the right adrenal mass

**INTERPRETATION OF THE FINDINGS & FURTHER RECOMMENDATIONS**

Regarding the absolute diameters of the adrenal mass shows mild progression. The impression of the caudal vena cave is an indirect sign for invasion. Suspicion of the latter needs to be confirmed with ultrasound. Hypertrophy of the phrenicoabdominal vein is recognized in both studies. This is a constant finding but may indicate invasion/thrombosis of this vessel as well.

**HOSPITAL NAME**

Animal Health  
Partners

**REFERRING VET**

Dr. Debbie Reynolds

**INVOICE**

49632

**DATE**

1-18-22



**PATIENT**

Raylan Tindall

**SPECIES**

Canine

**BREED**

Shepherd X

**SEX**

MN

**AGE**

11 Years

**INTERPRETED BY**

Sebastian Jawinski,  
German Board  
Certified Vet  
Specialist in  
Diagnostic Imaging

**HOSPITAL NAME**

Animal Health  
Partners

**REFERRING VET**

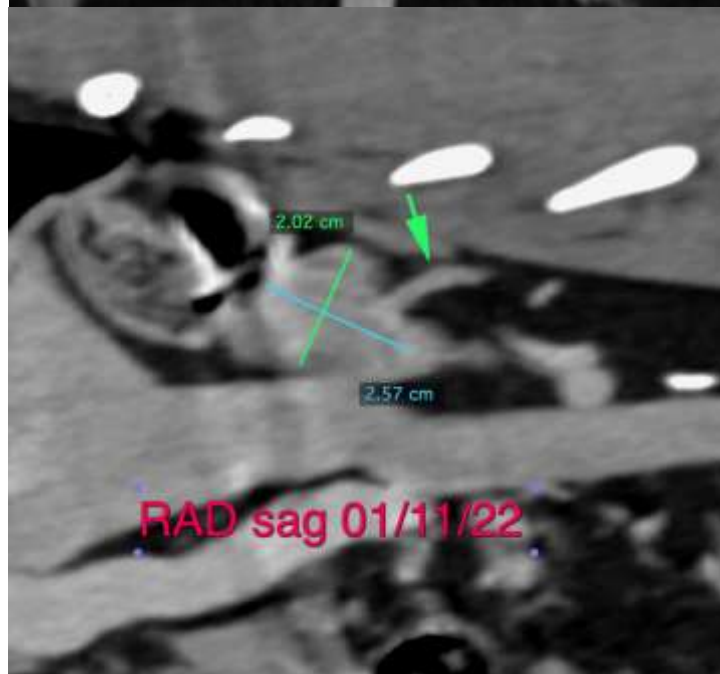
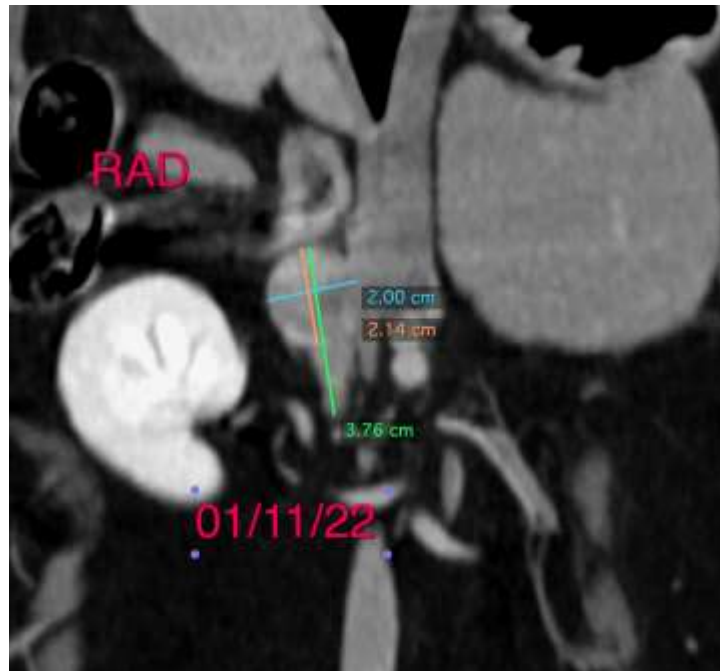Dr. Debbie Reynolds

**INVOICE**

49632

**DATE**

1-18-22





**PATIENT**

Raylan Tindall

**SPECIES**

Canine

**BREED**

Shepherd X

**SEX**

MN

**AGE**

11 Years

**INTERPRETED BY**

Sebastian Jawinski,  
German Board  
Certified Vet  
Specialist in  
Diagnostic Imaging

**HOSPITAL NAME**

Animal Health  
Partners

**REFERRING VET**

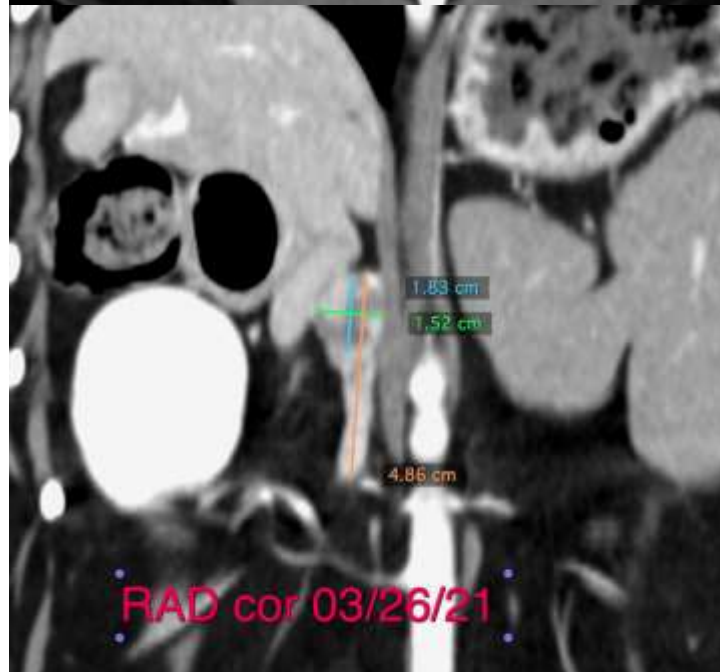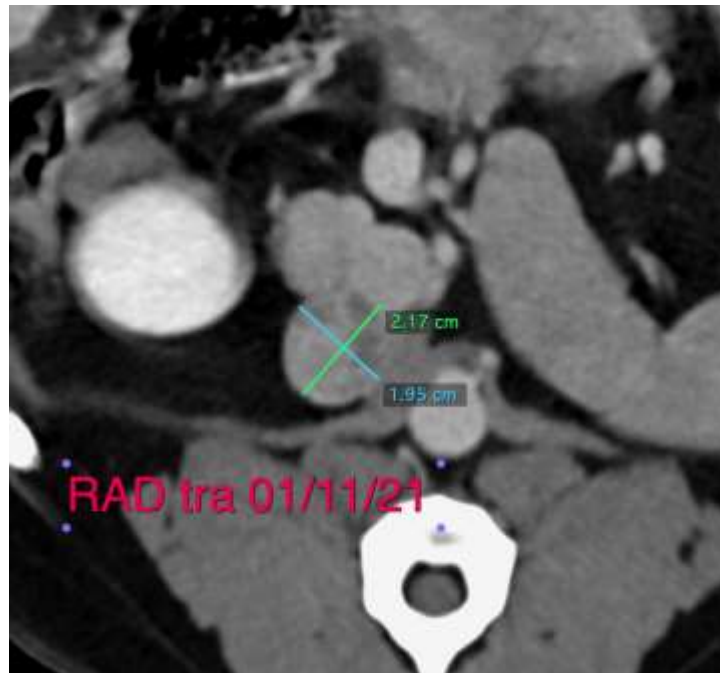
Dr. Debbie Reynolds

**INVOICE**

49632

**DATE**

1-18-22





**PATIENT**

Raylan Tindall

**SPECIES**

Canine

**BREED**

Shepherd X

**SEX**

MN

**AGE**

11 Years

**INTERPRETED BY**

Sebastian Jawinski,  
German Board  
Certified Vet  
Specialist in  
Diagnostic Imaging

**HOSPITAL NAME**

Animal Health  
Partners

**REFERRING VET**

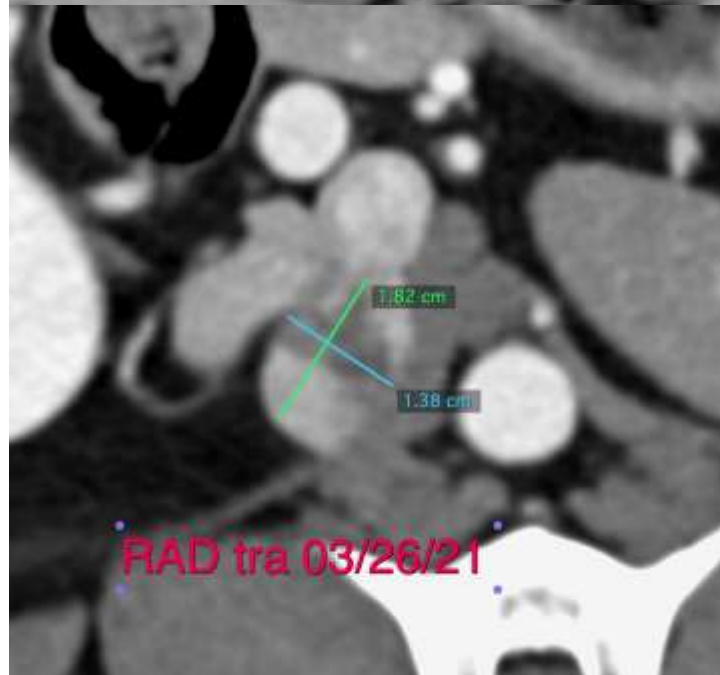
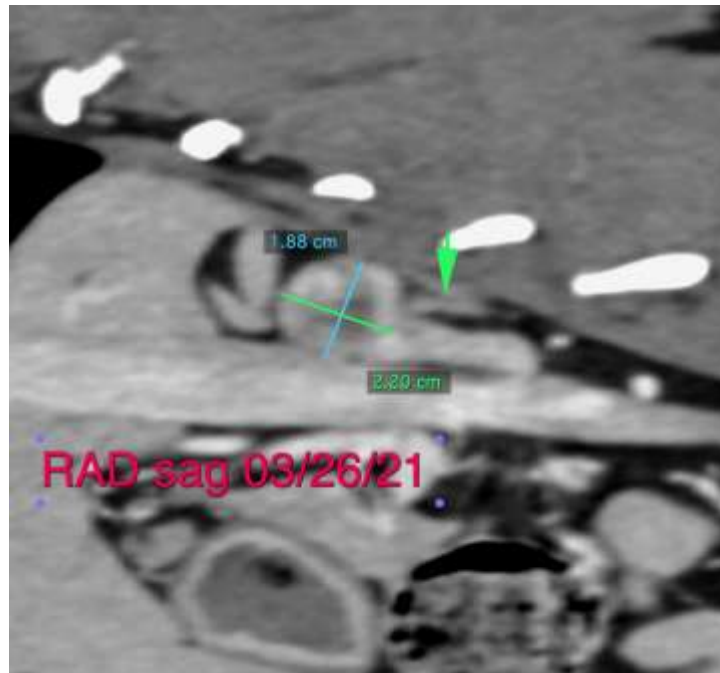
Dr. Debbie Reynolds

**INVOICE**

49632

**DATE**

1-18-22





**PATIENT**

Raylan Tindall

**SPECIES**

Canine

**BREED**

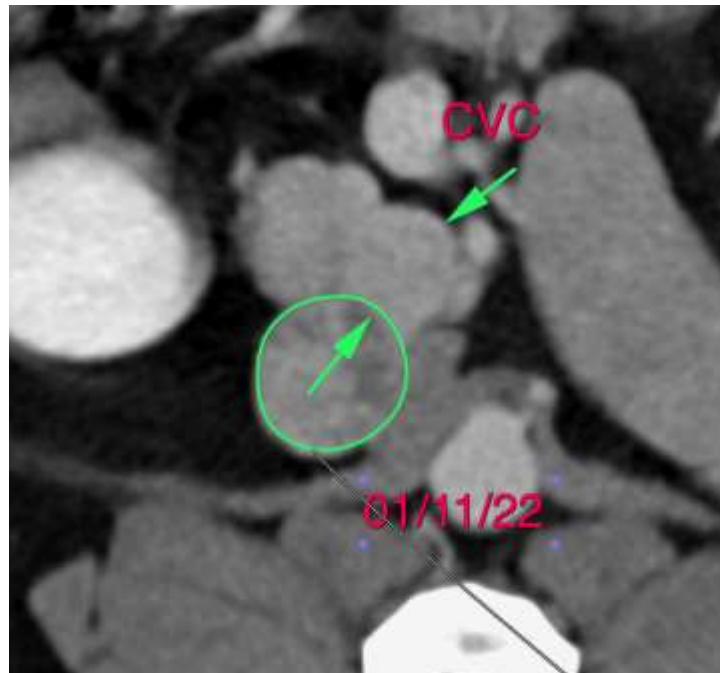
Shepherd X

**SEX**

MN

**AGE**

11 Years



**INTERPRETED BY**

Sebastian Jawinski,  
German Board  
Certified Vet  
Specialist in  
Diagnostic Imaging

The information and recommendations provided are based on the images presented by the referring veterinarian. No evaluation can be communicated regarding pathology that was not visible in the image/video clips provided.

Thank you for this referral. If the clinical or image interpretation does not parallel your findings or if I can be of any further assistance, please contact me.

**HOSPITAL NAME**

Animal Health  
Partners

Sebastian Jawinski, German Board Certified Vet Specialist in Diagnostic Imaging  
Sebastian.Jawinski@sonopath.com

**REFERRING VET**

Dr. Debbie Reynolds

**INVOICE**

49632

**DATE**

1-18-22