

**PATIENT**

Benni Lang

PRESENTING CLINICAL SIGNS

Benni presented for neck pain, first noted 1/15/22.

SPECIES

Canine

Head:

There is a breed-expected brachycephalic head formation noted with marked shortening of the nasal cavities, mild hyperplasia of the soft palate and hyperostosis of the skull bone.

BREED

French Bulldog

Displayed spine:

The intervertebral discs present calcification of the nuclei at multiple levels. Presented bony structures of the spine are breed-appropriate and unremarkable. Vertebral bodies are of regular density without signs of a lytic or sclerotic process. There is no evidence of a fracture and/or sub/-luxation.

SEX

Male

AGE

2 Years

At the level of C3/4 a moderate, partially calcified, broad-based and medial to left lateral to foraminal disc protrusion is recognized causing mild compression of the spinal cord and suspected compression of the left spinal nerve C3/4.

INTERPRETED BY

Paravertebral soft tissues are bilaterally symmetrical.

Sebastian Jawinski,
German Board
Certified Vet
Specialist in
Diagnostic Imaging

COMPUTED TOMOGRAPHIC DIAGNOSIS

- Moderate, calcified disc protrusion C3/4 mild signs of a spinal cord and left -nerve compression
- Marked degeneration of the displayed nuclei
- Brachycephalic head formation and malformation of the thoracic spine

HOSPITAL NAME

Animal Surgical
Center

INTERPRETATION OF THE FINDINGS & FURTHER RECOMMENDATIONS

CT findings of C3/4 likely match with the clinical presentation and show an acute disc protrusion. Symptoms should be pronounced on the left side. If symptoms do not improve and/or neurologic deficits are present surgical decompression should be considered (ventral slot). The left foraminal inclusion and the multiple degenerative discs may limit the long term prognosis.

REFERRING VET

West Hampton Beach
AH

INVOICE

49635

DATE

1-18-22



PATIENT

Benni Lang

SPECIES

Canine

BREED

French Bulldog

SEX

Male

AGE

2 Years

INTERPRETED BY

Sebastian Jawinski,
German Board
Certified Vet
Specialist in
Diagnostic Imaging

HOSPITAL NAME

Animal Surgical
Center

REFERRING VET

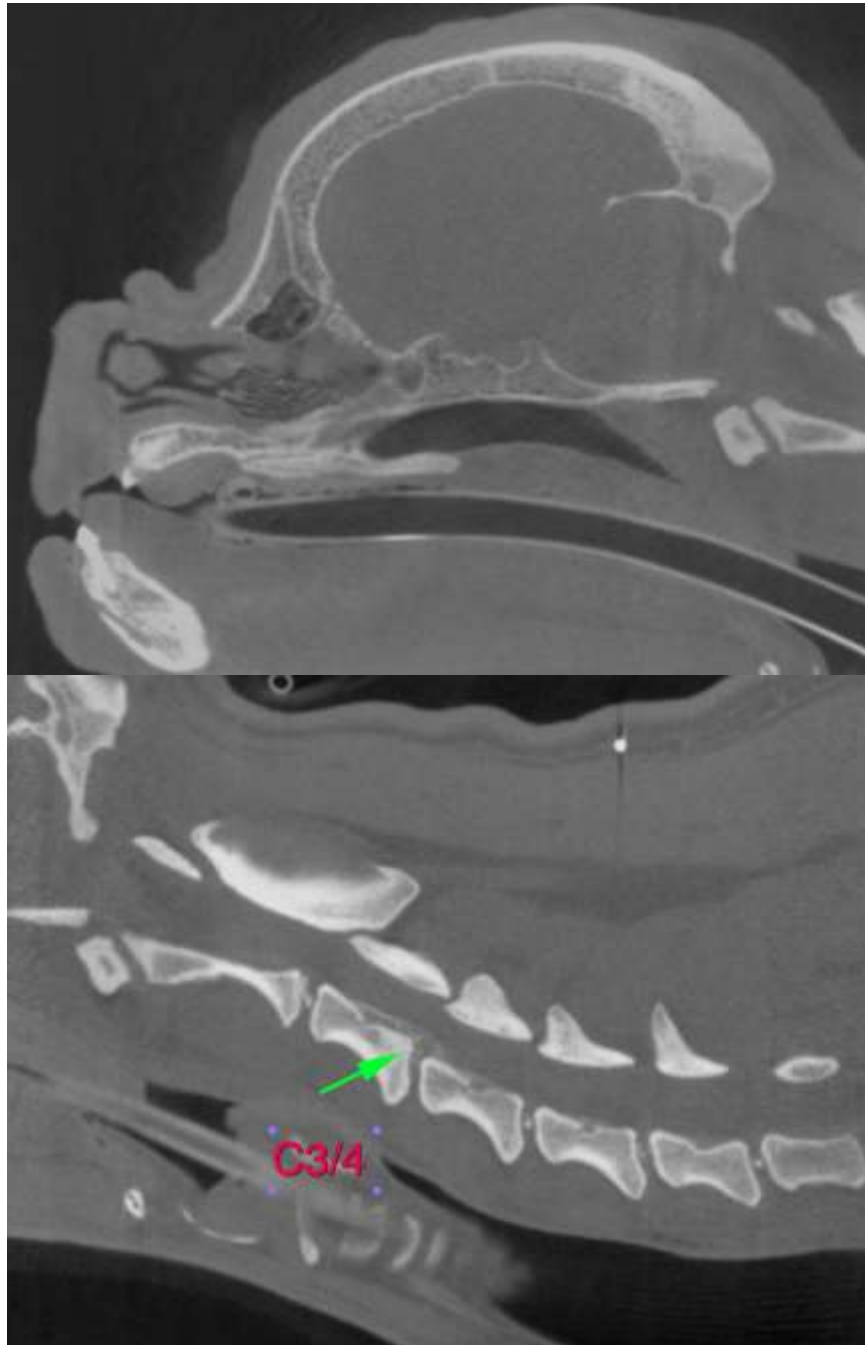
West Hampton Beach
AH

INVOICE

49635

DATE

1-18-22





PATIENT

Benni Lang

SPECIES

Canine

BREED

French Bulldog

SEX

Male

AGE

2 Years

INTERPRETED BY

Sebastian Jawinski,
German Board
Certified Vet
Specialist in
Diagnostic Imaging

HOSPITAL NAME

Animal Surgical
Center

REFERRING VET

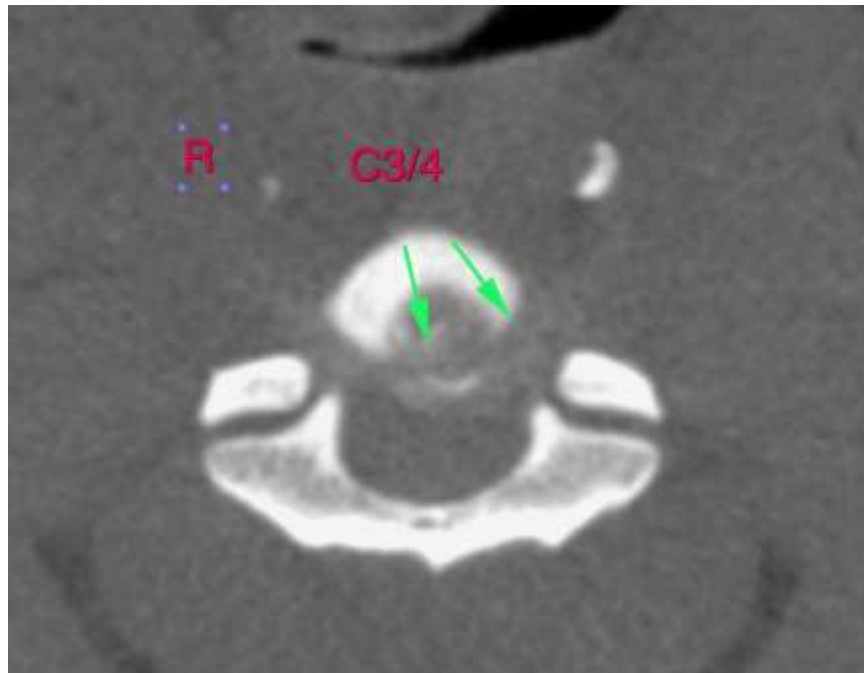
West Hampton Beach
AH

INVOICE

49635

DATE

1-18-22



The information and recommendations provided are based on the images presented by the referring veterinarian. No evaluation can be communicated regarding pathology that was not visible in the image/video clips provided.

Thank you for this referral. If the clinical or image interpretation does not parallel your findings or if I can be of any further assistance, please contact me.

Sebastian Jawinski, German Board Certified Vet Specialist in Diagnostic Imaging
Sebastian.Jawinski@sonopath.com