



## PATIENT

Aiden Vigil

## SPECIES

Canine

## BREED

Terrier Mix

## SEX

Neutered Male

## AGE

12

## WEIGHT

48.2

## INTERPRETED BY

Sebastian Jawinski,  
German Board  
Certified Vet Specialist  
in Diagnostic Imaging

## IMAGING PERFORMED BY

Steph and Alisha

## HOSPITAL NAME

Petroglyph AH

## REFERRING VET

Eric Randall, DVM

## INVOICE

35442

## DATE

1/15/26

## PRESENTING CLINICAL SIGNS

History: Recurrent pneumonia following vomiting. History of pancreatitis flair ups over the last few years. Pneumonia follows after pancreatitis episodes. Transtracheal wash performed after CT scan. Culture pending.

## COMPUTED TOMOGRAPHIC STUDY OF THE CHEST

The right caudal lung lobe presents marked interstitial densities with distended bronchi in the periphery and mild peri-bronchial infiltrates. Relevant nodular or diffuse pulmonary changes are not recognized. The lungs are regularly ventilated apart from that including the main stem bronchi and trachea. Radiopaque foreign material is not recognized. There is no evidence of free pleural fluid. The cranial mediastinum shows a mild increase of density. The mediastinal lymph nodes are inconspicuous.

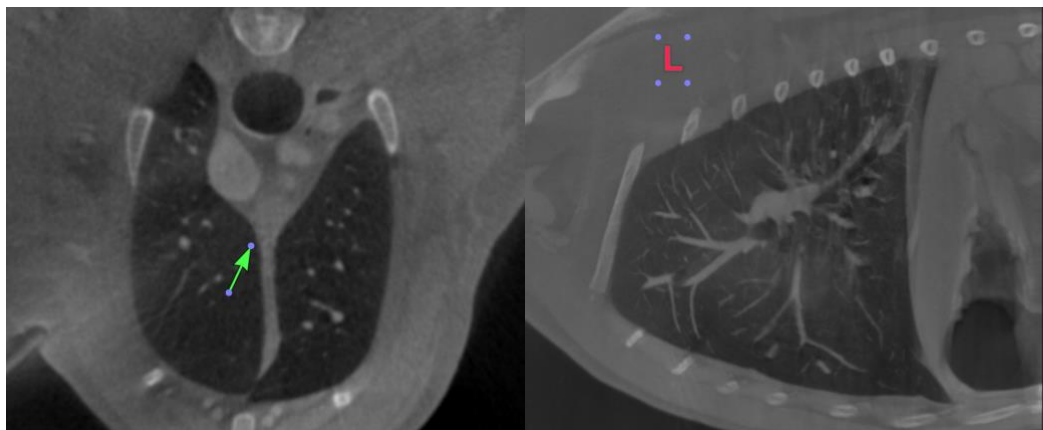
The thoracic borders including the diaphragm do not show particular findings.

## COMPUTED TOMOGRAPHIC DIAGNOSIS

- Broncho-interstitial lung pattern right caudal lung lobe

## INTERPRETATION OF THE FINDINGS & FURTHER RECOMMENDATIONS

The CT findings are mild from a CT perspective and present a broncho-interstitial pattern that is more or less limited to the dorsal aspects of the right caudal lung lobe. These changes are thought to be of inflammatory origin and could represent local bronchopneumonia. Similar findings are recognized with atelectasis caused by anesthesia and positioning in right lateral recumbency right before CT. Typical signs of an aspiration pneumonia are not recognized. Furthermore, radiopaque foreign material is not noted. This does not exclude aspirated material. For further assessment -as already done- complementary endoscopy and sampling could be performed next.





## PATIENT

Aiden Vigil

## SPECIES

Canine

## BREED

Terrier Mix

## SEX

Neutered Male

## AGE

12

## WEIGHT

48.2

## INTERPRETED BY

Sebastian Jawinski,  
German Board  
Certified Vet Specialist  
in Diagnostic Imaging

## IMAGING PERFORMED BY

Steph and Alisha

## HOSPITAL NAME

Petroglyph AH

## REFERRING VET

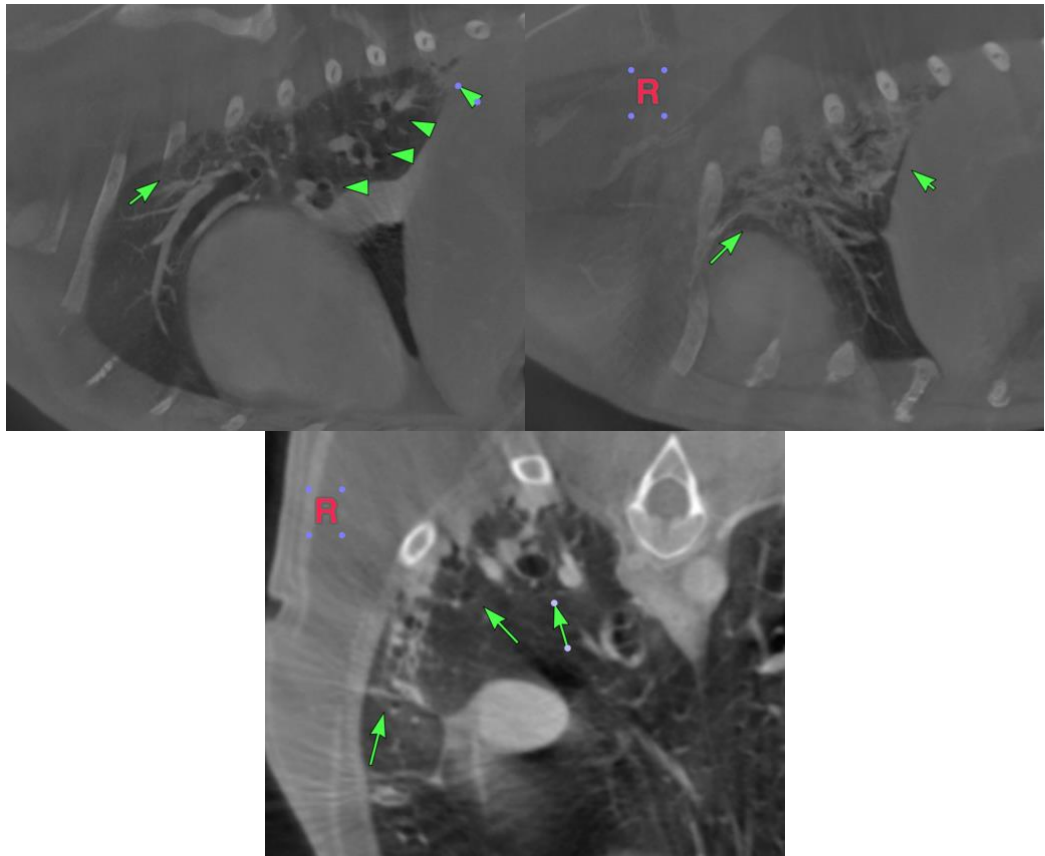
Eric Randall, DVM

## INVOICE

35442

## DATE

1/15/26



**The information and recommendations provided are based on the images presented by the referring veterinarian/sonographer. No evaluation can be communicated regarding pathology that was not visible in the image/video clips provided.**

Thank you for this referral. If the clinical or image interpretation does not parallel your findings or if I can be of any further assistance, please contact me.

**Sebastian Jawinski, German Board Certified Vet Specialist in Diagnostic Imaging**  
[info@sonopath.com](mailto:info@sonopath.com)