



PATIENT

Ada Wiegand

SPECIES

Dog

BREED

Siberian Husky

SEX

Spayed Female

AGE

11

WEIGHT

70

INTERPRETED BY

Sebastian Jawinski,
German Board
Certified Vet Specialist
in Diagnostic Imaging

IMAGING PERFORMED BY

WS

HOSPITAL NAME

Aloha Pet & Bird
Hospital

REFERRING VET

Dr. Jose Pepen

INVOICE

73295

DATE

1-13-26

PRESENTING CLINICAL SIGNS

hx of 4 month favoring left front limb.

COMPUTED TOMOGRAPHIC FINDINGS

Right Forelimb

The displayed parts of the right paw, metacarpal bones including the sesamoid bones and carpal joint are inconspicuous. There are no signs of a lytic/sclerotic process or soft tissue swelling. There is no evidence of a fracture, subluxation or relevant degeneration.

The right elbow joint look normal with well-defined bone surfaces and without signs of a fracture, sub-/luxation or an osteolytic/sclerotic process. The periarticular soft tissues are in expected normal limits.

The right shoulder joint presents a normal caudal humeral head. The bicipital groove is inconspicuous with a normal origin and course of the biceps tendon. The insertion of the infra- und supraspinatus muscles is unremarkable. There is no overt evidence of joint effusion. The periarticular soft tissues and the brachial plexus do not show particular findings.

The displayed spine shows no evidence of a compressive lesion.

COMPUTED TOMOGRAPHIC DIAGNOSIS

- Normal CT findings right forelimb

INTERPRETATION OF THE FINDINGS & FURTHER RECOMMENDATIONS

The CT findings do not explain the reported patient's history. Signs of an aggressive lesion, neoplasia, and/or an active inflammatory process are not noted. Relevant degeneration is not present. This does not fully exclude inflammatory changes in the soft tissues and functional/dolent problems due to an ongoing improper load.



PATIENT

Ada Wiegand

SPECIES

Dog

BREED

Siberian Husky

SEX

Spayed Female

AGE

11

WEIGHT

70

INTERPRETED BY

Sebastian Jawinski,
German Board
Certified Vet Specialist
in Diagnostic Imaging

IMAGING PERFORMED BY

WS

HOSPITAL NAME

Aloha Pet & Bird
Hospital

REFERRING VET

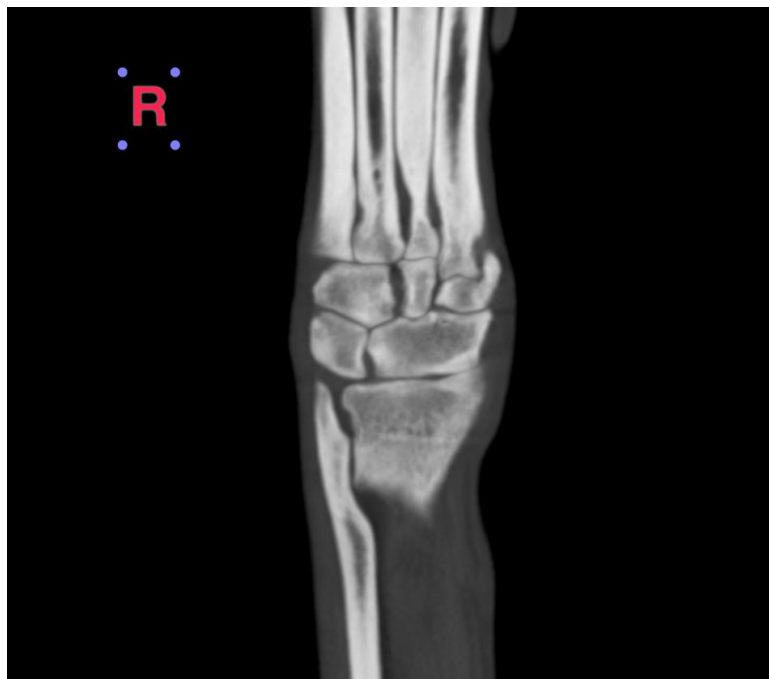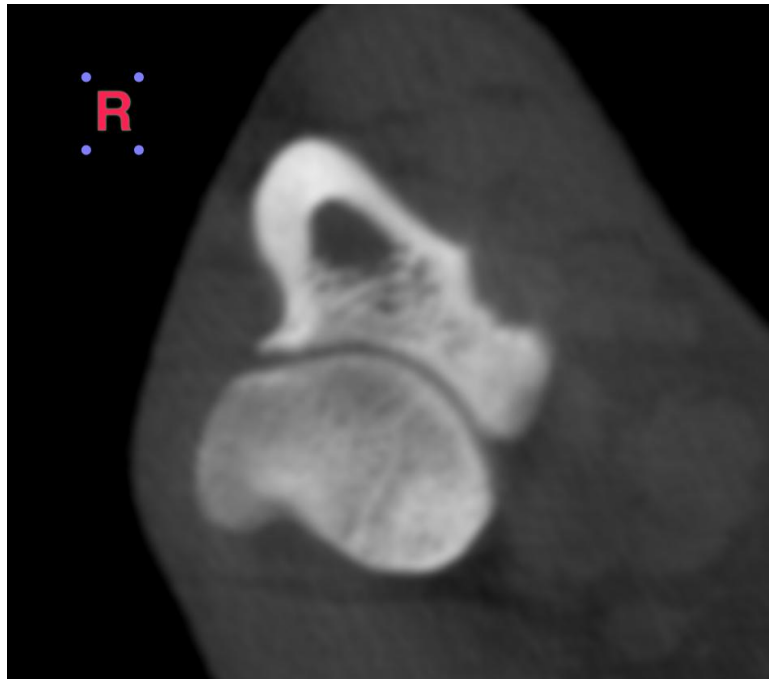
Dr. Jose Pepen

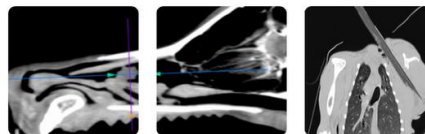
INVOICE

73295

DATE

1-13-26





PATIENT

Ada Wiegand

SPECIES

Dog

BREED

Siberian Husky

SEX

Spayed Female

AGE

11

WEIGHT

70

INTERPRETED BY

Sebastian Jawinski,
German Board
Certified Vet Specialist
in Diagnostic Imaging

IMAGING PERFORMED BY

WS

HOSPITAL NAME

Aloha Pet & Bird
Hospital

REFERRING VET

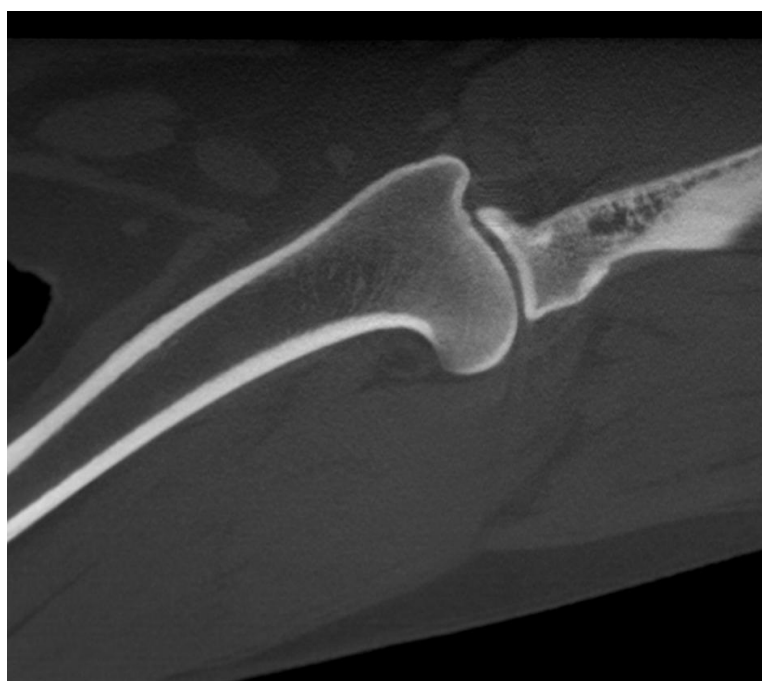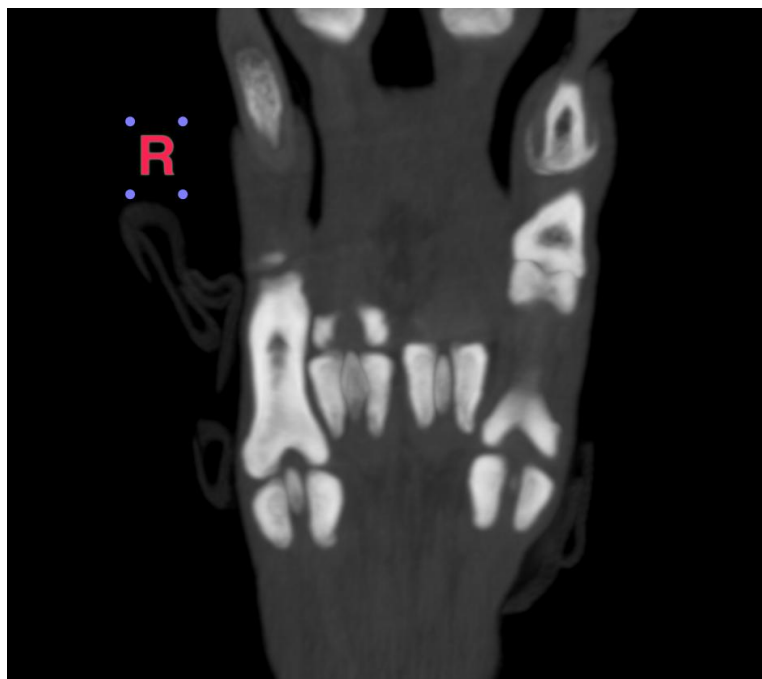Dr. Jose Pepen

INVOICE

73295

DATE

1-13-26





PATIENT

Ada Wiegand

SPECIES

Dog

BREED

Siberian Husky

SEX

Spayed Female

AGE

11

WEIGHT

70

INTERPRETED BY

Sebastian Jawinski,
German Board
Certified Vet Specialist
in Diagnostic Imaging

IMAGING PERFORMED BY

WS

HOSPITAL NAME

Aloha Pet & Bird
Hospital

REFERRING VET

Dr. Jose Pepen

INVOICE

73295

DATE

1-13-26

The information and recommendations provided are based on the images presented by the referring veterinarian/sonographer. No evaluation can be communicated regarding pathology that was not visible in the image/video clips provided.

Thank you for this referral. If the clinical or image interpretation does not parallel your findings or if I can be of any further assistance, please contact me.

Sebastian Jawinski, German Board Certified Vet Specialist in Diagnostic Imaging
info@sonopath.com