

**PATIENT**

Hope Cruz

SPECIES

Canine

BREED

Mixed Medium Breed

SEX

M

AGE

7 Years

INTERPRETED BY

Sebastian Jawinski,
German Board
Certified Vet
Specialist in
Diagnostic Imaging

HOSPITAL NAME

Veterinary Image
Center

REFERRING VET

Dr. M. Carrillo, DVM

INVOICE

49516

DATE

1-12-22

PRESENTING CLINICAL SIGNS

Patient was rescued three weeks ago, he was taken to the emergency room for a hit by car. X-rays revealed a fractured humerus, and he went to the surgery center where he had surgery to repair the humerus. Now a patient shows episodes of regurgitation and weight loss in a short time, all the food he eats within a few minutes he vomits. R/O: Stricture esophagus
Abnormal PE/Chem/CBC/UA Results: CBC --- Lymphopenia CHEM --- mild increased BUN and CREA

FLUOROSCOPY SWALLOWING STUDY

The swallowing study shows the bole passing the thoracic inlet and the heart base. There is mild ballooning of the esophageal diameter recognized up to the level of the heart base. Diameter then reduces caudal to the heart still containing ingesta which can be traced cranially to the cardia. Content then swaps back without sufficient contraction/peristalsis of the esophageal wall. Ingesta passing the cardia region into the stomach is not recognized with a further reduced transverse diameter just cranial to the cardia.

FLUOROSCOPIC DIAGNOSIS

- Insufficient esophageal peristalsis with suspected stricture/obstruction of the cardia/cardia region

INTERPRETATION OF THE FINDINGS & FURTHER RECOMMENDATIONS

Findings of the fluoroscopy are not typical for megaesophagus since the distension/ballooning of the esophagus is not of even diameter at all levels. This however does not exclude esophageal dysfunction. Secondary dysfunction due to inflammatory processes is possible as well strictures/obstruction of the gastric inlet. Mass like lesions and foreign material are not detected. I favor an obstructive issue at the level of the cardia with secondary reflux/esophagitis. Endoscopy and/or tomography could be the next diagnostic steps.



PATIENT

Hope Cruz

SPECIES

Canine

BREED

Mixed Medium Breed

SEX

M

AGE

7 Years

INTERPRETED BY

Sebastian Jawinski,
German Board
Certified Vet
Specialist in
Diagnostic Imaging

HOSPITAL NAME

Veterinary Image
Center

REFERRING VET

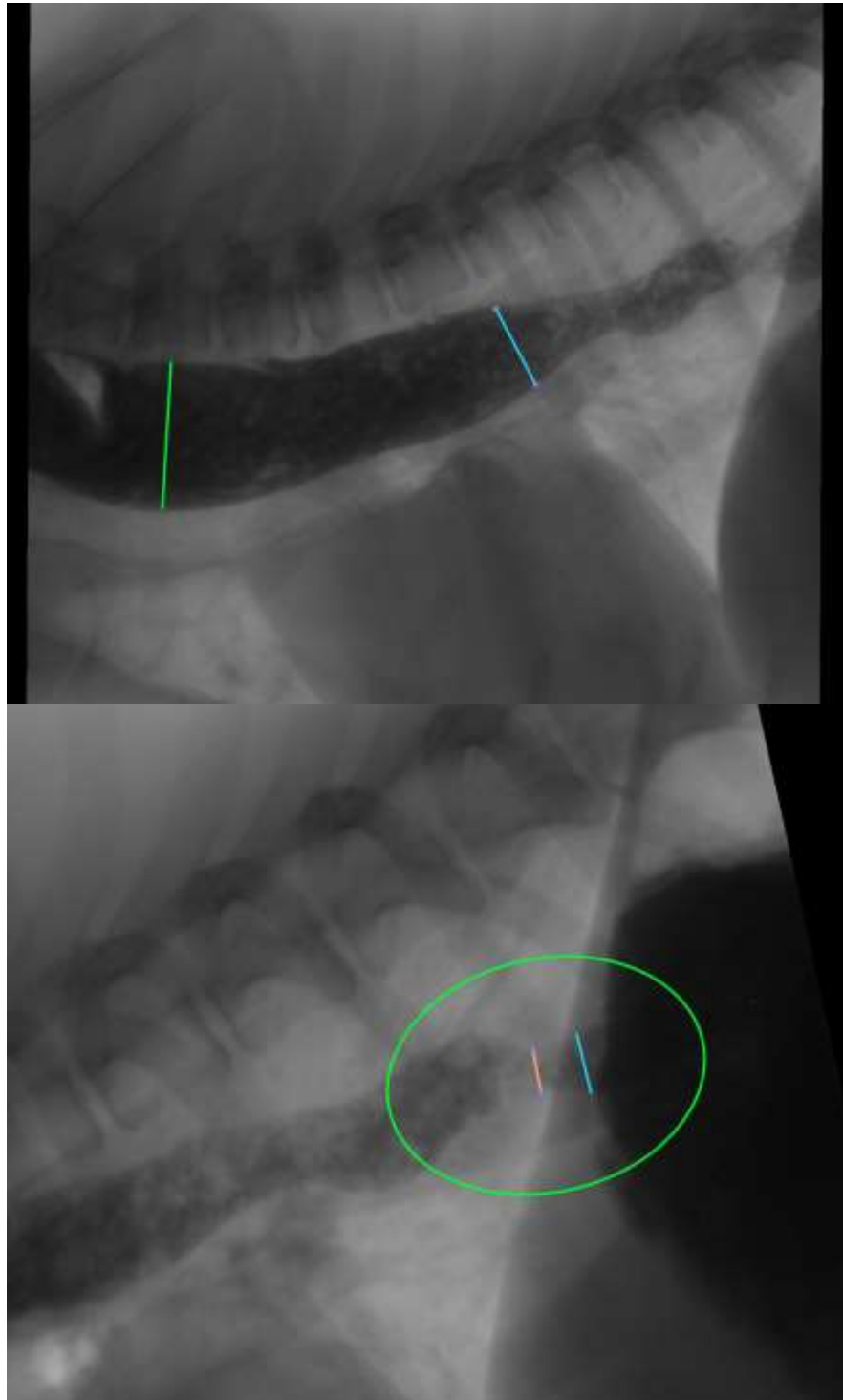
Dr. M. Carrillo, DVM

INVOICE

49516

DATE

1-12-22





PATIENT

Hope Cruz

The information and recommendations provided are based on the images presented by the referring veterinarian. No evaluation can be communicated regarding pathology that was not visible in the image/video clips provided.

Thank you for this referral. If the clinical or image interpretation does not parallel your findings or if I can be of any further assistance, please contact me.

SPECIES

Canine

Sebastian Jawinski, German Board Certified Vet Specialist in Diagnostic Imaging
Sebastian.Jawinski@sonopath.com

BREED

Mixed Medium Breed

SEX

M

AGE

7 Years

INTERPRETED BY

Sebastian Jawinski,
German Board
Certified Vet
Specialist in
Diagnostic Imaging

HOSPITAL NAME

Veterinary Image
Center

REFERRING VET

Dr. M. Carrillo, DVM

INVOICE

49516

DATE

1-12-22