



**PATIENT**

Eeyore Cumpston

**PRESENTING CLINICAL SIGNS**

Presented for standard COHAT.

**SPECIES**

Canine

**COMPUTED TOMOGRAPHIC FINDINGS**

**Head**

The frontal sinuses and the orbital contents are laterally symmetrical without evidence of a retrobulbar lesion and/or an oro-nasal fistula. Nasal cavities/conches and septum present normal findings.

**BREED**

Alastian Shepalute

The maxillary teeth present mild horizontal loss of alveolar bone. The 208 is missing. There is no evidence of residual roots. Relevant periapical lysis is not recognized.

**SEX**

MN

The soft tissues are symmetrical, of homogeneous density, and regarded as normal.

**AGE**

3 Years

**COMPUTED TOMOGRAPHIC DIAGNOSIS**

- Mild horizontal loss of alveolar bone maxillary teeth
- 208 missing

**INTERPRETED BY**

Sebastian Jawinski,  
German Board  
Certified Vet  
Specialist in  
Diagnostic Imaging

**INTERPRETATION OF THE FINDINGS & FURTHER RECOMMENDATIONS**

The mild horizontal loss of the maxillary bone indicates mild and chronic inflammation. There is no obvious evidence of a florid-inflammatory process recognized. CT findings must be correlated with the clinical presentation.

**HOSPITAL NAME**

South Bay Animal  
Hospital & Pet Resort

**REFERRING VET**

Dr. Ravinder Atwal

**INVOICE**

49510

**DATE**

1-12-22



**PATIENT**

Eeyore Cumpston

**SPECIES**

Canine

**BREED**

Alastian Shepalute

**SEX**

MN

**AGE**

3 Years

**INTERPRETED BY**

Sebastian Jawinski,  
German Board  
Certified Vet  
Specialist in  
Diagnostic Imaging

**HOSPITAL NAME**

South Bay Animal  
Hospital & Pet Resort

**REFERRING VET**

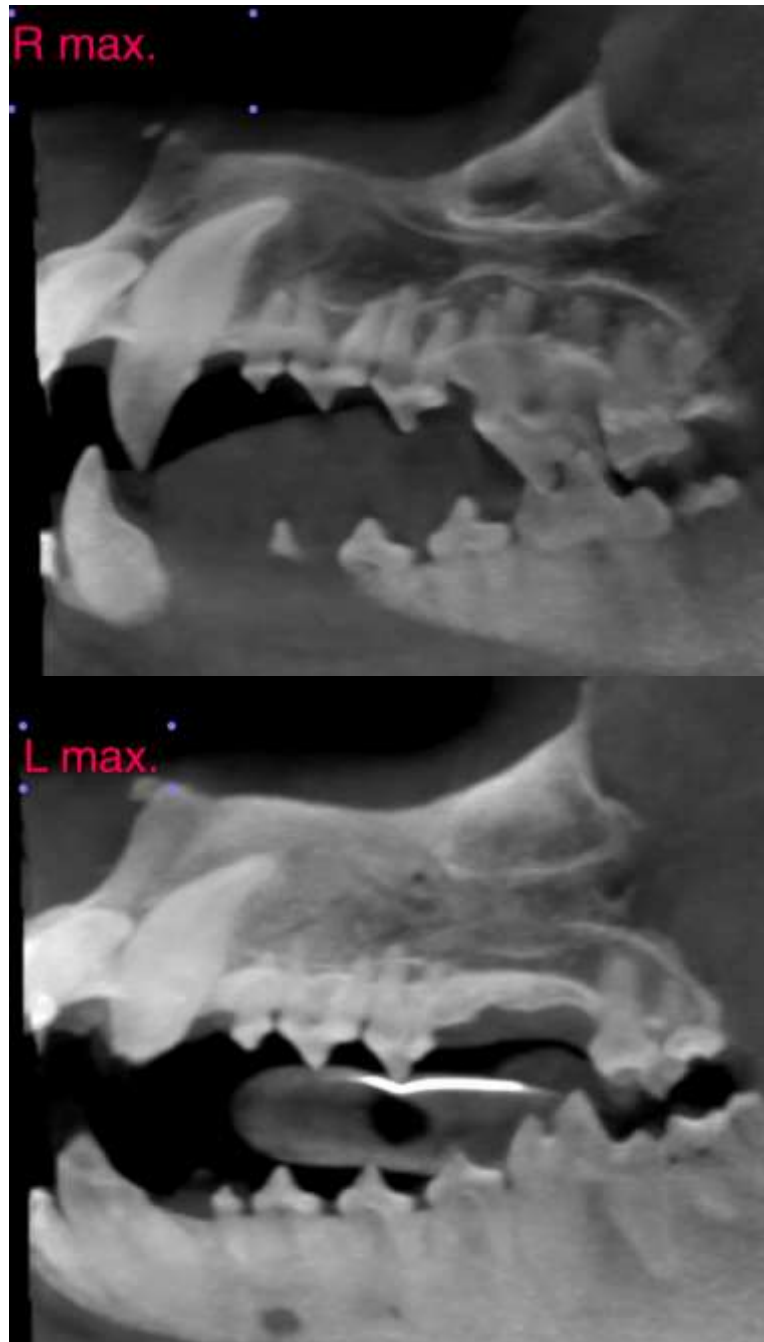Dr. Ravinder Atwal

**INVOICE**

49510

**DATE**

1-12-22





**PATIENT**

Eeyore Cumpston

**SPECIES**

Canine

**BREED**

Alastian Shepalute

**SEX**

MN

**AGE**

3 Years

**INTERPRETED BY**

Sebastian Jawinski,  
German Board  
Certified Vet  
Specialist in  
Diagnostic Imaging

**HOSPITAL NAME**

South Bay Animal  
Hospital & Pet Resort

**REFERRING VET**

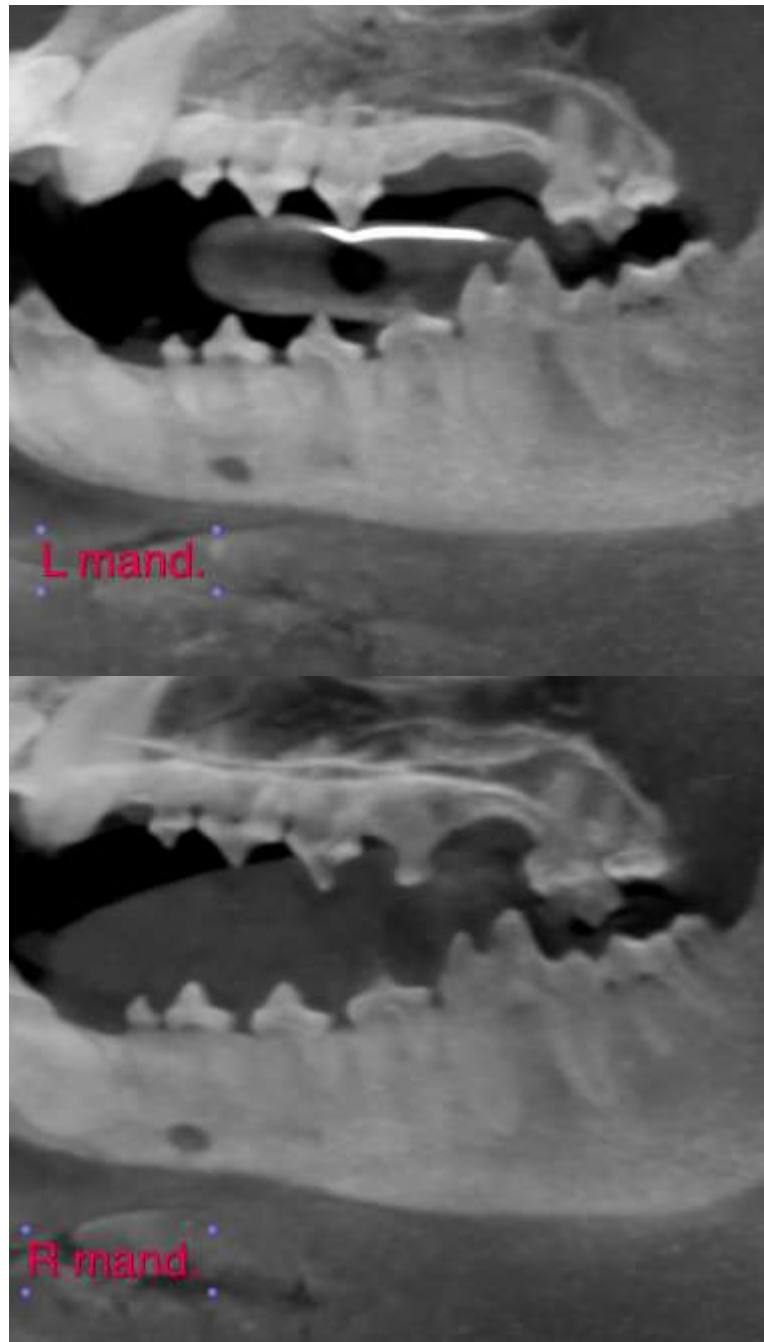
Dr. Ravinder Atwal

**INVOICE**

49510

**DATE**

1-12-22





**PATIENT**

Eeyore Cumpston

**SPECIES**

Canine

**BREED**

Alastian Shepalute

**SEX**

MN

**AGE**

3 Years

**INTERPRETED BY**

Sebastian Jawinski,  
German Board  
Certified Vet  
Specialist in  
Diagnostic Imaging

**HOSPITAL NAME**

South Bay Animal  
Hospital & Pet Resort

**REFERRING VET**

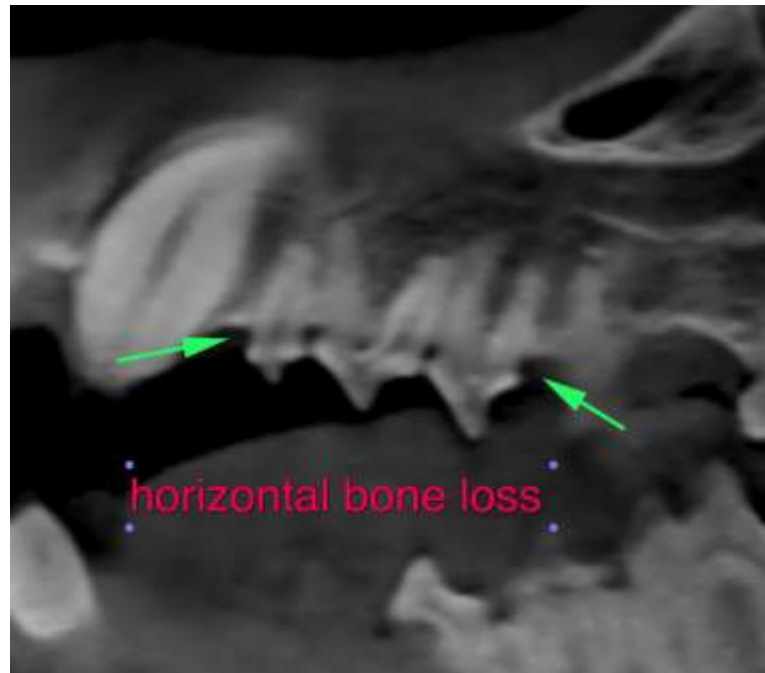
Dr. Ravinder Atwal

**INVOICE**

49510

**DATE**

1-12-22



The information and recommendations provided are based on the images presented by the referring veterinarian. No evaluation can be communicated regarding pathology that was not visible in the image/video clips provided.

Thank you for this referral. If the clinical or image interpretation does not parallel your findings or if I can be of any further assistance, please contact me.

**Sebastian Jawinski, German Board Certified Vet Specialist in Diagnostic Imaging**  
Sebastian.Jawinski@sonopath.com