

**PATIENT**

Breeze Nosworgthy

PRESENTING CLINICAL SIGNS

Unresolved lameness on RF leg, suspect elbow dysplasia

SPECIES

Canine

COMPUTED TOMOGRAPHIC FINDINGS

Left elbow:

The radioulnar joint space is congruent. There are no osteophytic changes noted. The subchondral bone especially of the trochlea is inconspicuous. The medial coronoid process is clearly defined, rounded and presents a homogeneous density without signs of fragmentation and/or a fissure line. The periarticular soft tissue is unremarkable.

BREED

Golden Retriever

Right elbow:

The right elbow shows a marked incongruity of the radioulnar joint space. Formation of osteophytes at all parts of the joint is recognized especially at the level of the medial epicondyle. The medial coronoid process is irregular in shape and indistinct in its tip with a decreased density of the cranial contour. A fragment at the tip of the process is not overt. The periarticular soft tissue is unremarkable.

SEX

Female Intact

AGE

8 Months

INTERPRETED BY

Sebastian Jawinski,
German Board
Certified Vet
Specialist in
Diagnostic Imaging

COMPUTED TOMOGRAPHIC DIAGNOSIS

- Lesion of the medial coronoid process on the right with moderate secondary arthrosis
- Normal left elbow joint

INTERPRETATION OF THE FINDINGS & FURTHER RECOMMENDATIONS

CT findings of the right elbow joint are most likely relevant and consistent with canine elbow dysplasia. With regard to the clinical presentation surgery should be considered.

HOSPITAL NAME

Bridgwater
Veterinary Hospital
and Wellness Centre

REFERRING VET

Dr. Aaron Mooi

INVOICE

49511

DATE

1-12-22



PATIENT

Breeze Nosworgthy

SPECIES

Canine

BREED

Golden Retriever

SEX

Female Intact

AGE

8 Months

INTERPRETED BY

Sebastian Jawinski,
German Board
Certified Vet
Specialist in
Diagnostic Imaging

HOSPITAL NAME

Bridgwater
Veterinary Hospital
and Wellness Centre

REFERRING VET

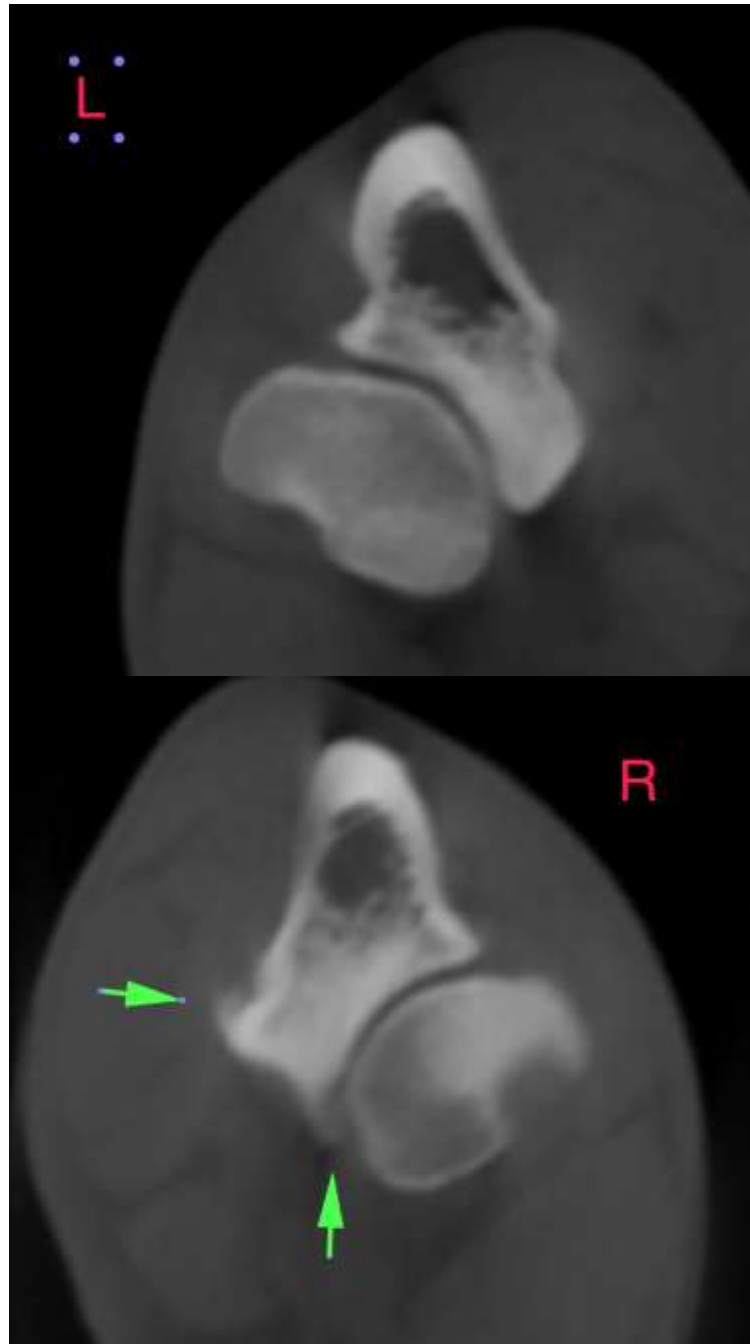
Dr. Aaron Mooi

INVOICE

49511

DATE

1-12-22





PATIENT

Breeze Nosworgthy

SPECIES

Canine

BREED

Golden Retriever

SEX

Female Intact

AGE

8 Months

INTERPRETED BY

Sebastian Jawinski,
German Board
Certified Vet
Specialist in
Diagnostic Imaging

HOSPITAL NAME

Bridgwater
Veterinary Hospital
and Wellness Centre

REFERRING VET

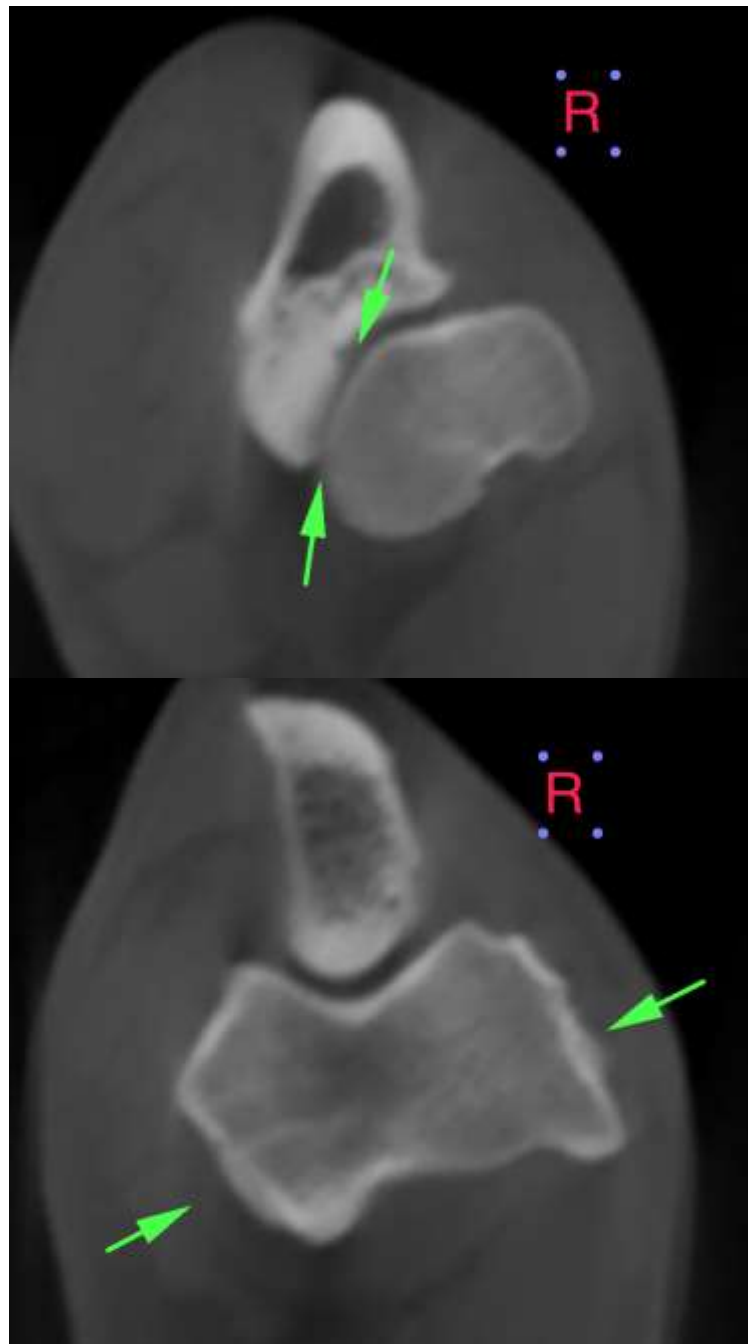
Dr. Aaron Mooi

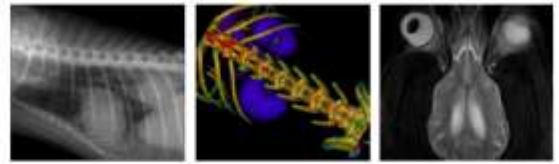
INVOICE

49511

DATE

1-12-22





PATIENT

Breeze Nosworgthy

The information and recommendations provided are based on the images presented by the referring veterinarian. No evaluation can be communicated regarding pathology that was not visible in the image/video clips provided.

SPECIES

Canine

Thank you for this referral. If the clinical or image interpretation does not parallel your findings or if I can be of any further assistance, please contact me.

Sebastian Jawinski, German Board Certified Vet Specialist in Diagnostic Imaging
Sebastian.Jawinski@sonopath.com

BREED

Golden Retriever

SEX

Female Intact

AGE

8 Months

INTERPRETED BY

Sebastian Jawinski,
German Board
Certified Vet
Specialist in
Diagnostic Imaging

HOSPITAL NAME

Bridgwater
Veterinary Hospital
and Wellness Centre

REFERRING VET

Dr. Aaron Mooi

INVOICE

49511

DATE

1-12-22