

**PATIENT**

Misty Fallavollita

**SPECIES**

Feline

**BREED**

DSH

**SEX**

Spayed Female

**AGE**

17 Years

**WEIGHT**

3.37 kg

**INTERPRETED BY**

Sara Brethel, DVM,  
 DACVIM (Cardiology)

**IMAGING PERFORMED BY**

Amanda Stewart

**HOSPITAL NAME**

Waterloo West AH

**REFERRING VET**

Dr. Gajadhar

**INVOICE**

36322

**DATE**

6/4/26

**PRESENTING CLINICAL SIGNS**

History: heart murmur; bleeding from the vulva (abdominal US done - revealed irregularities in bladder (thickened bladder wall, irregular mucosal surface and hyperechoic intraluminal material within the bladder); Decreased appetite, and concerns with weight loss.

Current Medications: Convenia (04.05.2026)

Abnormal PE/Chem/CBC/UA Results: Elevated NEUT (11.39) and MONO (1.05); biochemistry and T4 was normal except for elevated SDMA (21) with normal BUN and CREAT Radiographic Findings / Primary Question to Be Answered in This Exam degree of heart disease, medication needed?

**ULTRASONOGRAPHIC EXAMINATION OF THE HEART**

FELINE CARDIAC PARAMETERS	BODY WEIGHT (kg)	HR (BPM)	IVSd (cm)	LVIDd (cm)	LVWd (cm)	FS (%)	EF (%)
<b>NORMAL PARAMETER</b>	-----	150-240	0.3-0.6	1.0-2.1	0.25-0.6	35-67	80-100
<b>PATIENT</b>	3.37	157	0.36	1.0	0.44	42	--
FELINE CARDIAC PARAMETERS	LA/AO (M-mode)	LA/AO HEART BASE (Sisson)	LAD LA MAX 4 Chamber		LVOT VEL. (m/s)	RVOT VEL. (m/s)	IVRT (m/)
<b>NORMAL PARAMETER</b>	<1.5	1.6	0.7-1.7		<1.6	<1.3	40-60
<b>PATIENT</b>	1.48	1.05	1.1		0.91	1.33	NM
Adapted from June Boon, Veterinary Echocardiography, 1998 Sisson D et al. JVIM 1991; 5: 232, Jacobs et al. Am J Vet Res 1985; 46:1705							

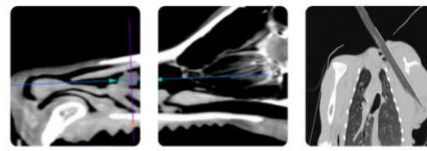
LVIDs: 0.58

**ECG Interpretation**

Normal sinus rhythm.

**Cardiac Presentation**

The mitral valve leaflets are normal and there is no mitral regurgitation. The left atrial size is normal. There is no evidence of systolic anterior motion of the mitral valve and no evidence of a left ventricular outflow tract obstruction. Left ventricular systolic and diastolic function is within normal limits. There is no evidence of left ventricular concentric hypertrophy. There is evidence of a moderator band. There is normal right atrial size without evidence of tricuspid regurgitation. There is no prolapse of the tricuspid valve leaflets and no evidence of pulmonary hypertension on the images provided. The right ventricle appears normal in structure and function subjectively. The aortic and pulmonic valves have normal morphology, and the corresponding outflow velocities are within normal



**PATIENT**

Misty Fallavollita

**SPECIES**

Feline

**BREED**

DSH

**SEX**

Spayed Female

**AGE**

17 Years

**WEIGHT**

3.37 kg

**INTERPRETED BY**

Sara Brethel, DVM,  
 DACVIM (Cardiology)

**IMAGING PERFORMED BY**

Amanda Stewart

**HOSPITAL NAME**

Waterloo West AH

**REFERRING VET**

Dr. Gajadhar

**INVOICE**

36322

**DATE**

6/4/26

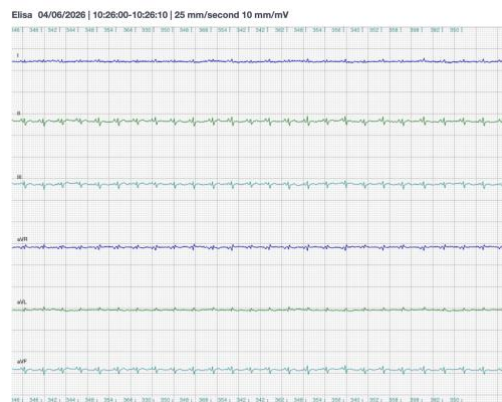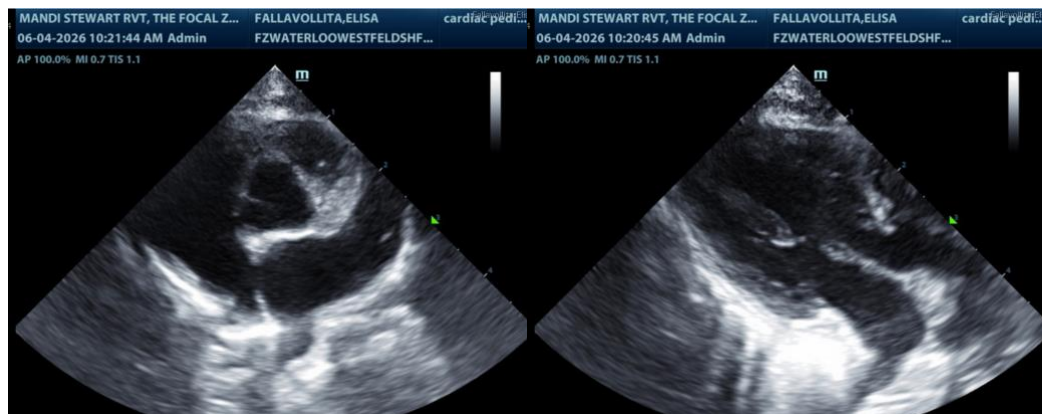
limits. There is no evidence of pulmonic or aortic insufficiency. The aorta appears normal. The pulmonary artery and associated branches appear normal. There is no evidence of pleural effusion, pericardial effusion, or intracardiac masses.

**ULTRASONOGRAPHIC FINDINGS**

- Normal heart
- Moderator band (can be a normal finding)

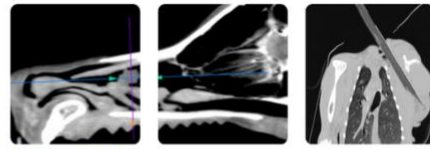
**INTERPRETATION OF THE FINDINGS & FURTHER RECOMMENDATIONS**

The heart murmur is likely innocent versus physiologic. Cause for the murmur is not identified based upon the images provided. The heart is structurally normal. Can consider a recheck echo in 10 - 12 months. Alternatively, can perform a proBNP. If the proBNP becomes elevated, a recheck echo would be indicated at that time.



**The information and recommendations provided are based on the images presented by the referring veterinarian/sonographer. No evaluation can be communicated regarding pathology that was not visible in the image/video clips provided.**

Thank you for this referral. If the clinical or image interpretation does not parallel your findings or if I



**PATIENT**

can be of any further assistance please contact me.

Misty Fallavollita

Sara Brethel DVM, DACVIM (Cardiology)

**SPECIES**

[info@SonoPath.com](mailto:info@SonoPath.com)

Feline

**BREED**

DSH

**SEX**

Spayed Female

**AGE**

17 Years

**WEIGHT**

3.37 kg

**INTERPRETED BY**

Sara Brethel, DVM,  
DACVIM (Cardiology)

**IMAGING  
PERFORMED BY**

Amanda Stewart

**HOSPITAL NAME**

Waterloo West AH

**REFERRING VET**

Dr. Gajadhar

**INVOICE**

36322

**DATE**

6/4/26