



PATIENT

Renji Zubillaga

SPECIES

Canine

BREED

Poodle Mix

SEX

Neutered Male

AGE

7.5 Years

WEIGHT

26 Pounds

INTERPRETED BY

Sara Brethel DVM,
DACVIM (Cardiology)

IMAGING PERFORMED BY

Amy Alivernini, VMD

HOSPITAL NAME

Gilbertsville VH

REFERRING VET

Amy Alivernini, VMD

INVOICE

37564

DATE

6/17/26

PRESENTING CLINICAL SIGNS

History: New patient - heart murmur on exam, screening prior to dental. No cardiac signs at home.

Abnormal PE/Chem/CBC/UA Results: 3/6 L apex systolic murmur, pulses s/s, overweight, dental calculus BP 146mmHg Glob 3.9, ALP 305, A4 neg.

ULTRASONOGRAPHIC EXAMINATION OF THE HEART

CANINE CARDIAC PARAMETERS	MR VMAX (m/s)	TR VMAX (m/s)	LA/AO (M-Mode)	LA/AO (Heart Base; Swe)	FS (%)	EF (%)	EPSS (cm)
NORMAL PARAMETER	4.5-5.5	<2.7	1.3	Up to 1.6	28-40	40-100	<0.6
PATIENT	5.46	--	NM	1.68	36.5	--	--
CANINE CARDIAC PARAMETERS	HR (BPM)	AV VMAX (m/s)	PV MAX (m/s)	BODY WEIGHT (kg)	LAD LA MAX 4 Chamber	LVIDd Avg; 2D and m-mode short axis (cm)	LVIDs Avg; 2D and m-mode short axis (cm)
NORMAL PARAMETER	50-100	0.7-1.7	0.7-1.6				
PATIENT	171	1.48	0.82	11.8	3.22	3.15	2.0

Cardiac Presentation

The mitral valve leaflets are mildly thickened with mild mitral regurgitation posteriorly directed. There is no prolapse of the mitral valve leaflets. The left atrial size is mildly increased. Left ventricular internal dimensions during diastole are within normal limits and systolic function is preserved in the face of mitral regurgitation. There is normal right atrial size without tricuspid regurgitation. There is no prolapse of the tricuspid valve leaflets and no evidence of pulmonary hypertension based upon tricuspid regurgitant velocities. The right ventricle subjectively appears normal in structure and function. The aortic and pulmonic valves have normal morphology, and the corresponding outflow velocities are within normal limits. There is no evidence of pulmonic or aortic insufficiency. The aorta appears normal. The pulmonary artery and associated branches appear normal. There is no evidence of pleural effusion, pericardial effusion, or intracardiac masses.

ULTRASONOGRAPHIC FINDINGS

- Degenerative valve disease, ACVIM stage B2
- Mild left atrial enlargement

INTERPRETATION OF THE FINDINGS & FURTHER RECOMMENDATIONS



PATIENT

Renji Zubillaga

SPECIES

Canine

BREED

Poodle Mix

SEX

Neutered Male

AGE

7.5 Years

WEIGHT

26 Pounds

INTERPRETED BY

Sara Brethel DVM,
DACVIM (Cardiology)

IMAGING PERFORMED BY

Amy Alivernini, VMD

HOSPITAL NAME

Gilbertsville VH

REFERRING VET

Amy Alivernini, VMD

INVOICE

37564

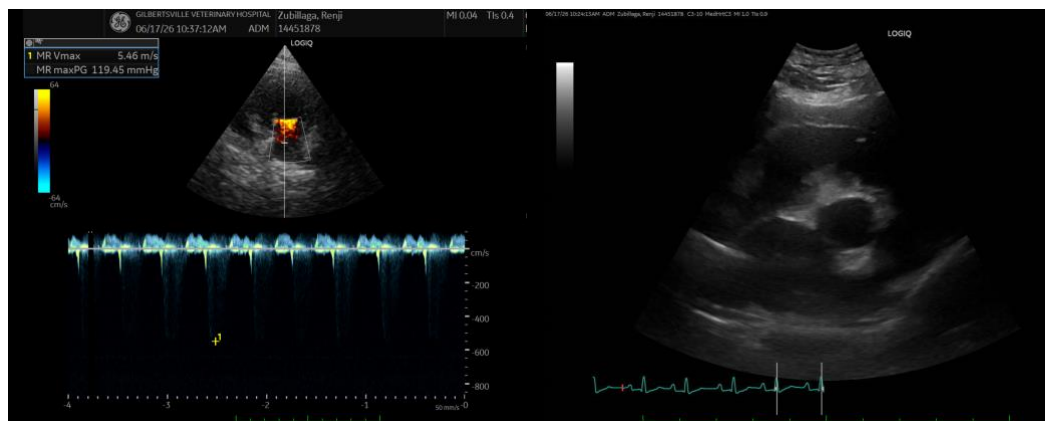
DATE

6/17/26

The patient has degenerative valve disease ACVIM stage B2 and pimobendan therapy at 0.27-0.32mg/kg PO q12 is recommended. This will be a lifelong therapy. A recheck echocardiogram is recommended in 4-6 months to monitor the condition since starting pimobendan. A sooner recheck is recommended if the patient develops cardiovascular clinical signs or the heart murmur is worsening in intensity. The client should start monitoring respiratory rate and effort at home if not already doing so. The resting respiratory rate should be < 35-40 breathes/minute when the patient is resting or sleeping. If the breathing rates are increasing, then chest radiographs are recommended.

The reported blood pressure is within normal limits.

Recommend the patient be on pimobendan for 1-3 weeks prior to elective anesthetic procedures, however, once the patient is on pimobendan, while there is a mildly increased risk, he is likely an adequate anesthetic candidate. Judicious perioperative fluids are recommended due to the increased left atrial size. Medications like dexmedetomidine and other alpha 2 agonists are best avoided. Ketamine is also best avoided. If needed, anticholinergics can be used in the face of a clinically significant bradyarrhythmia (i.e., bradycardia with concurrent hypotension). If the patient is on an ACEi, recommend not giving this therapy the day of anesthesia.



The information and recommendations provided are based on the images presented by the referring veterinarian/sonographer. No evaluation can be communicated regarding pathology that was not visible in the image/video clips provided.

Thank you for this referral. If the clinical or image interpretation does not parallel your findings or if I can be of any further assistance please contact me.

Sara Brethel DVM, DACVIM (Cardiology)

info@SonoPath.com