

**PATIENT**

Cooper Young

**SPECIES**

Canine

**BREED**

Cavalier King Charles Spaniel

**SEX**

Neutered Male

**AGE**

4 Years

**WEIGHT**

20.3 Pounds

**INTERPRETED BY**

Sara Brethel, DVM,  
DACVIM (Cardiology)

**IMAGING PERFORMED BY**

Andrea Nicastro, DVM,  
DACVIM

**HOSPITAL NAME**

Waterway AH

**REFERRING VET**

Dr. Roland

**INVOICE**

37570

**DATE**

6/17/26

**PRESENTING CLINICAL SIGNS**

History: 1-2/6 murmur. HR 100.0, RR 18, BP N/A

**ULTRASONOGRAPHIC EXAMINATION OF THE HEART**

<b>CANINE CARDIAC PARAMETERS</b>	<b>MR VMAX (m/s)</b>	<b>TR VMAX (m/s)</b>	<b>LA/AO (M-Mode)</b>	<b>LA/AO (Heart Base; Swe)</b>	<b>FS (%)</b>	<b>EF (%)</b>	<b>EPSS (cm)</b>
<b>NORMAL PARAMETER</b>	4.5-5.5	<2.7	1.3	Up to 1.6	28-40	40-100	<0.6
<b>PATIENT</b>	NM	NM	1.28	1.34	45.25	--	NM
<b>CANINE CARDIAC PARAMETERS</b>	<b>HR (BPM)</b>	<b>AV VMAX (m/s)</b>	<b>PV MAX (m/s)</b>	<b>BODY WEIGHT (kg)</b>	<b>LAD LA MAX 4 Chamber</b>	<b>LVIDd Avg; 2D and m-mode short axis (cm)</b>	<b>LVIDs Avg; 2D and m-mode short axis (cm)</b>
<b>NORMAL PARAMETER</b>	50-100	0.7-1.7	0.7-1.6				
<b>PATIENT</b>	--	~1.5	~1.0	9.22	2.6	2.74	1.5

**Cardiac Presentation**

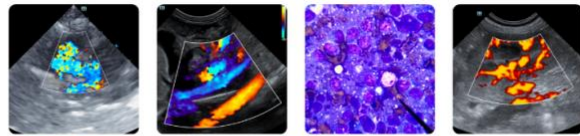
The mitral valve leaflets are mildly thickened with mild mitral regurgitation posteriorly directed. There is no prolapse of the mitral valve leaflet. The left atrial size is normal. Left ventricular internal dimensions during diastole are within normal limits and systolic function is preserved in the face of mitral regurgitation. There is normal right atrial size with mild tricuspid regurgitation. There is no prolapse of the tricuspid valve leaflets and no evidence of pulmonary hypertension based upon tricuspid regurgitant velocities. The right ventricle subjectively appears normal in structure and function. The aortic and pulmonic valves have normal morphology, and the corresponding outflow velocities are within normal limits. There is no evidence of pulmonic or aortic insufficiency. The aorta appears normal. The pulmonary artery and associated branches appear normal. There is no evidence of pleural effusion, pericardial effusion, or intracardiac masses.

**ULTRASONOGRAPHIC FINDINGS**

- Degenerative valve disease, ACVIM stage B1 (mitral and tricuspid)

**INTERPRETATION OF THE FINDINGS & FURTHER RECOMMENDATIONS**

The patient has degenerative valve disease ACVIM stage B1 and no cardiac medications are indicated at this time. Since this can be a progressive condition, serial monitoring is recommended. A recheck echocardiogram is recommended in 10-12 months. A sooner recheck is recommended if the patient develops cardiovascular clinical signs or the heart murmur is worsening in intensity. Elective anesthetic



**PATIENT**

procedures should be well tolerated.

Cooper Young

Recommend obtaining a blood pressure on the patient to ensure it is <160mmHg. If the blood pressure is elevated recommend following ACVIM guidelines for systemic hypertension and treating if indicated.

**SPECIES**

Canine

Standard perioperative fluid rates should be well-tolerated. Medications like dexmedetomidine and other alpha 2 agonists are best avoided. Ketamine is also best avoided. Anticholinergics can be used in the case of a clinically significant bradyarrhythmia (i.e., bradycardia with concurrent hypotension). If the patient is on an ACEi, recommend not giving this therapy the day of anesthesia.

**BREED**

Cavalier King Charles Spaniel

**SEX**

Neutered Male

**AGE**

4 Years

**WEIGHT**

20.3 Pounds

**INTERPRETED BY**

Sara Brethel, DVM,  
 DACVIM (Cardiology)

**IMAGING PERFORMED BY**

Andrea Nicastro, DVM,  
 DACVIM

**HOSPITAL NAME**

Waterway AH

**REFERRING VET**

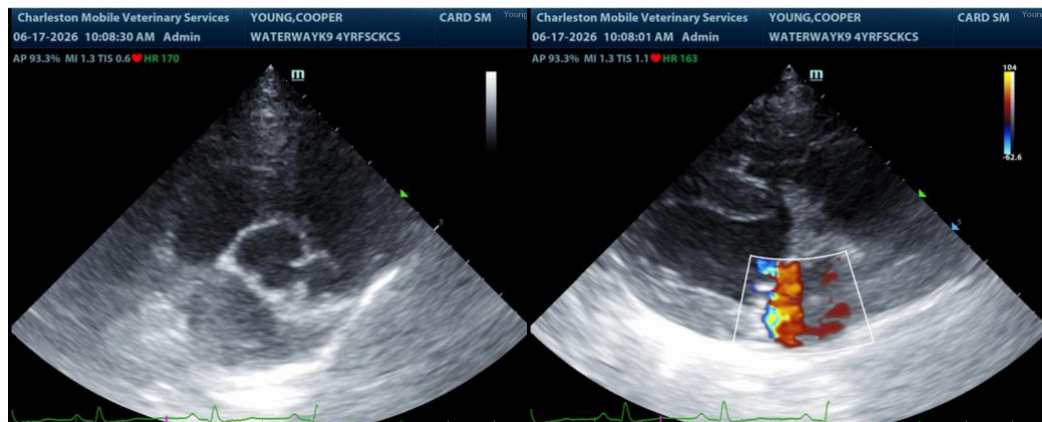
Dr. Roland

**INVOICE**

37570

**DATE**

6/17/26



**The information and recommendations provided are based on the images presented by the referring veterinarian/sonographer. No evaluation can be communicated regarding pathology that was not visible in the image/video clips provided.**

Thank you for this referral. If the clinical or image interpretation does not parallel your findings or if I can be of any further assistance please contact me.

Sara Brethel DVM, DACVIM (Cardiology)

[info@SonoPath.com](mailto:info@SonoPath.com)