



PATIENT

Charlie Gentry

SPECIES

Canine

BREED

Bichon X

SEX

Neutered Male

AGE

10 Years

WEIGHT

30.4 Pounds

INTERPRETED BY

Sara Brethel DVM,
 DACVIM (Cardiology)

IMAGING PERFORMED BY

Sara Hansen

HOSPITAL NAME

Animal Care Center

REFERRING VET

Dr. Rigling

INVOICE

37568

DATE

6/17/26

PRESENTING CLINICAL SIGNS

History: Clinical Exam Findings: Newly noted 3-4/6 left systolic heart murmur as of 5/28/26.
 ABNORMAL Labwork Values: no abnormalities noted on blood work. For ECHO Only: Blood Pressure will obtain day of echo. HR/RR/BP: will obtain day of echo. Is there a Heart Murmur? If so, please grade: 3-4/6 left systolic heart murmur. Current Medications: intermittent use of Apoquel 5.4mg, Claritin 1 tab SID. Radiographic Findings: no radiographs performed. Notes to Specialist (if any): Recommended echocardiogram prior to anesthesia.

ULTRASONOGRAPHIC EXAMINATION OF THE HEART

| CANINE CARDIAC PARAMETERS | MR VMAX (m/s) | TR VMAX (m/s) | LA/AO (M-Mode) | LA/AO (Heart Base; Swe) | FS (%) | EF (%) | EPSS (cm) |
|----------------------------------|----------------------|----------------------|-----------------------|--------------------------------|-----------------------------|---|---|
| NORMAL PARAMETER | 4.5-5.5 | <2.7 | 1.3 | Up to 1.6 | 28-40 | 40-100 | <0.6 |
| PATIENT | 5.96 | -- | 1.37 | 1.53 | 44 | -- | 0.15 |
| CANINE CARDIAC PARAMETERS | HR (BPM) | AV VMAX (m/s) | PV MAX (m/s) | BODY WEIGHT (kg) | LAD LA MAX 4 Chamber | LVIDd Avg; 2D and m-mode short axis (cm) | LVIDs Avg; 2D and m-mode short axis (cm) |
| NORMAL PARAMETER | 50-100 | 0.7-1.7 | 0.7-1.6 | | | | |
| PATIENT | -- | 1.61 | 1.15 | 13.8 | 3.5 | 3.0 | 1.68 |

ECG Interpretation

Normal sinus rhythm.

Cardiac Presentation

The mitral valve leaflets are mildly thickened with mild mitral regurgitation posteriorly directed. There is no prolapse of the mitral valve leaflets. The left atrial size is mildly increased. Left ventricular internal dimensions during diastole are within normal limits and systolic function is preserved in the face of mitral regurgitation. There is normal right atrial size without tricuspid regurgitation. There is no prolapse of the tricuspid valve leaflets and no evidence of pulmonary hypertension based upon tricuspid regurgitant velocities. The right ventricle subjectively appears normal in structure and function. The aortic and pulmonic valves have normal morphology, and the corresponding outflow velocities are within normal limits. There is no evidence of pulmonic or aortic insufficiency. The aorta appears normal. The pulmonary artery and associated branches appear normal. There is no evidence of pleural effusion, pericardial effusion, or intracardiac masses.



PATIENT

Charlie Gentry

SPECIES

Canine

BREED

Bichon X

SEX

Neutered Male

AGE

10 Years

WEIGHT

30.4 Pounds

INTERPRETED BY

Sara Brethel DVM,
 DACVIM (Cardiology)

IMAGING PERFORMED BY

Sara Hansen

HOSPITAL NAME

Animal Care Center

REFERRING VET

Dr. Rigling

INVOICE

37568

DATE

6/17/26

ULTRASONOGRAPHIC FINDINGS

- Degenerative valve disease, ACVIM stage B2
- Mild left atrial enlargement

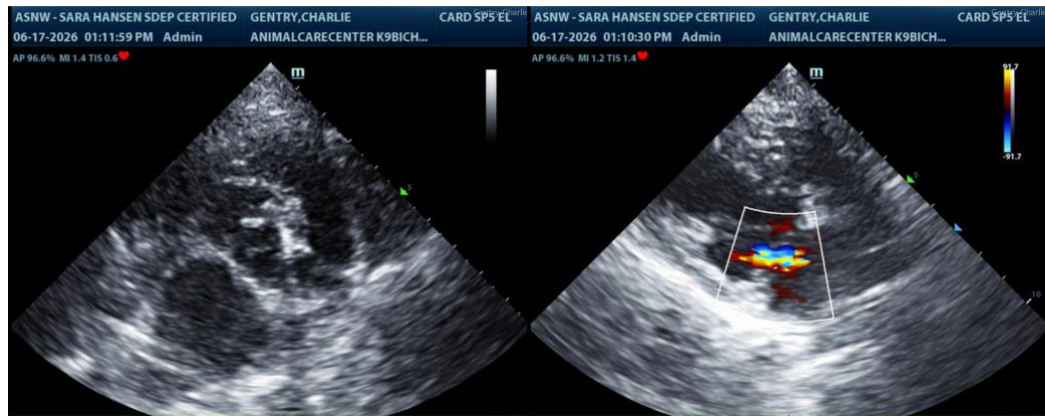
INTERPRETATION OF THE FINDINGS & FURTHER RECOMMENDATIONS

The patient has degenerative valve disease ACVIM stage B2 and pimobendan therapy at 0.27-0.32mg/kg PO q12 is recommended. This will be a lifelong therapy. A recheck echocardiogram is recommended in 4-6 months to monitor the condition since starting pimobendan. A sooner recheck is recommended if the patient develops cardiovascular clinical signs or the heart murmur is worsening in intensity. The client should start monitoring respiratory rate and effort at home if not already doing so. The resting respiratory rate should be < 35-40 breathes/minute when the patient is resting or sleeping. If the breathing rates are increasing, then chest radiographs are recommended.

Recommend obtaining a blood pressure on the patient to ensure it is <160mmHg. If the blood pressure is elevated recommend following ACVIM guidelines for systemic hypertension and treating if indicated.

Judicious perioperative fluids are recommended due to the increased left atrial size. Medications like dexmedetomidine and other alpha 2 agonists are best avoided. Ketamine is also best avoided. If needed, anticholinergics can be used in the face of a clinically significant bradyarrhythmia (i.e., bradycardia with concurrent hypotension). If the patient is on an ACEi, recommend not giving this therapy the day of anesthesia.

I would recommend that the patient be on pimobendan for 1 - 3 weeks prior to elective anesthetic procedures.





PATIENT

Charlie Gentry

SPECIES

Canine

BREED

Bichon X

SEX

Neutered Male

AGE

10 Years

WEIGHT

30.4 Pounds

INTERPRETED BY

Sara Brethel DVM,
DACVIM (Cardiology)

IMAGING PERFORMED BY

Sara Hansen

HOSPITAL NAME

Animal Care Center

REFERRING VET

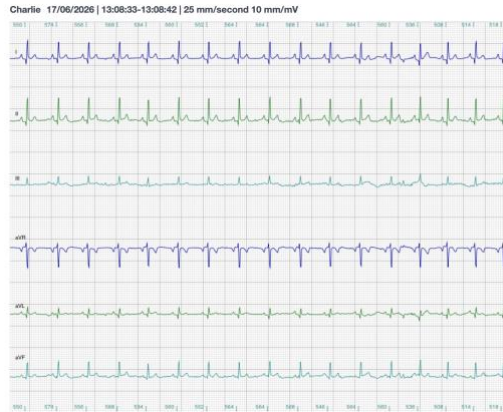
Dr. Rigling

INVOICE

37568

DATE

6/17/26



The information and recommendations provided are based on the images presented by the referring veterinarian/sonographer. No evaluation can be communicated regarding pathology that was not visible in the image/video clips provided.

Thank you for this referral. If the clinical or image interpretation does not parallel your findings or if I can be of any further assistance please contact me.

Sara Brethel DVM, DACVIM (Cardiology)

info@SonoPath.com