

PATIENT

Jojo Marturano

SPECIES

Canine

BREED

Australian Cattle Dog

SEX

Neutered Male

AGE

11 Years 7 Months

WEIGHT

50.6 lbs

INTERPRETED BY

Sara Brethel DVM,
 DACVIM (Cardiology)

PRESENTING CLINICAL SIGNS

BCS 6/9. Increased grade in heart murmur. Elevated Pro BNP. Grade III-IV/VI heart murmur, previously grade as II. Never had a full workup. Rest of exam unremarkable. No current medications.

Abnormal PE/Chem/CBC/UA Results: CPK 52; Chol 376; Creat 2.6; BUN 46; Cardio BNP 6.8 pg/ml. UA: PH 5.0; USG: 1.017

ULTRASONOGRAPHIC EXAMINATION OF THE HEART

CANINE CARDIAC PARAMETERS	MR VMAX (m/s)	TR VMAX (m/s)	LA/AO (M-Mode)	LA/AO (Heart Base; Swe)	FS (%)	EF (%)	EPSS (cm)
NORMAL PARAMETER	4.5-5.5	<2.7	1.3	Up to 1.6	28-40	40-100	<0.6
PATIENT	~6.0	~3.0	1.53	1.87	41.82	--	NM
CANINE CARDIAC PARAMETERS	HR (BPM)	AV VMAX (m/s)	PV MAX (m/s)	BODY WEIGHT (kg)	LAD LA MAX 4 Chamber	LVIDd Avg; 2D and m-mode short axis (cm)	LVIDs Avg; 2D and m-mode short axis (cm)
NORMAL PARAMETER	50-100	0.7-1.7	0.7-1.6				
PATIENT	138	1.43	0.84	23	4.9	4.4	2.56

IMAGING PERFORMED BY

Shari Reffi CVT

HOSPITAL NAME

Andover Animal Hospital

REFERRING VET

Dr. Lawlor

INVOICE

15927

DATE

05/07/26

Cardiac Presentation

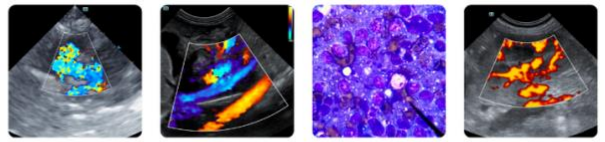
The mitral valve leaflets are moderately thickened with moderate mitral regurgitation posteriorly directed. There is moderate prolapse of the mitral valve leaflets. The left atrial size is mildly to moderately increased. Left ventricular internal dimensions during diastole are increased and systolic function is preserved in the face of mitral regurgitation. There is normal right atrial size with mild tricuspid regurgitation. There is no prolapse of the tricuspid valve leaflets and no evidence of pulmonary hypertension based upon tricuspid regurgitant velocities. The right ventricle subjectively appears normal in structure and function. The aortic and pulmonic valves have normal morphology and the corresponding outflow velocities are within normal limits. There is no evidence of pulmonic or aortic insufficiency. The aorta appears normal. The pulmonary artery and associated branches appear normal. There is no evidence of pleural effusion, pericardial effusion, or intracardiac masses.

ULTRASONOGRAPHIC FINDINGS

- Degenerative valve disease ACVIM stage B2.
- Mild tricuspid regurgitation without evidence of significant pulmonary hypertension.

INTERPRETATION OF THE FINDINGS & FURTHER RECOMMENDATIONS

The patient has degenerative valve disease ACVIM stage B2 and Pimobendan therapy at 0.27-



PATIENT
 Jojo Marturano

SPECIES
 Canine

BREED
 Australian Cattle Dog

0.32mg/kg PO q12 is recommended. This will be a lifelong therapy. A recheck echocardiogram is recommended in 4-6 months to monitor the condition since starting Pimobendan. A sooner recheck is recommended if the patient develops cardiovascular clinical signs or the heart murmur is worsening in intensity. The client should start monitoring respiratory rate and effort at home if not already doing so. The resting respiratory rate should be < 35-40 breathes/minute when the patient is resting or sleeping. If the breathing rates are increasing then chest radiographs are recommended.

Recommend obtaining a blood pressure on the patient to ensure it is <160mmHg. If the blood pressure is elevated recommend following ACVIM guidelines for systemic hypertension and treating if indicated.

SEX
 Neutered Male

AGE
 11 Years 7 Months

WEIGHT
 50.6 lbs

INTERPRETED BY
 Sara Brethel DVM,
 DACVIM (Cardiology)

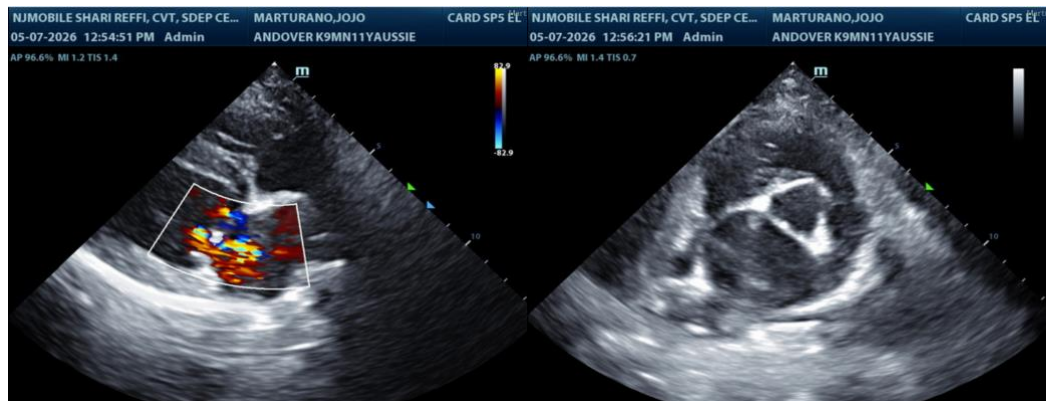
IMAGING PERFORMED BY
 Shari Reffi CVT

HOSPITAL NAME
 Andover Animal
 Hospital

REFERRING VET
 Dr. Lawlor

INVOICE
 15927

DATE
 05/07/26



The information and recommendations provided are based on the images presented by the referring veterinarian/sonographer. No evaluation can be communicated regarding pathology that was not visible in the image/video clips provided.

Thank you for this referral. If the clinical or image interpretation does not parallel your findings or if I can be of any further assistance please contact me.

Sara Brethel DVM, DACVIM (Cardiology)

info@SonoPath.com