



**PATIENT**

Ennis Miller

**SPECIES**

Feline

**BREED**

DLH

**SEX**

Spayed Female

**AGE**

14 Years

**WEIGHT**

4.39 kg

**INTERPRETED BY**

Sara Brethel DVM,  
 DACVIM (Cardiology)

**IMAGING PERFORMED BY**

Kelly Reschny

**HOSPITAL NAME**

Chippawa AH

**REFERRING VET**

Dr. Kilkenny

**INVOICE**

35965

**DATE**

5/6/26

**PRESENTING CLINICAL SIGNS**

History: Feline oral resorptive lesion present on physical exam  
 Echocardiogram prior to dental surgery due to grade 3/6 HM.

**ULTRASONOGRAPHIC EXAMINATION OF THE HEART**

FELINE CARDIAC PARAMETERS	BODY WEIGHT (kg)	HR (BPM)	IVSd (cm)	LVIDd (cm)	LVWd (cm)	FS (%)	EF (%)
<b>NORMAL PARAMETER</b>	-----	150-240	0.3-0.6	1.0-2.1	0.25-0.6	35-67	80-100
<b>PATIENT</b>	4.39	201	0.35	1.53	0.33	64.71	--
FELINE CARDIAC PARAMETERS	LA/AO (M-mode)	LA/AO HEART BASE (Sisson)	LAD LA MAX 4 Chamber		LVOT VEL. (m/s)	RVOT VEL. (m/s)	IVRT (m/)
<b>NORMAL PARAMETER</b>	<1.5	1.6	0.7-1.7		<1.6	<1.3	40-60
<b>PATIENT</b>	1.18	1.18	--		1.11	1.22	NM
Adapted from June Boon, Veterinary Echocardiography, 1998 Sisson D et al. JVIM 1991; 5: 232, Jacobs et al. Am J Vet Res 1985; 46:1705							

LVIDs: 0.54

**Cardiac Presentation**

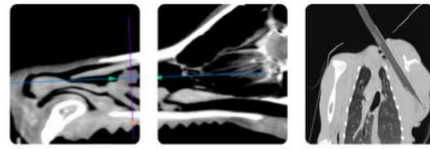
The mitral valve leaflets are normal and there is no mitral regurgitation. The left atrial size is normal. There is no evidence of systolic anterior motion of the mitral valve and no evidence of a left ventricular outflow tract obstruction. Left ventricular systolic and diastolic function is within normal limits. There is no evidence of left ventricular concentric hypertrophy. There is normal right atrial size without evidence of tricuspid regurgitation. There is no prolapse of the tricuspid valve leaflets and no evidence of pulmonary hypertension on the images provided. The right ventricle appears normal in structure and function subjectively. The aortic and pulmonic valves have normal morphology, and the corresponding outflow velocities are within normal limits. There is no evidence of pulmonic or aortic insufficiency. The aorta appears normal. The pulmonary artery and associated branches appear normal. There is no evidence of pleural effusion, pericardial effusion, or intracardiac masses.

**ULTRASONOGRAPHIC FINDINGS**

- Structurally normal heart

**INTERPRETATION OF THE FINDINGS & FURTHER RECOMMENDATIONS**

The heart is structurally normal. The heart murmur is likely innocent versus physiologic. No cardiac therapies are indicated at this time. No contraindications to IV fluids or general anesthesia. Can



**PATIENT**

Ennis Miller

**SPECIES**

Feline

**BREED**

DLH

**SEX**

Spayed Female

**AGE**

14 Years

**WEIGHT**

4.39 kg

**INTERPRETED BY**

Sara Brethel DVM,  
DACVIM (Cardiology)

**IMAGING  
PERFORMED BY**

Kelly Reschny

**HOSPITAL NAME**

Chippawa AH

**REFERRING VET**

Dr. Kilkenny

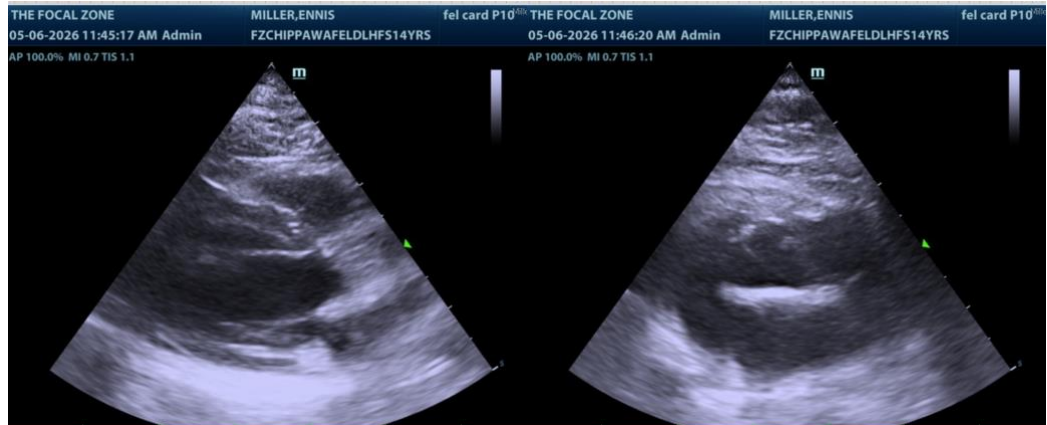
**INVOICE**

35965

**DATE**

5/6/26

consider a recheck echo in 10 - 12 months, alternatively, performing a proBNP in 10 - 12 months, sooner if the murmur changes and/or the patient develops an arrhythmia.



**The information and recommendations provided are based on the images presented by the referring veterinarian/sonographer. No evaluation can be communicated regarding pathology that was not visible in the image/video clips provided.**

Thank you for this referral. If the clinical or image interpretation does not parallel your findings or if I can be of any further assistance please contact me.

Sara Brethel DVM, DACVIM (Cardiology)

[info@SonoPath.com](mailto:info@SonoPath.com)