

**PATIENT**

Shaggy Wimmer

**SPECIES**

Canine

**BREED**

Old English Sheepdog

**SEX**

Intact Male

**AGE**

9 Years

**WEIGHT**

50 kg

**INTERPRETED BY**

Sara Brethel, DVM,  
DACVIM (Cardiology)

**IMAGING PERFORMED BY**

Kathleen Byrnes

**HOSPITAL NAME**

Midway Animal Clinic

**REFERRING VET**

Dr. Lakey

**INVOICE**

15800

**DATE**

05/05/26

**PRESENTING CLINICAL SIGNS**

P needs anesthesia for mass removal. Arrhythmia heard at last exam. No murmur or any clinical signs.

**ELECTROCARDIOGRAPHIC EXAMINATION**

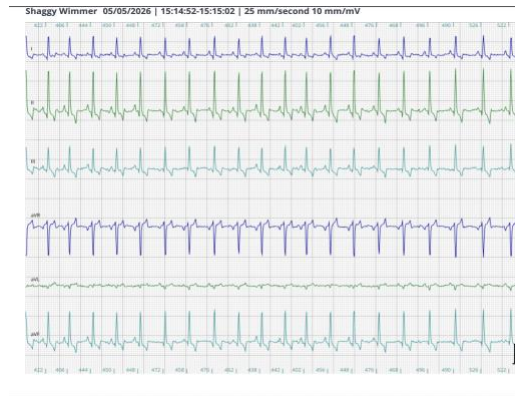
Sinus rhythm with a sinus arrhythmia and a wandering pacemaker.

**ELECTROCARDIOGRAPHIC FINDINGS**

- Sinus rhythm with a sinus arrhythmia and varying P wave morphology.

**INTERPRETATION OF THE FINDINGS & FURTHER RECOMMENDATIONS**

The patient has a normal ECG. Any other underlying structural cardiac disease cannot be ruled out without an echocardiogram. However, the ECG provided is within normal limits. To be cautious, I would recommend avoiding alpha-2 agonists and dexmedetomidine. Three view chest radiographs can be taken prior to anesthesia to evaluate the cardiac silhouette.



The information and recommendations provided are based on the images presented by the referring veterinarian/sonographer. No evaluation can be communicated regarding pathology that was not visible in the image/video clips provided.

Thank you for this referral. If the clinical or image interpretation does not parallel your findings or if I can be of any further assistance, please contact me.

Sara Brethel, DVM, DACVIM (Cardiology)

[info@SonoPath.com](mailto:info@SonoPath.com)