

PATIENT

Yuki Piquette

SPECIES

Canine

BREED

Cavalier King Charles
 Spaniel

SEX

Spayed Female

AGE

5 Years

WEIGHT

22.8 pounds

INTERPRETED BY

Sara Brethel DVM,
 DACVIM (Cardiology)

IMAGING PERFORMED BY

Sara Hansen

HOSPITAL NAME

VCA McKenzie Animal
 Hospital

REFERRING VET

Dr. Fricke

INVOICE

14950

DATE

04/08/26

PRESENTING CLINICAL SIGNS

Clinical Exam Findings: Presented for complaint of licking at her vulva. Heart murmur systolic grade 3/6, previously noted and diagnosed as Chronic degenerative mitral valve disease ACVIM stage B1 May 2025. Dental disease present. ABNORMAL Labwork Values: CBC, Chemistry normal. UA normal except pH 8.5 For ECHO Only: Blood Pressure: TBD. HR/RR/BP: 140/30/ TBD Is there a Heart Murmur? If so, please grade. 3/6 Current Medications: SP Cardiac Support

ULTRASONOGRAPHIC EXAMINATION OF THE HEART

CANINE CARDIAC PARAMETERS	MR VMAX (m/s)	TR VMAX (m/s)	LA/AO (M-Mode)	LA/AO (Heart Base; Swe)	FS (%)	EF (%)	EPSS (cm)
NORMAL PARAMETER	4.5-5.5	<2.7	1.3	Up to 1.6	28-40	40-100	<0.6
PATIENT	5.57	--	1.07	1.12	38.46	--	0.08
CANINE CARDIAC PARAMETERS	HR (BPM)	AV VMAX (m/s)	PV MAX (m/s)	BODY WEIGHT (kg)	LAD LA MAX 4 Chamber	LVIDd Avg; 2D and m-mode short axis (cm)	LVIDs Avg; 2D and m-mode short axis (cm)
NORMAL PARAMETER	50-100	0.7-1.7	0.7-1.6				
PATIENT	155	1.49	0.78	10.36	2.7	2.6	1.6

Cardiac Presentation

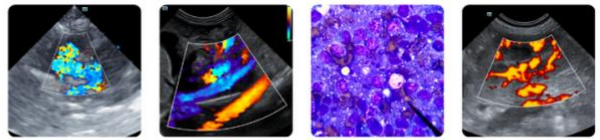
The mitral valve leaflets are mildly thickened with mild mitral regurgitation posteriorly directed. There is no prolapse of the mitral valve leaflets. The left atrial size is normal. Left ventricular internal dimensions during diastole are within normal limits and systolic function is preserved in the face of mitral regurgitation. There is normal right atrial size without tricuspid regurgitation. There is no prolapse of the tricuspid valve leaflets and no evidence of pulmonary hypertension based upon tricuspid regurgitant velocities. The right ventricle subjectively appears normal in structure and function. The aortic and pulmonic valves have normal morphology and the corresponding outflow velocities are within normal limits. There is no evidence of pulmonic or aortic insufficiency. The aorta appears normal. The pulmonary artery and associated branches appear normal. There is no evidence of pleural effusion, pericardial effusion, or intracardiac masses.

ECG

Normal sinus rhythm.

ULTRASONOGRAPHIC FINDINGS

- Degenerative valve disease ACVIM stage B1.
- Normal sinus rhythm.



PATIENT

Yuki Piquette

SPECIES

Canine

BREED

Cavalier King Charles
 Spaniel

SEX

Spayed Female

AGE

5 Years

WEIGHT

22.8 pounds

INTERPRETED BY

Sara Brethel DVM,
 DACVIM (Cardiology)

IMAGING PERFORMED BY

Sara Hansen

HOSPITAL NAME

VCA McKenzie Animal
 Hospital

REFERRING VET

Dr. Fricke

INVOICE

14950

DATE

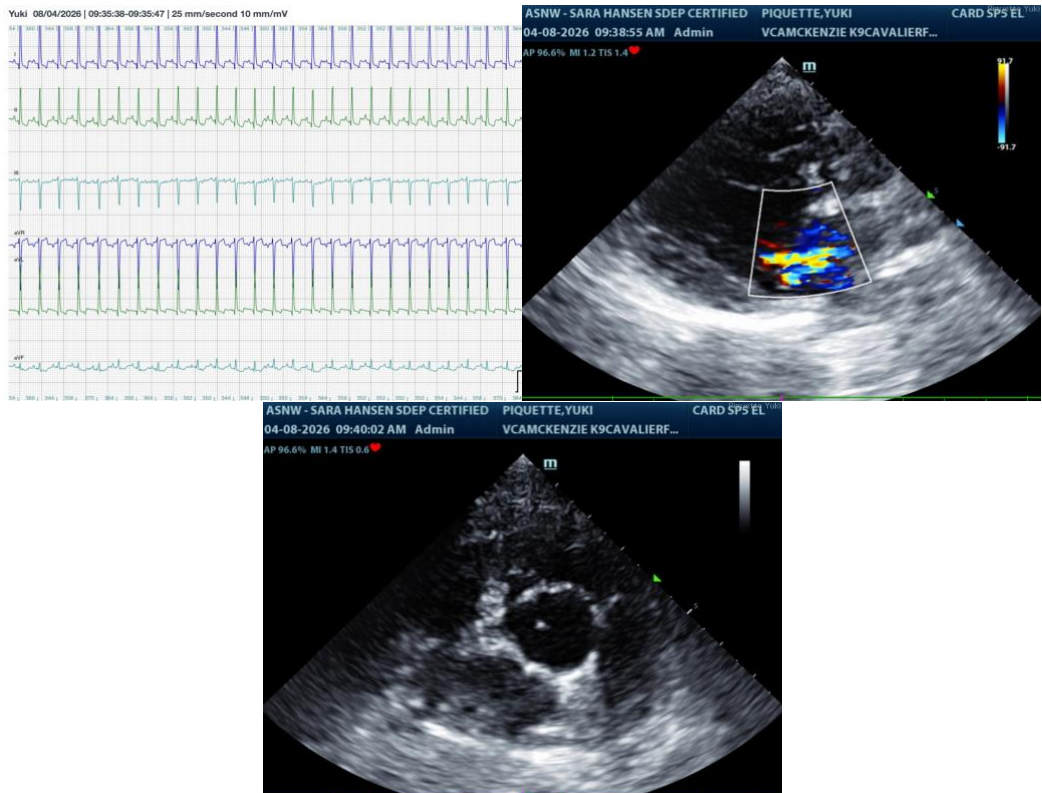
04/08/26

INTERPRETATION OF THE FINDINGS & FURTHER RECOMMENDATIONS

The patient has degenerative valve disease ACVIM stage B1 and no cardiac medications are indicated at this time. Since this can be a progressive condition, serial monitoring is recommended. A recheck echocardiogram is recommended in 10-12 months. A sooner recheck is recommended if the patient develops cardiovascular clinical signs or the heart murmur is worsening in intensity. Elective anesthetic procedures should be well tolerated.

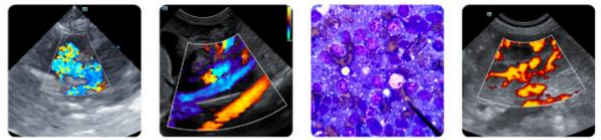
Recommend obtaining a blood pressure on the patient to ensure it is <160mmHg. If the blood pressure is elevated recommend following ACVIM guidelines for systemic hypertension and treating if indicated.

Standard perioperative fluid rates should be well-tolerated. Medications like dexmedetomidine and other alpha 2 agonists are best avoided. Ketamine is also best avoided. Anticholinergics can be used in the case of a clinically significant bradyarrhythmia (i.e., bradycardia with concurrent hypotension). If the patient is on an ACEi, recommend not giving this therapy the day of anesthesia.



The information and recommendations provided are based on the images presented by the referring veterinarian/sonographer. No evaluation can be communicated regarding pathology that was not visible in the image/video clips provided.

Thank you for this referral. If the clinical or image interpretation does not parallel your findings or if I



PATIENT

Yuki Piquette

can be of any further assistance please contact me.

Sara Brethel DVM, DACVIM (Cardiology)

SPECIES

Canine

info@SonoPath.com

BREED

Cavalier King Charles
Spaniel

SEX

Spayed Female

AGE

5 Years

WEIGHT

22.8 pounds

INTERPRETED BY

Sara Brethel DVM,
DACVIM (Cardiology)

**IMAGING
PERFORMED BY**

Sara Hansen

HOSPITAL NAME

VCA Mckenzie Animal
Hospital

REFERRING VET

Dr. Fricke

INVOICE

14950

DATE

04/08/26