



PATIENT

Boo Todd

PRESENTING CLINICAL SIGNS

History: P presented for echo due to elevated proBNP on bloodwork. No murmur heard.

SPECIES

Feline

BREED

DSH

SEX

Spayed Female

AGE

6 Years 3 Months

WEIGHT

15.8 Pounds

ULTRASONOGRAPHIC EXAMINATION OF THE HEART

FELINE CARDIAC PARAMETERS	BODY WEIGHT (kg)	HR (BPM)	IVSd (cm)	LVIDd (cm)	LVWd (cm)	FS (%)	EF (%)
NORMAL PARAMETER	-----	150-240	0.3-0.6	1.0-2.1	0.25-0.6	35-67	80-100
PATIENT	7.18	NM	0.46	1.17	0.51	--	--
FELINE CARDIAC PARAMETERS	LA/AO (M-mode)	LA/AO HEART BASE (Sisson)	LAD LA MAX 4 Chamber		LVOT VEL. (m/s)	RVOT VEL. (m/s)	IVRT (m/)
NORMAL PARAMETER	<1.5	1.6	0.7-1.7		<1.6	<1.3	40-60
PATIENT	NM	1.42	NM		1.21	1.21	NM

Adapted from June Boon, Veterinary Echocardiography, 1998
 Sisson D et al. JVIM 1991; 5: 232, Jacobs et al. Am J Vet Res 1985; 46:1705

INTERPRETED BY

Sara Brethel, DVM,
 DACVIM (Cardiology)

Cardiac Presentation

The mitral valve leaflets are normal and there is no mitral regurgitation. The left atrial size is normal. There is no evidence of systolic anterior motion of the mitral valve and no evidence of a left ventricular outflow tract obstruction. Left ventricular systolic and diastolic function is within normal limits. There is no evidence of left ventricular concentric hypertrophy. There is normal right atrial size without evidence of tricuspid regurgitation. There is no prolapse of the tricuspid valve leaflets and no evidence of pulmonary hypertension on the images provided. The right ventricle appears normal in structure and function subjectively. The aortic and pulmonic valves have normal morphology and the corresponding outflow velocities are within normal limits. There is no evidence of pulmonic or aortic insufficiency. The aorta appears normal. The pulmonary artery and associated branches appear normal. There is no evidence of pleural effusion, pericardial effusion, or intracardiac masses.

IMAGING PERFORMED BY

Kathleen Byrnes

HOSPITAL NAME

Harmony Heights AH

REFERRING VET

Dr. Sechrist

INVOICE

35893

DATE

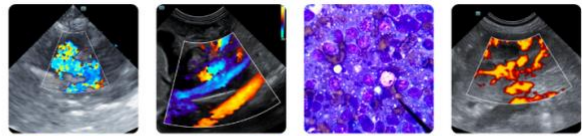
4/30/26

ULTRASONOGRAPHIC FINDINGS

- Structurally normal heart

INTERPRETATION OF THE FINDINGS & FURTHER RECOMMENDATIONS

The heart is structurally normal. The cause for the patient's elevated proBNP is unknown. With the history of the ProBNP being increased, can recheck an echo in a year. No cardiac therapies are recommended.



PATIENT

Boo Todd

SPECIES

Feline

BREED

DSH

SEX

Spayed Female

AGE

6 Years 3 Months

WEIGHT

15.8 Pounds

INTERPRETED BY

Sara Brethel, DVM,
DACVIM (Cardiology)

IMAGING PERFORMED BY

Kathleen Byrnes

HOSPITAL NAME

Harmony Heights AH

REFERRING VET

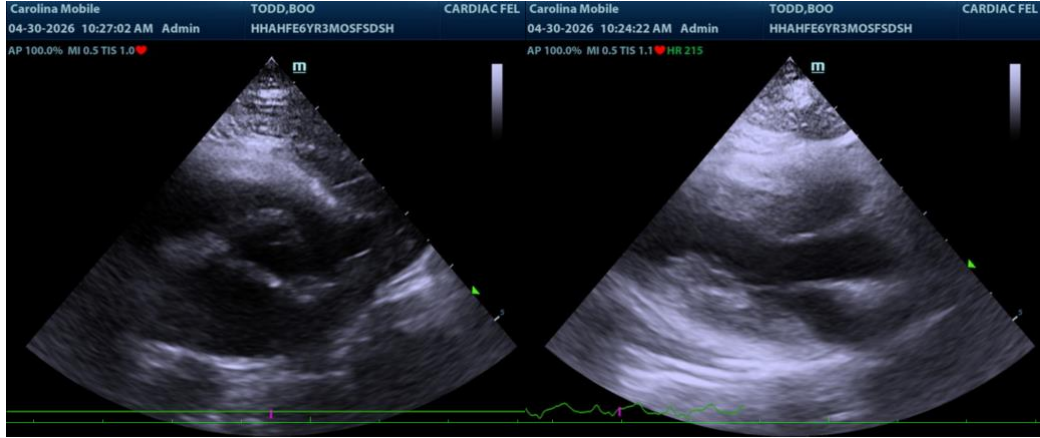
Dr. Sechrist

INVOICE

35893

DATE

4/30/26



The information and recommendations provided are based on the images presented by the referring veterinarian/sonographer. No evaluation can be communicated regarding pathology that was not visible in the image/video clips provided.

Thank you for this referral. If the clinical or image interpretation does not parallel your findings or if I can be of any further assistance please contact me.

Sara Brethel DVM, DACVIM (Cardiology)

info@SonoPath.com