



PATIENT

Oscar Hall

SPECIES

Feline

BREED

DSH

SEX

Neutered Male

AGE

7 Years 11 Months

WEIGHT

11.3 Pounds

INTERPRETED BY

Sara Brethel, DVM,
 DACVIM (Cardiology)

IMAGING PERFORMED BY

Kathleen Byrnes

HOSPITAL NAME

Pet Care Clinic of the
 High Country

REFERRING VET

Dr. Sturgill

INVOICE

36880

DATE

4/30/26

PRESENTING CLINICAL SIGNS

History: P presented for echo due to new murmur and elevated pro BNP
 Please comment on anesthesia for dental cleaning.

ULTRASONOGRAPHIC EXAMINATION OF THE HEART

FELINE CARDIAC PARAMETERS	BODY WEIGHT (kg)	HR (BPM)	IVSd (cm)	LVIDd (cm)	LVWd (cm)	FS (%)	EF (%)
NORMAL PARAMETER	-----	150-240	0.3-0.6	1.0-2.1	0.25-0.6	35-67	80-100
PATIENT	5.13	NM	0.61	1.05	0.5	--	--
FELINE CARDIAC PARAMETERS	LA/AO (M-mode)	LA/AO HEART BASE (Sisson)	LAD LA MAX 4 Chamber		LVOT VEL. (m/s)	RVOT VEL. (m/s)	IVRT (m/)
NORMAL PARAMETER	<1.5	1.6	0.7-1.7		<1.6	<1.3	40-60
PATIENT	--	1.28	NM		~3.0	0.89	NM
Adapted from June Boon, Veterinary Echocardiography, 1998 Sisson D et al. JVIM 1991; 5: 232, Jacobs et al. Am J Vet Res 1985; 46:1705							

MR Vmax: 5.08

Cardiac Presentation

The mitral valve leaflets are normal and there is mild mitral regurgitation. There is no prolapse of the mitral valve leaflets. The left atrial size is within normal limits. Left ventricular systolic function appears preserved. Left ventricular diastolic dimensions are within normal limits. There is evidence of systolic anterior motion of the mitral valve and there is a discrete step up in velocities through the left ventricular outflow tract. There is evidence of a kissing lesion at the level of SAM, and the left ventricular myocardium appears hyperechoic in some regions. Left ventricular walls measure hypertrophied. There is normal right atrial size without evidence of tricuspid regurgitation. There is no prolapse of the tricuspid valve leaflets and no evidence of pulmonary hypertension on the images provided. The right ventricle appears normal in structure and function subjectively. The aortic and pulmonic valves have normal morphology and the corresponding outflow velocities are within normal limits. There is no evidence of pulmonic or aortic insufficiency. The aorta appears normal. The pulmonary artery and associated branches appear normal. There is no evidence of pleural effusion, pericardial effusion, or intracardiac masses.

ULTRASONOGRAPHIC FINDINGS

- Hypertrophic obstructive cardiomyopathy
- Normal left atrial size, assessment



PATIENT

Oscar Hall

SPECIES

Feline

BREED

DSH

SEX

Neutered Male

AGE

7 Years 11 Months

WEIGHT

11.3 Pounds

INTERPRETED BY

Sara Brethel, DVM,
 DACVIM (Cardiology)

IMAGING PERFORMED BY

Kathleen Byrnes

HOSPITAL NAME

Pet Care Clinic of the
 High Country

REFERRING VET

Dr. Sturgill

INVOICE

36880

DATE

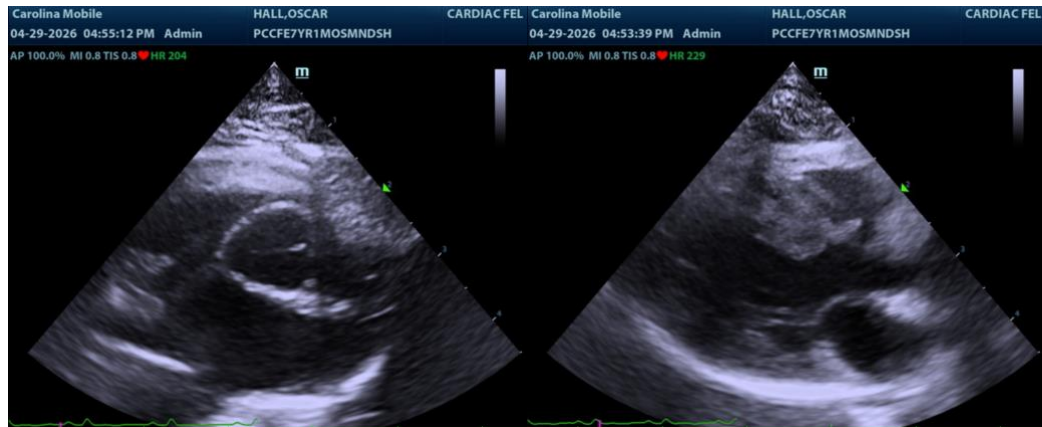
4/30/26

INTERPRETATION OF THE FINDINGS & FURTHER RECOMMENDATIONS

The patient has evidence of left ventricular concentric hypertrophy and is classified as a stage B1 due to the normal left atrial size. If not already performed, it is recommended to ensure that patients blood pressure is normal, and the patient is euthyroid. If the patient is euthyroid and normotensive, then the patient has underlying hypertrophic cardiomyopathy. No cardiac medications are indicated at this time as the patient is at a low risk for complications associated with this condition. Since this can be a progressive condition, serial monitoring is recommended. It's recommended to recheck an echocardiogram in 6 months, sooner if the patient develops cardiovascular clinical signs.

Recommend obtaining a blood pressure on the patient to ensure it is <160mmHg. If the blood pressure is elevated recommend following ACVIM guidelines for systemic hypertension and treating if indicated.

Standard perioperative fluid rates should be well-tolerated. Medications like dexmedetomidine and other alpha 2 agonists are best avoided. Ketamine is also best avoided. Anticholinergics can be used in the case of a clinically significant bradyarrhythmia (i.e., bradycardia with concurrent hypotension). If the patient is on an ACEi, recommend not giving this therapy the day of anesthesia.



The information and recommendations provided are based on the images presented by the referring veterinarian/sonographer. No evaluation can be communicated regarding pathology that was not visible in the image/video clips provided.

Thank you for this referral. If the clinical or image interpretation does not parallel your findings or if I can be of any further assistance please contact me.

Sara Brethel DVM, DACVIM (Cardiology)

info@SonoPath.com