



PATIENT

Gucci Altekreeti

SPECIES

Canine

BREED

Miniature Poodle Mix

SEX

Neutered Male

AGE

14 Years

WEIGHT

6.4 Pounds

INTERPRETED BY

Sara Brethel, DVM,
DACVIM (Cardiology)

IMAGING PERFORMED BY

Dr. Ryan Leal

HOSPITAL NAME

Wellesley AH

REFERRING VET

Dr. Lindsey Elswick

INVOICE

36858

DATE

4/28/26

PRESENTING CLINICAL SIGNS

History: Pt presents for echocardiogram prior to COHAT. Pt is otherwise doing well at home. Heart murmur first noticed in 2025. Medications: None

Abnormal PE/Chem/CBC/UA Results: PE: BCS 5/9, 4/6 left systolic murmur, significant dental disease, systemic alopecia and thin hair coat Labwork: None Blood Pressure: Doppler 185; Osscilometric 170/113 (127).

ULTRASONOGRAPHIC EXAMINATION OF THE HEART

CANINE CARDIAC PARAMETERS	MR VMAX (m/s)	TR VMAX (m/s)	LA/AO (M-Mode)	LA/AO (Heart Base; Swe)	FS (%)	EF (%)	EPSS (cm)
NORMAL PARAMETER	4.5-5.5	<2.7	1.3	Up to 1.6	28-40	40-100	<0.6
PATIENT	~6.0	Underest.	NM	2.29	61.8	--	NM
CANINE CARDIAC PARAMETERS	HR (BPM)	AV VMAX (m/s)	PV MAX (m/s)	BODY WEIGHT (kg)	LAD LA MAX 4 Chamber	LVIDd Avg; 2D and m-mode short axis (cm)	LVIDs Avg; 2D and m-mode short axis (cm)
NORMAL PARAMETER	50-100	0.7-1.7	0.7-1.6				
PATIENT	NM	0.9	0.8	2.9	2.64	2.33	0.89

Cardiac Presentation

The mitral valve leaflets are moderately thickened with moderate mitral regurgitation posteriorly directed. There is billowing of the mitral valve leaflets. The left atrial size is severely increased. There is a distention of the left ventricular dimensions and systolic function is preserved in the face of mitral regurgitation. There is normal right atrial size with mild tricuspid regurgitation. There is no prolapse of the tricuspid valve leaflets. The right ventricle subjectively appears normal in structure and function. The aortic and pulmonic valves have normal morphology and the corresponding outflow velocities are within normal limits. There is no evidence of pulmonic or aortic insufficiency. The aorta appears normal. The pulmonary artery and associated branches appear normal. There is no evidence of pleural effusion, pericardial effusion, or intracardiac masses.

ULTRASONOGRAPHIC FINDINGS

- Degenerative valve disease, ACVIM stage B-2
- Severe left atrial enlargement
- Mild degeneration of the tricuspid valve



PATIENT

Gucci Altekreeti

SPECIES

Canine

BREED

Miniature Poodle Mix

SEX

Neutered Male

AGE

14 Years

WEIGHT

6.4 Pounds

INTERPRETED BY

Sara Brethel, DVM,
DACVIM (Cardiology)

IMAGING PERFORMED BY

Dr. Ryan Leal

HOSPITAL NAME

Wellesley AH

REFERRING VET

Dr. Lindsey Elswick

INVOICE

36858

DATE

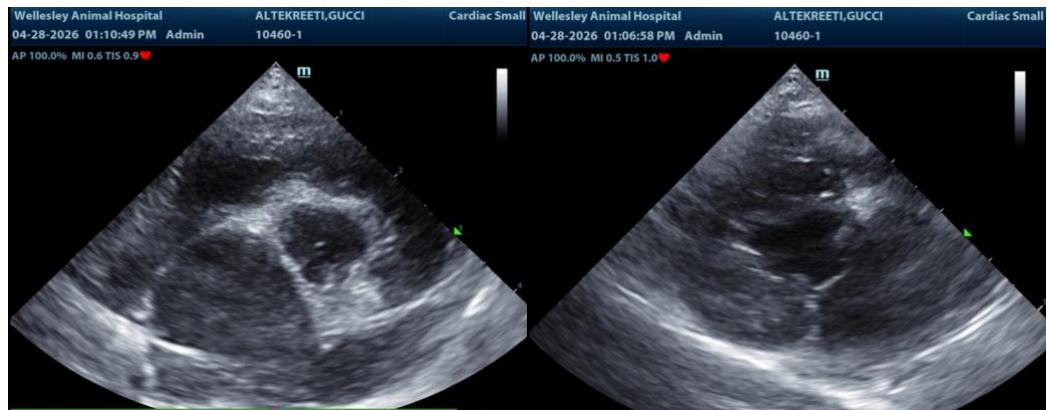
4/28/26

INTERPRETATION OF THE FINDINGS & FURTHER RECOMMENDATIONS

The patient has degenerative valve disease ACVIM stage B2 and pimobendan therapy at 0.27-0.32mg/kg PO q12 is recommended. This will be a lifelong therapy. A recheck echocardiogram is recommended in 4-6 months to monitor the condition since starting pimobendan. A sooner recheck is recommended if the patient develops cardiovascular clinical signs or the heart murmur is worsening in intensity. The client should start monitoring respiratory rate and effort at home if not already doing so. The resting respiratory rate should be < 35-40 breathes/minute when the patient is resting or sleeping. If the breathing rates are increasing, then chest radiographs are recommended.

The blood pressure reported is increased and it's recommended to ensure this value does not represent systemic hypertension. Recommend following ACVIM guidelines for systemic hypertension and treating if indicated with either ace inhibitors, amlodipine, or a combination of the two therapies.

The patient is at an increased risk for elective anesthetic procedures. Due to the severity of the left atrial enlargement, ideally, the patient would be on pimobendan therapy for at least 1-3 weeks prior to elective procedures. Judicious perioperative fluids are recommended due to the increased left atrial size. Medications like dexmedetomidine and other alpha 2 agonists are best avoided. Ketamine is also best avoided. If needed, anticholinergics can be used in the face of a clinically significant bradyarrhythmia (i.e., bradycardia with concurrent hypotension). If the patient is on an ACEi, recommend not giving this therapy the day of anesthesia.



The information and recommendations provided are based on the images presented by the referring veterinarian/sonographer. No evaluation can be communicated regarding pathology that was not visible in the image/video clips provided.

Thank you for this referral. If the clinical or image interpretation does not parallel your findings or if I can be of any further assistance please contact me.

Sara Brethel DVM, DACVIM (Cardiology)

info@SonoPath.com