

**PATIENT**

Giselle Fortune

**SPECIES**

Canine

**BREED**

Shetland Sheepdog

**SEX**

Spayed Female

**AGE**

11 Years

**WEIGHT**

23.5 pounds

**INTERPRETED BY**

Sara Brethel DVM,  
DACVIM (Cardiology)

**IMAGING PERFORMED BY**

Sara Hansen

**HOSPITAL NAME**

Q Street Animal  
Hospital

**REFERRING VET**

Dr. Hoerauf

**INVOICE**

15395

**DATE**

04/23/26

**PRESENTING CLINICAL SIGNS**

Clinical Exam Findings: Collapse or seizure episode occurred on 3/30/26. Event was not observed, but Giselle was under the bed, unable to get out and causing quite a disturbance. Afterward, she was unable to stand for about 30 minutes. She has seemed relatively normal since that time, but within the last few days, has had lower energy, slightly pale mucous membranes and increased respiratory rate and effort. Grade 4/6 systolic murmur present. **ABNORMAL** Labwork Values BW from 3/30 abnormalities: MCV 60.9, MCHC 38.4, Platelets 615, plateletcrit 0.58%, ALT 182, ALP 425, Cholesterol 420. For ECHO Only: Blood Pressure Will check on morning of appt. HR/RR/BP: 120/pant Is there a Heart Murmur? If so, please grade. 4/6 Current Medications None

**ULTRASONOGRAPHIC EXAMINATION OF THE HEART**

CANINE CARDIAC PARAMETERS	MR VMAX (m/s)	TR VMAX (m/s)	LA/AO (M-Mode)	LA/AO (Heart Base; Swe)	FS (%)	EF (%)	EPSS (cm)
NORMAL PARAMETER	4.5-5.5	<2.7	1.3	Up to 1.6	28-40	40-100	<0.6
PATIENT	6.65	--	1.28	1.68	57.31	--	NM
CANINE CARDIAC PARAMETERS	HR (BPM)	AV VMAX (m/s)	PV MAX (m/s)	BODY WEIGHT (kg)	LAD LA MAX 4 Chamber	LVIDd Avg; 2D and m-mode short axis (cm)	LVIDs Avg; 2D and m-mode short axis (cm)
NORMAL PARAMETER	50-100	0.7-1.7	0.7-1.6				
PATIENT	NM	1.31	0.83	10.68	3.76	3.35	1.43

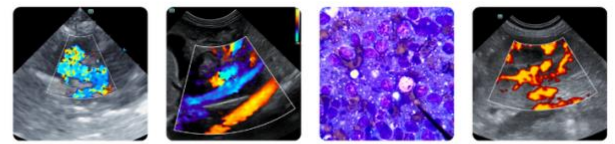
**Cardiac Presentation**

The mitral valve leaflets are mildly thickened with mild mitral regurgitation posteriorly directed. There is **no** prolapse of the mitral valve leaflets. The left atrial size is mildly increased. Left ventricular internal dimensions during diastole are within normal limits and systolic function is preserved in the face of mitral regurgitation. There is normal right atrial size without tricuspid regurgitation. There is no prolapse of the tricuspid valve leaflets and no evidence of pulmonary hypertension based upon tricuspid regurgitant velocities. The right ventricle subjectively appears normal in structure and function. The aortic and pulmonic valves have normal morphology and the corresponding outflow velocities are within normal limits. There is no evidence of pulmonic or aortic insufficiency. The aorta appears normal. The pulmonary artery and associated branches appear normal. There is no evidence of pleural effusion, pericardial effusion, or intracardiac masses.

**ECG**

Normal sinus rhythm.

**ULTRASONOGRAPHIC FINDINGS**



**PATIENT**

- Degenerative valve disease ACVIM stage B2.

Giselle Fortune

**INTERPRETATION OF THE FINDINGS & FURTHER RECOMMENDATIONS**

**SPECIES**

The patient has degenerative valve disease ACVIM stage B2 and Pimobendan therapy at 0.27-0.32mg/kg PO q12 is recommended. This will be a lifelong therapy. A recheck echocardiogram is recommended in 4-6 months to monitor the condition since starting Pimobendan. A sooner recheck is recommended if the patient develops cardiovascular clinical signs or the heart murmur is worsening in intensity. The client should start monitoring respiratory rate and effort at home if not already doing so. The resting respiratory rate should be < 35-40 breathes/minute when the patient is resting or sleeping. If the breathing rates are increasing then chest radiographs are recommended.

Canine

**BREED**

Shetland Sheepdog

**SEX**

Spayed Female

**AGE**

11 Years

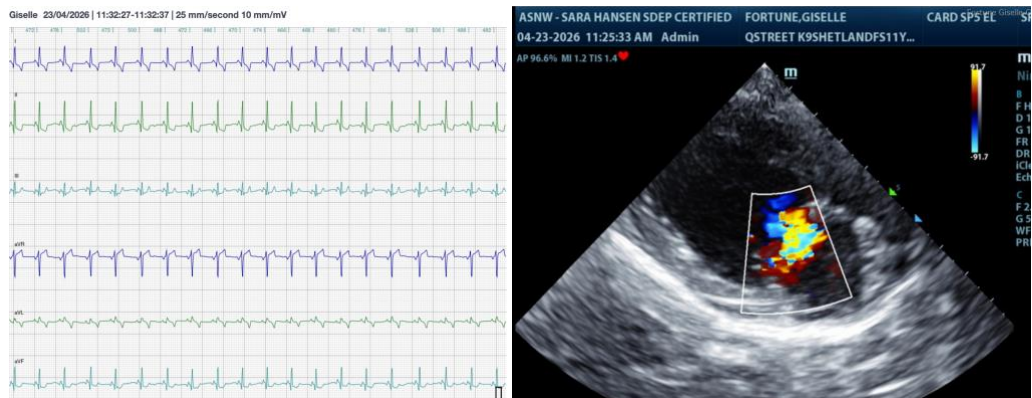The cause of the patient's collapse episode is not identified based upon the images provided. Given the description, I'm more concerned for neurologic or vascular episode. Can consider performing a Holter monitor despite the normal ECG. While there is mild left atrial enlargement, there does not appear to be evidence of decompensation into congestive heart failure. Can consider additional diagnostics such as an abdominal ultrasound and three view chest radiographs.

**WEIGHT**

23.5 pounds

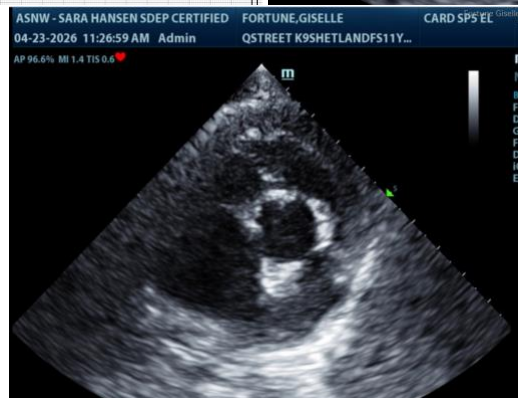
**INTERPRETED BY**

Sara Brethel DVM,  
 DACVIM (Cardiology)



**IMAGING PERFORMED BY**

Sara Hansen



**HOSPITAL NAME**

Q Street Animal Hospital

**REFERRING VET**

Dr. Hoerauf

**INVOICE**

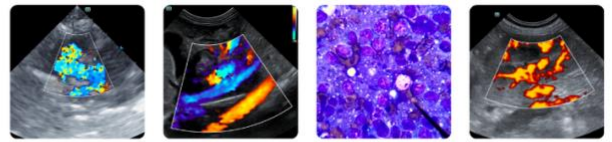
15395

**DATE**

04/23/26

The information and recommendations provided are based on the images presented by the referring veterinarian/sonographer. No evaluation can be communicated regarding pathology that was not visible in the image/video clips provided.

Thank you for this referral. If the clinical or image interpretation does not parallel your findings or if I



**PATIENT**

Giselle Fortune

can be of any further assistance please contact me.

Sara Brethel DVM, DACVIM (Cardiology)

**SPECIES**

Canine

[info@SonoPath.com](mailto:info@SonoPath.com)

**BREED**

Shetland Sheepdog

**SEX**

Spayed Female

**AGE**

11 Years

**WEIGHT**

23.5 pounds

**INTERPRETED BY**

Sara Brethel DVM,  
DACVIM (Cardiology)

**IMAGING PERFORMED BY**

Sara Hansen

**HOSPITAL NAME**

Q Street Animal  
Hospital

**REFERRING VET**

Dr. Hoerauf

**INVOICE**

15395

**DATE**

04/23/26