

PATIENT

Garcia Perkins

SPECIES

Feline

BREED

DSH

SEX

Spayed Female

AGE

9 Years

WEIGHT

8.4 pounds

INTERPRETED BY

Sara Brethel DVM,
 DACVIM (Cardiology)

IMAGING PERFORMED BY

Kathleen Byrnes

HOSPITAL NAME

Animal Hospital of
 Lewisville

REFERRING VET

Dr. Journell

INVOICE

15116

DATE

04/14/26

PRESENTING CLINICAL SIGNS

P presented for echo due to murmur that fluctuates from 1-4/6. concerned for physiologic murmur vs other, ProBNP also elevated

ULTRASONOGRAPHIC EXAMINATION OF THE HEART

FELINE CARDIAC PARAMETERS	BODY WEIGHT (kg)	HR (BPM)	IVSd (cm)	LVIDd (cm)	LVWd (cm)	FS (%)	EF (%)
NORMAL PARAMETER	-----	150-240	0.3-0.6	1.0-2.1	0.25-0.6	35-67	80-100
PATIENT	3.8	152	0.52	1.04	0.5	40.38	--
FELINE CARDIAC PARAMETERS	LA/AO (M-mode)	LA/AO HEART BASE (Sisson)	LAD LA MAX 4 Chamber	LVOT VEL. (m/s)	RVOT VEL. (m/s)	LVIDs (m/s)	
NORMAL PARAMETER	<1.5	1.6	0.7-1.7	<1.6	<1.3		
PATIENT	1.52	1.34	--	0.9	1.37	0.62	

Adapted from June Boon, Veterinary Echocardiography, 1998
 Sisson D et al. JVIM 1991; 5: 232, Jacobs et al. Am J Vet Res 1985; 46:1705

MR: 7.72

Cardiac Presentation

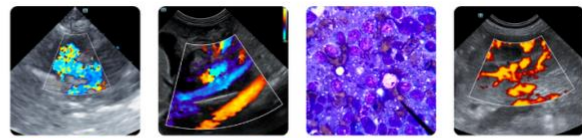
The mitral valve leaflets are normal and there is mild mitral regurgitation along the free wall. The left atrial size is normal. There is evidence of systolic anterior motion of the mitral valve and no evidence of a left ventricular outflow tract obstruction. Left ventricular systolic and diastolic function is within normal limits. There is no evidence of left ventricular concentric hypertrophy. There is normal right atrial size without evidence of tricuspid regurgitation. There is no prolapse of the tricuspid valve leaflets and no evidence of pulmonary hypertension on the images provided. The right ventricle appears normal in structure and function subjectively. The aortic and pulmonic valves have normal morphology and the corresponding outflow velocities are within normal limits. There is no evidence of pulmonic or aortic insufficiency. The aorta appears normal. The pulmonary artery and associated branches appear normal. There is no evidence of pleural effusion, pericardial effusion, or intracardiac masses.

ECG

Sinus rhythm with sinus bradycardia.

ULTRASONOGRAPHIC FINDINGS

- Mild mitral regurgitation.
- Normal sinus rhythm.
- Normal left atrial size.



PATIENT

Garcia Perkins

SPECIES

Feline

BREED

DSH

SEX

Spayed Female

AGE

9 Years

WEIGHT

8.4 pounds

INTERPRETED BY

Sara Brethel DVM,
 DACVIM (Cardiology)

IMAGING PERFORMED BY

Kathleen Byrnes

HOSPITAL NAME

Animal Hospital of
 Lewisville

REFERRING VET

Dr. Journell

INVOICE

15116

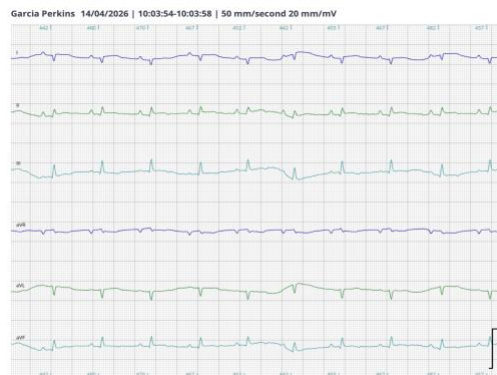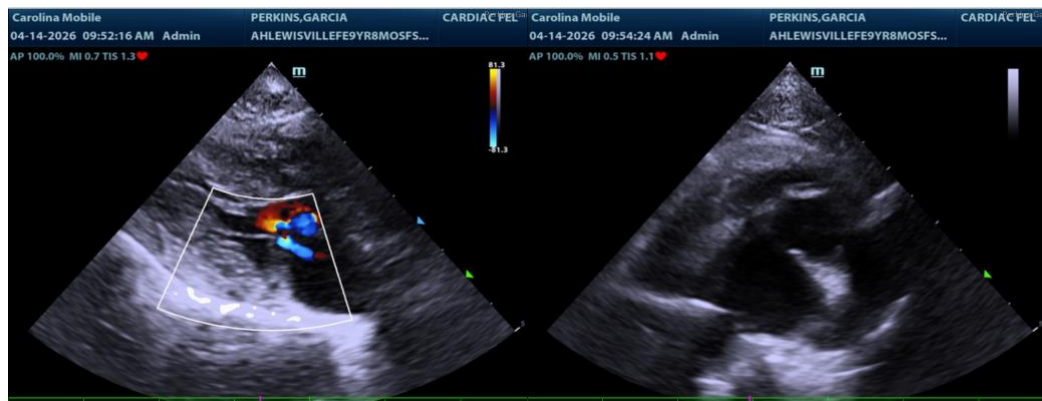
DATE

04/14/26

INTERPRETATION OF THE FINDINGS & FURTHER RECOMMENDATIONS

The patient has mild mitral regurgitation. This is the source of the murmur. The left atrial size is normal. No cardiac therapies are indicated at this time. The patient's rhythm is sinus, however considered lower for a cat in the clinic. If the patient did not receive sedation, recommend monitoring the rhythm and rechecking an electrocardiogram in 4-6 months. If the patient was sedated, then a recheck echocardiogram is recommended in 10-12 months, sooner, if the patient is developing cardiovascular clinical signs.

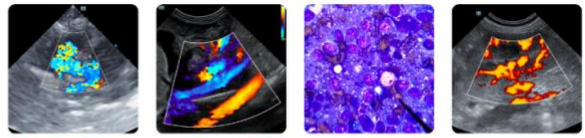
Recommend ensuring the patient is euthyroid and normotensive. If needed, elective anesthetic procedures should be well tolerated. Standard perioperative fluid rates should be well-tolerated. Medications like dexmedetomidine and other alpha 2 agonists are best avoided. Ketamine is also best avoided. Anticholinergics can be used in the case of a clinically significant bradyarrhythmia (i.e., bradycardia with concurrent hypotension). If the patient is on an ACEi, recommend not giving this therapy the day of anesthesia.



The information and recommendations provided are based on the images presented by the referring veterinarian/sonographer. No evaluation can be communicated regarding pathology that was not visible in the image/video clips provided.

Thank you for this referral. If the clinical or image interpretation does not parallel your findings or if I can be of any further assistance please contact me.

Sara Brethel DVM, DACVIM (Cardiology)



PATIENT

info@SonoPath.com

Garcia Perkins

SPECIES

Feline

BREED

DSH

SEX

Spayed Female

AGE

9 Years

WEIGHT

8.4 pounds

INTERPRETED BY

Sara Brethel DVM,
DACVIM (Cardiology)

**IMAGING
PERFORMED BY**

Kathleen Byrnes

HOSPITAL NAME

Animal Hospital of
Lewisville

REFERRING VET

Dr. Journell

INVOICE

15116

DATE

04/14/26