



PATIENT

Maxxwell Patire

SPECIES

Canine

BREED

Spaniel

SEX

Neutered Male

AGE

4 Years

WEIGHT

44 Pounds

INTERPRETED BY

Sara Brethel DVM,
DACVIM (Cardiology)

IMAGING PERFORMED BY

Arielle Roldan, CVT

HOSPITAL NAME

Milford AH

REFERRING VET

Sean Grasso, DVM

INVOICE

36594

DATE

4/13/26

PRESENTING CLINICAL SIGNS

History: Owner notes that Maxx is always panting / breathing heavily even when just laying around and always seems to have increased heart rate " heart is always beating out of his chest "

Otherwise no health concerns, no murmur noted, no history of cardiac symptoms. Owner wanted bloodwork and found abnormal levels.

Abnormal PE/Chem/CBC/UA Results: c.NT-proBNP 1018.1 (500 - 10000 pmol/L) Gray Zone cTnl 0.25 (0.01 - 20 ng/mL) Abnormal.

ULTRASONOGRAPHIC EXAMINATION OF THE HEART

CANINE CARDIAC PARAMETERS	MR VMAX (m/s)	TR VMAX (m/s)	LA/AO (M-Mode)	LA/AO (Heart Base; Swe)	FS (%)	EF (%)	EPSS (cm)
NORMAL PARAMETER	4.5-5.5	<2.7	1.3	Up to 1.6	28-40	40-100	<0.6
PATIENT	NM	--	NM	NM	34.35	--	NM
CANINE CARDIAC PARAMETERS	HR (BPM)	AV VMAX (m/s)	PV MAX (m/s)	BODY WEIGHT (kg)	LAD LA MAX 4 Chamber	LVIDd Avg; 2D and m-mode short axis (cm)	LVIDs Avg; 2D and m-mode short axis (cm)
NORMAL PARAMETER	50-100	0.7-1.7	0.7-1.6				
PATIENT	NM	NM	~1.0	20	--	3.9	2.56

Cardiac Presentation

The mitral valve leaflets are mildly thickened with mild mitral regurgitation posteriorly directed. There is no prolapse of the mitral valve leaflet. The left atrial size is normal. Left ventricular internal dimensions during diastole are within normal limits and systolic function is preserved in the face of mitral regurgitation. There is normal right atrial size with mild tricuspid regurgitation. There is no prolapse of the tricuspid valve leaflets and no evidence of pulmonary hypertension based upon tricuspid regurgitant velocities. The right ventricle subjectively appears normal in structure and function. The aortic and pulmonic valves have normal morphology and the corresponding outflow velocities are within normal limits. There is no evidence of pulmonic or aortic insufficiency. The aorta appears normal. The pulmonary artery and associated branches appear normal. There is no evidence of pleural effusion, pericardial effusion, or intracardiac masses.

ULTRASONOGRAPHIC FINDINGS



PATIENT

Maxxwell Patire

- Degenerative valve disease, ACVIM stage B-1
- Trivial mitral and tricuspid regurgitation

SPECIES

Canine

BREED

Spaniel

SEX

Neutered Male

AGE

4 Years

WEIGHT

44 Pounds

INTERPRETED BY

Sara Brethel DVM,
DACVIM (Cardiology)

IMAGING PERFORMED BY

Arielle Roldan, CVT

HOSPITAL NAME

Milford AH

REFERRING VET

Sean Grasso, DVM

INVOICE

36594

DATE

4/13/26

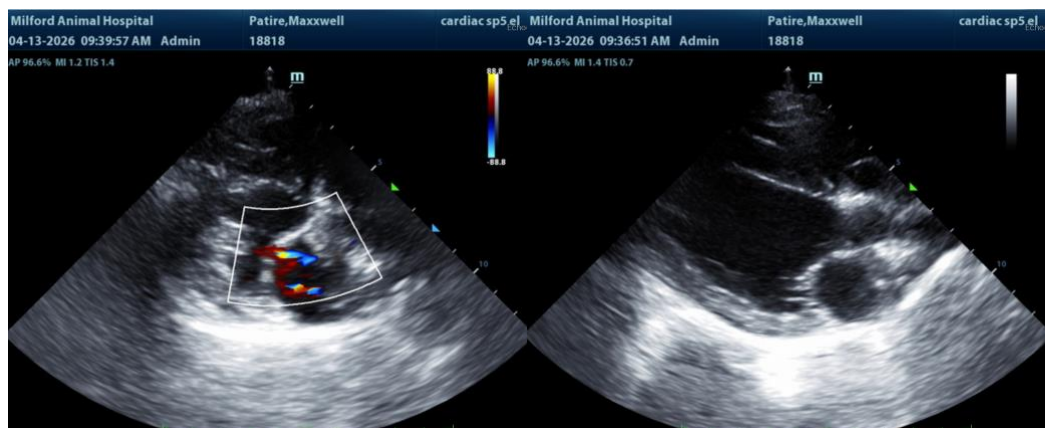
INTERPRETATION OF THE FINDINGS & FURTHER RECOMMENDATIONS

The patient has degenerative valve disease ACVIM stage B1 and no cardiac medications are indicated at this time. Since this can be a progressive condition, serial monitoring is recommended. A recheck echocardiogram is recommended in 10-12 months. A sooner recheck is recommended if the patient develops cardiovascular clinical signs or the heart murmur is worsening in intensity. Elective anesthetic procedures should be well tolerated.

Recommend obtaining a blood pressure on the patient to ensure it is <160mmHg. If the blood pressure is elevated recommend following ACVIM guidelines for systemic hypertension and treating if indicated.

Standard perioperative fluid rates should be well-tolerated. Medications like dexmedetomidine and other alpha 2 agonists are best avoided. Ketamine is also best avoided. Anticholinergics can be used in the case of a clinically significant bradyarrhythmia (i.e., bradycardia with concurrent hypotension). If the patient is on an ACEi, recommend not giving this therapy the day of anesthesia.

The cause of the patient's clinical signs is not identified based upon the images provided. The mild degenerative changes can cause an elevated proBNP and a mildly increased troponin. Consider endocrine testing, obtaining an electrocardiogram, chest radiographs, and possible abdominal imaging for further investigation into the patient's clinical status.



The information and recommendations provided are based on the images presented by the referring veterinarian/sonographer. No evaluation can be communicated regarding pathology that was not visible in the image/video clips provided.

Thank you for this referral. If the clinical or image interpretation does not parallel your findings or if I can be of any further assistance please contact me.

Sara Brethel DVM, DACVIM (Cardiology)



PATIENT

info@SonoPath.com

Maxxwell Patire

SPECIES

Canine

BREED

Spaniel

SEX

Neutered Male

AGE

4 Years

WEIGHT

44 Pounds

INTERPRETED BY

Sara Brethel DVM,
DACVIM (Cardiology)

IMAGING PERFORMED BY

Arielle Roldan, CVT

HOSPITAL NAME

Milford AH

REFERRING VET

Sean Grasso, DVM

INVOICE

36594

DATE

4/13/26