



**PATIENT**

Bodhi Yeager

**SPECIES**

Canine

**BREED**

Hound Mix

**SEX**

Spayed Female

**AGE**

9 Years 11 Months

**WEIGHT**

58 Pounds

**INTERPRETED BY**

Sara Brethel DVM,  
DACVIM (Cardiology)

**IMAGING PERFORMED BY**

Kerri Becker

**HOSPITAL NAME**

Ringwood AH

**REFERRING VET**

Dr. Wilkes

**INVOICE**

36597

**DATE**

4/13/26

**PRESENTING CLINICAL SIGNS**

History: New 4/6 systolic murmur otherwise well and normal.  
Abnormal PE/Chem/CBC/UA Results: glob-4.4 neut-2.7

**ULTRASONOGRAPHIC EXAMINATION OF THE HEART**

CANINE CARDIAC PARAMETERS	MR VMAX (m/s)	TR VMAX (m/s)	LA/AO (M-Mode)	LA/AO (Heart Base; Swe)	FS (%)	EF (%)	EPSS (cm)
NORMAL PARAMETER	4.5-5.5	<2.7	1.3	Up to 1.6	28-40	40-100	<0.6
PATIENT	~6.0	--	NM	1.1	35.01	--	NM
CANINE CARDIAC PARAMETERS	HR (BPM)	AV VMAX (m/s)	PV MAX (m/s)	BODY WEIGHT (kg)	LAD LA MAX 4 Chamber	LVIDd Avg; 2D and m-mode short axis (cm)	LVIDs Avg; 2D and m-mode short axis (cm)
NORMAL PARAMETER	50-100	0.7-1.7	0.7-1.6				
PATIENT	--	~1.3	~1.0	26.36	4.8	3.57	2.32

*\*\*No other measurements were obtained.*

**Cardiac Presentation**

The mitral valve leaflets are mildly thickened with mild mitral regurgitation posteriorly directed. There is no prolapse of the mitral valve leaflets. The left atrial size is at the upper limits of normal to mildly increased on long axis assessment. Left ventricular internal dimensions during diastole are within normal limits and systolic function is preserved in the face of mitral regurgitation. There is normal right atrial size without tricuspid regurgitation. There is no prolapse of the tricuspid valve leaflets and no evidence of pulmonary hypertension based upon tricuspid regurgitant velocities. The right ventricle subjectively appears normal in structure and function. The aortic and pulmonic valves have normal morphology and the corresponding outflow velocities are within normal limits. There is no evidence of pulmonic or aortic insufficiency. The aorta appears normal. The pulmonary artery and associated branches appear normal. There is no evidence of pleural effusion, pericardial effusion, or intracardiac masses.

**ULTRASONOGRAPHIC FINDINGS**

- Degenerative valve disease, ACVIM stage B-1
- Left atrium upper limits of normal to mildly increased on long axis assessment

**INTERPRETATION OF THE FINDINGS & FURTHER RECOMMENDATIONS**

The patient has degenerative valve disease ACVIM stage B1 and no cardiac medications are indicated at this time. Since this can be a progressive condition, serial monitoring is recommended. A recheck echocardiogram is recommended in 4-6 months due to the left atrial size. A sooner recheck is



**PATIENT**

Bodhi Yeager

recommended if the patient develops cardiovascular clinical signs or the heart murmur is worsening in intensity. Elective anesthetic procedures should be well tolerated.

**SPECIES**

Canine

Recommend obtaining a blood pressure on the patient to ensure it is <160mmHg. If the blood pressure is elevated recommend following ACVIM guidelines for systemic hypertension and treating if indicated.

**BREED**

Hound Mix

Due to the left atrium being at the upper limits of normal to mildly increased, judicious perioperative fluids are recommended. Medications like dexmedetomidine and other alpha 2 agonists are best avoided. Ketamine is also best avoided. If needed, anticholinergics can be used in the face of a clinically significant bradyarrhythmia (i.e., bradycardia with concurrent hypotension). If the patient is on an ACEi, recommend not giving this therapy the day of anesthesia.

**SEX**

Spayed Female

**AGE**

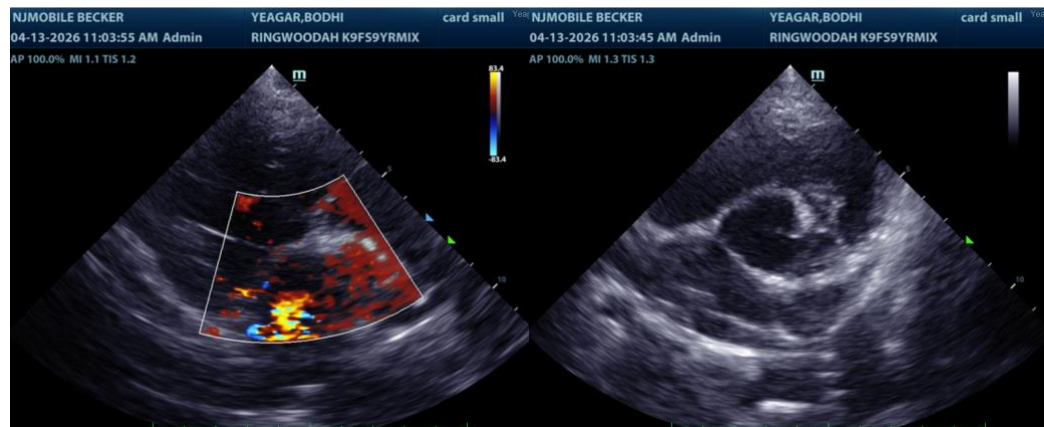
9 Years 11 Months

**WEIGHT**

58 Pounds

**INTERPRETED BY**

Sara Brethel DVM,  
DACVIM (Cardiology)



**IMAGING PERFORMED BY**

Kerri Becker

The information and recommendations provided are based on the images presented by the referring veterinarian/sonographer. No evaluation can be communicated regarding pathology that was not visible in the image/video clips provided.

**HOSPITAL NAME**

Ringwood AH

Thank you for this referral. If the clinical or image interpretation does not parallel your findings or if I can be of any further assistance please contact me.

Sara Brethel DVM, DACVIM (Cardiology)

**REFERRING VET**

Dr. Wilkes

[info@SonoPath.com](mailto:info@SonoPath.com)

**INVOICE**

36597

**DATE**

4/13/26