

PATIENT

Biscuit Easter

SPECIES

Canine

BREED

Mixed Breed

SEX

Neutered Male

AGE

15 Years

WEIGHT

22.7 pounds

INTERPRETED BY

Sara Brethel DVM,
DACVIM (Cardiology)

IMAGING PERFORMED BY

Kathleen Byrnes

HOSPITAL NAME

Gentle Touch
Veterinary Hospital

REFERRING VET

Dr. Jackson

INVOICE

14067

DATE

03/05/26

PRESENTING CLINICAL SIGNS

- P has hypoproteinemia, recently had abd US at specialist and diagnosed with PLE. Heart murmur recently heard.
- P has thickened erythematous area on lip that is concerning for infection, neoplasia, autoimmune dz and dental dz.
- Owner considering anesthesia for dental cleaning and biopsy of lip but has concerns due to age and PLE
- rDVM considering using steroid for palliative care but concerned about heart.
- ABD US report- IBD, Lymphangiectasia and PLE suspected, benign renal cysts, non-obstructive left renolithiasis, pit dependent HAC and 2nd vacuolar hepatopathy suspected

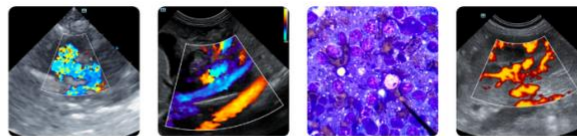
Abnormal PE/Chem/CBC/UA Results: HCT 37.6, Lymph 4.4, TP 4.1, Alb 2.1, Glob 2, Lipase 506, Crea Kinase 247

ULTRASONOGRAPHIC EXAMINATION OF THE HEART

CANINE CARDIAC PARAMETERS	MR VMAX (m/s)	TR VMAX (m/s)	LA/AO (M-Mode)	LA/AO (Heart Base; Swe)	FS (%)	EF (%)	EPSS (cm)
NORMAL PARAMETER	4.5-5.5	<2.7	1.3	Up to 1.6	28-40	40-100	<0.6
PATIENT	5.72	3.12	NM	1.5	27.21	54.15	NM
CANINE CARDIAC PARAMETERS	HR (BPM)	AV VMAX (m/s)	PV MAX (m/s)	BODY WEIGHT (kg)	LAD LA MAX 4 Chamber	LVIDd Avg; 2D and m-mode short axis (cm)	LVIDs Avg; 2D and m-mode short axis (cm)
NORMAL PARAMETER	50-100	0.7-1.7	0.7-1.6				
PATIENT	114	1.33	0.85	10.32	3.8	3.36	2.45

Cardiac Presentation

The mitral valve leaflets are mildly thickened with moderate mitral regurgitation posteriorly directed. There is no prolapse of the mitral valve leaflet. The left atrial size is mildly to moderately increased. Left ventricular internal dimensions during diastole are within normal limits but meet EPIC criteria and systolic function is low normal in the face of mitral regurgitation. There is normal right atrial size with mild tricuspid regurgitation. There is no prolapse of the tricuspid valve leaflets and mild evidence of pulmonary hypertension based upon tricuspid regurgitant velocities. The right ventricle subjectively appears normal in structure and function. The aortic and pulmonic valves have normal morphology and the corresponding outflow velocities are within normal limits. There is no evidence of pulmonic or aortic insufficiency. The aorta appears normal. The pulmonary artery and associated



PATIENT

Biscuit Easter

SPECIES

Canine

BREED

Mixed Breed

SEX

Neutered Male

AGE

15 Years

WEIGHT

22.7 pounds

INTERPRETED BY

Sara Brethel DVM,
DACVIM (Cardiology)

IMAGING PERFORMED BY

Kathleen Byrnes

HOSPITAL NAME

Gentle Touch
Veterinary Hospital

REFERRING VET

Dr. Jackson

INVOICE

14067

DATE

03/05/26

branches appear normal. There is no evidence of pleural effusion, pericardial effusion, or intracardiac masses.

ULTRASONOGRAPHIC FINDINGS

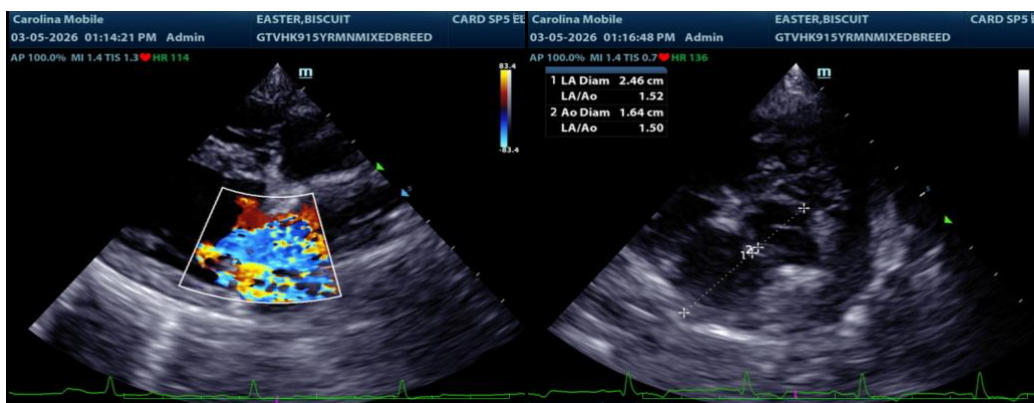
- Degenerative valve disease ACVIM stage B2.
- Mild to moderate left atrial enlargement.
- Mild pulmonary hypertension.
- Low normal ventricular systolic function.

INTERPRETATION OF THE FINDINGS & FURTHER RECOMMENDATIONS

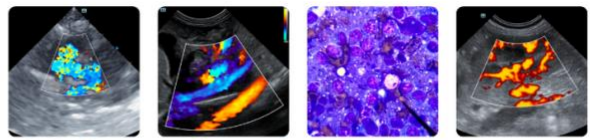
The patient has degenerative valve disease ACVIM stage B2 and Pimobendan therapy at 0.27-0.32mg/kg PO q12 is recommended. This will be a lifelong therapy. A recheck echocardiogram is recommended in 4-6 months to monitor the condition since starting Pimobendan. A sooner recheck is recommended if the patient develops cardiovascular clinical signs or the heart murmur is worsening in intensity. The client should start monitoring respiratory rate and effort at home if not already doing so. The resting respiratory rate should be < 35-40 breathes/minute when the patient is resting or sleeping. If the breathing rates are increasing, then chest radiographs are recommended.

Recommend obtaining a blood pressure on the patient to ensure it is <160mmHg. If the blood pressure is elevated recommend following ACVIM guidelines for systemic hypertension and treating if indicated.

The patient is at a mildly increased risk for elective anesthetic procedures. To minimize that risk, I recommend they be on Pimobenden for at least one to three weeks prior to elective procedures. Judicious perioperative fluids are recommended due to the increased left atrial size. Medications like dexmedetomidine and other alpha 2 agonists are best avoided. Ketamine is also best avoided. If needed, anticholinergics can be used in the face of a clinically significant bradyarrhythmia (i.e., bradycardia with concurrent hypotension). If the patient is on an ACEi, recommend not giving this therapy the day of anesthesia.



The information and recommendations provided are based on the images presented by the referring veterinarian/sonographer. No evaluation can be communicated regarding pathology that was not visible in the image/video clips provided.



PATIENT

Biscuit Easter

SPECIES

Canine

BREED

Mixed Breed

SEX

Neutered Male

AGE

15 Years

WEIGHT

22.7 pounds

INTERPRETED BY

Sara Brethel DVM,
DACVIM (Cardiology)

**IMAGING
PERFORMED BY**

Kathleen Byrnes

HOSPITAL NAME

Gentle Touch
Veterinary Hospital

REFERRING VET

Dr. Jackson

INVOICE

14067

DATE

03/05/26

Thank you for this referral. If the clinical or image interpretation does not parallel your findings or if I can be of any further assistance please contact me.

Sara Brethel DVM, DACVIM (Cardiology)

info@SonoPath.com