



PATIENT

Scout Mikkola

SPECIES

Canine

BREED

Chihuahua Mix

SEX

Neutered Male

AGE

9 Years

WEIGHT

11.4

INTERPRETED BY

Sara Brethel, DVM,
DACVIM (Cardiology)

IMAGING PERFORMED BY

Sara Hansen

HOSPITAL NAME

Creekside VC

REFERRING VET

Dr. Strahon

INVOICE

36109

DATE

3/4/26

PRESENTING CLINICAL SIGNS

- Clinical Exam Findings: Degenerative Valve Disease ACVIM stage B2
- HR/RR/BP: 160/30
- Is there a Heart Murmur? If so, please grade: gr. 3/6 L systolic heart murmur on auscultation
- Current Medications: Pimobendan 1.25mg PO BID, Trazodone 25mg + Gabapentin 50mg PO evening prior and am of echocardiogram.
- Radiographic Findings: O will decide on day of echocardiogram if pursuing radiographs
- Notes to Specialist (if any): Recheck echocardiogram for monitoring after starting pimobendan

ULTRASONOGRAPHIC EXAMINATION OF THE HEART

CANINE CARDIAC PARAMETERS	MR VMAX (m/s)	TR VMAX (m/s)	LA/AO (M-Mode)	LA/AO (Heart Base; Swe)	FS (%)	EF (%)	EPSS (cm)
NORMAL PARAMETER	4.5-5.5	<2.7	1.3	Up to 1.6	28-40	40-100	<0.6
PATIENT	7.37	--	1.49	1.42	41.15	--	0.16
CANINE CARDIAC PARAMETERS	HR (BPM)	AV VMAX (m/s)	PV MAX (m/s)	BODY WEIGHT (kg)	LAD LA MAX 4 Chamber	LVIDd Avg; 2D and m-mode short axis (cm)	LVIDs Avg; 2D and m-mode short axis (cm)
NORMAL PARAMETER	50-100	0.7-1.7	0.7-1.6				
PATIENT	--	1.21	1.16	5.18	3.1	2.77	1.63

Cardiac Presentation

The mitral valve leaflets are mildly thickened with mild mitral regurgitation posteriorly directed. There is no prolapse of the mitral valve leaflets. The left atrial size is normal. Left ventricular internal dimensions during diastole are within normal limits and systolic function is preserved in the face of mitral regurgitation. There is normal right atrial size without tricuspid regurgitation. There is no prolapse of the tricuspid valve leaflets and no evidence of pulmonary hypertension based upon tricuspid regurgitant velocities. The right ventricle subjectively appears normal in structure and function. The aortic and pulmonic valves have normal morphology and the corresponding outflow



PATIENT

Scout Mikkola

SPECIES

Canine

BREED

Chihuahua Mix

SEX

Neutered Male

AGE

9 Years

WEIGHT

11.4

INTERPRETED BY

Sara Brethel, DVM,
DACVIM (Cardiology)

IMAGING PERFORMED BY

Sara Hansen

HOSPITAL NAME

Creekside VC

REFERRING VET

Dr. Strahon

INVOICE

36109

DATE

3/4/26

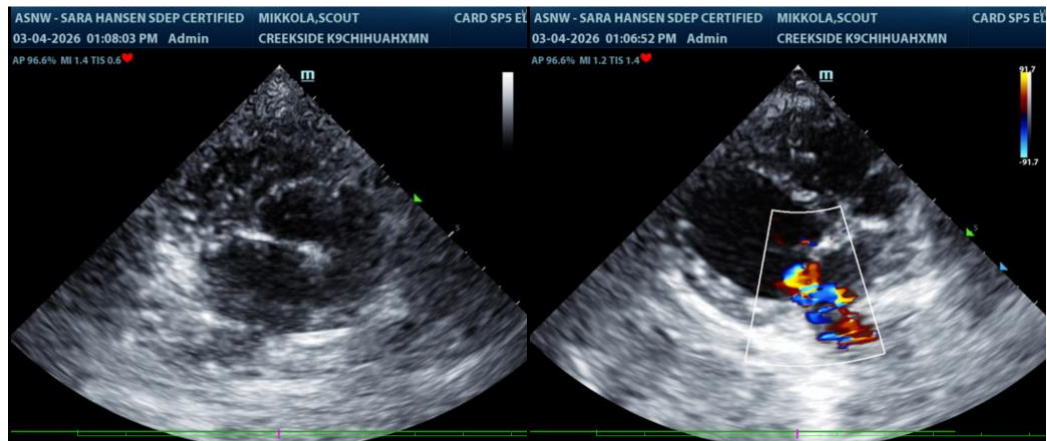
velocities are within normal limits. There is no evidence of pulmonic or aortic insufficiency. The aorta appears normal. The pulmonary artery and associated branches appear normal. There is no evidence of pleural effusion, pericardial effusion, or intracardiac masses.

ULTRASONOGRAPHIC FINDINGS

- Degenerative valve disease, ACVIM stage B-2 (improved dimensions when compared to previous echo)

INTERPRETATION OF THE FINDINGS & FURTHER RECOMMENDATIONS

The patient continues to have degenerative valve disease, ACVIM stage B-2. No changes to medications are recommended, and there has been improvement in left atrial size since the previous evaluation. The pimobendan will continue to be a lifelong therapy. Recheck echo in 10-12 months, sooner if the patient is decompensating or the murmur is worsening in intensity. If elective anesthetic procedures are needed, the patient should be an adequate candidate. Judicious perioperative fluids are recommended due to the increased left atrial size. Medications like dexmedetomidine and other alpha 2 agonists are best avoided. Ketamine is also best avoided. If needed, anticholinergics can be used in the face of a clinically significant bradyarrhythmia (i.e., bradycardia with concurrent hypotension). If the patient is on an ACEi, recommend not giving this therapy the day of anesthesia.



The information and recommendations provided are based on the images presented by the referring veterinarian/sonographer. No evaluation can be communicated regarding pathology that was not visible in the image/video clips provided.

Thank you for this referral. If the clinical or image interpretation does not parallel your findings or if I can be of any further assistance please contact me.

Sara Brethel DVM, DACVIM (Cardiology)

info@SonoPath.com



PATIENT

Scout Mikkola

SPECIES

Canine

BREED

Chihuahua Mix

SEX

Neutered Male

AGE

9 Years

WEIGHT

11.4

INTERPRETED BY

Sara Brethel, DVM,
DACVIM (Cardiology)

**IMAGING
PERFORMED BY**

Sara Hansen

HOSPITAL NAME

Creekside VC

REFERRING VET

Dr. Strahon

INVOICE

36109

DATE

3/4/26