



PATIENT

Cali Rochambeau

SPECIES

Feline

BREED

DSH

SEX

Spayed Female

AGE

13 Years

WEIGHT

8.3 Pounds

INTERPRETED BY

Sara Brethel DVM,
 DACVIM (Cardiology)

IMAGING PERFORMED BY

Sara Hansen

HOSPITAL NAME

Eastgate VC

REFERRING VET

Dr. Iantz

INVOICE

36092

DATE

3/3/26

PRESENTING CLINICAL SIGNS

Clinical Exam Findings:

- Dental disease with FORLs and fracture teeth, tartar, gingivitis.
- Exophthalmos OS
- 1/6 sternal systolic murmur
- Allergic miliary dermatitis/flea allergies
- ABNORMAL Labwork Values: Mild eosinophilia and lymphopenia and thrombocytosis
- HR/RR/BP: On 2/10/2026 - 180 HR; 30 RR
- Is there a Heart Murmur? If so, please grade:1/6
- Current Medications: None that we are aware of in last 24 hours prior to echocardiogram.
- Notes to Specialist (if any): Patient needs a dental procedure with extractions and an enucleation. Want to evaluate overall health and heart prior to anesthesia. Trying to also decide on if doing dental/extractions and enucleation at same time or two different procedures in light of cardiac disease - which would be better for heart? Peri-operative cardiac safe/supportive drugs?

ULTRASONOGRAPHIC EXAMINATION OF THE HEART

FELINE CARDIAC PARAMETERS	BODY WEIGHT (kg)	HR (BPM)	IVSd (cm)	LVIDd (cm)	LVWd (cm)	FS (%)	EF (%)
NORMAL PARAMETER	-----	150-240	0.3-0.6	1.0-2.1	0.25-0.6	35-67	80-100
PATIENT	3.77	NM	0.4	1.1	0.5	40	--
FELINE CARDIAC PARAMETERS	LA/AO (M-mode)	LA/AO HEART BASE (Sisson)	LAD LA MAX 4 Chamber		LVOT VEL. (m/s)	RVOT VEL. (m/s)	IVRT (m/)
NORMAL PARAMETER	<1.5	1.6	0.7-1.7		<1.6	<1.3	40-60
PATIENT	1.06	1.16	--		0.97	1.14	NM
Adapted from June Boon, Veterinary Echocardiography,1998 Sisson D et al. JVIM 1991; 5: 232, Jacobs et al. Am J Vet Res 1985; 46:1705							

LVIDs: 0.66



PATIENT

Cali Rochambeau

SPECIES

Feline

BREED

DSH

SEX

Spayed Female

AGE

13 Years

WEIGHT

8.3 Pounds

INTERPRETED BY

Sara Brethel DVM,
 DACVIM (Cardiology)

IMAGING PERFORMED BY

Sara Hansen

HOSPITAL NAME

Eastgate VC

REFERRING VET

Dr. Iantz

INVOICE

36092

DATE

3/3/26

Cardiac Presentation

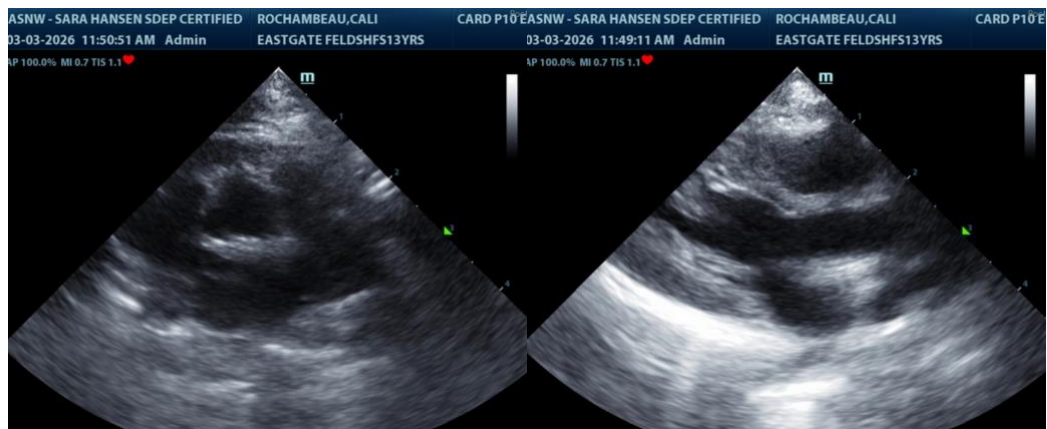
The mitral valve leaflets are normal and there is no mitral regurgitation. The left atrial size is normal. There is no evidence of systolic anterior motion of the mitral valve and no evidence of a left ventricular outflow tract obstruction. Left ventricular systolic and diastolic function is within normal limits. There is no evidence of left ventricular concentric hypertrophy. There is normal right atrial size without evidence of tricuspid regurgitation. There is no prolapse of the tricuspid valve leaflets and no evidence of pulmonary hypertension on the images provided. The right ventricle appears normal in structure and function subjectively. The aortic and pulmonic valves have normal morphology and the corresponding outflow velocities are within normal limits. There is no evidence of pulmonic or aortic insufficiency. The aorta appears normal. The pulmonary artery and associated branches appear normal. There is no evidence of pleural effusion, pericardial effusion, or intracardiac masses.

ULTRASONOGRAPHIC FINDINGS

- Structurally normal heart

INTERPRETATION OF THE FINDINGS & FURTHER RECOMMENDATIONS

The heart is structurally normal and a cause for the murmur is not identified. Therefore, the murmur is likely innocent. The reported blood pressures are also within normal limits. If the murmur persists, consider a recheck echo in another 10-12 months. No contraindications for the patient's required anesthesia at this time based upon the images provided.



The information and recommendations provided are based on the images presented by the referring veterinarian/sonographer. No evaluation can be communicated regarding pathology that was not visible in the image/video clips provided.

Thank you for this referral. If the clinical or image interpretation does not parallel your findings or if I can be of any further assistance please contact me.

Sara Brethel DVM, DACVIM (Cardiology)



PATIENT

info@SonoPath.com

Cali Rochambeau

SPECIES

Feline

BREED

DSH

SEX

Spayed Female

AGE

13 Years

WEIGHT

8.3 Pounds

INTERPRETED BY

Sara Brethel DVM,
DACVIM (Cardiology)

**IMAGING
PERFORMED BY**

Sara Hansen

HOSPITAL NAME

Eastgate VC

REFERRING VET

Dr. Iantz

INVOICE

36092

DATE

3/3/26